



## CASE REPORT

### Natal and Neonatal Teeth in Bahrain: A Review of 19 Cases

Fajer S. Al-Buainain<sup>1\*</sup>, Aania Adil<sup>2</sup>, Omar Mustafa<sup>3</sup>

<sup>1</sup>Resident, Dental and maxillofacial center, Bahrain Defence Force Royal Medical Services, Riffa, Bahrain

<sup>2</sup>Senior Resident, Dental, and maxillofacial center, Bahrain Defence Force Royal Medical Services, Riffa, Bahrain

<sup>3</sup>Consultant Paediatric Dentist, Dental and maxillofacial center, Bahrain Defence Force Royal Medical Services, Riffa, Bahrain

**\*Corresponding author:**

Fajer Salem Al-Buainain, Resident, Dental and maxillofacial center, Bahrain Defence Force Royal Medical Services, Riffa, Bahrain. Tel.: (+973) 34455459. Address: Kingdom of Bahrain, West Riffa, Block 91-, Road: 1066, House: 3098; E-mail: [Fajer.s.albuainain@gmail.com](mailto:Fajer.s.albuainain@gmail.com)

**Received date:** September 30, 2020; **Accepted date:** December 9, 2020; **Published date:** March 31, 2021

#### Abstract

**Background:** This paper aimed to present 29 natal/neonatal teeth in 19 patients and subsequently described clinical characteristics, associated disorders, and treatments.

**Methods:** This is a retrospective study of Bahraini neonates with natal or neonatal teeth who reported to the pediatric dental clinic, Dental and Maxillofacial Center, Bahrain Defense Forces-Royal Medical Services, Kingdom of Bahrain, conducted over a decade. Information about age, gender, mothers' chief complaint, the clinical appearance of natal/neonatal teeth, location, associated complications, and treatments were collected.

**Results:** A total of 29 teeth (20 natal, 9 neonatal) were diagnosed in 19 infants. There was a female predilection (14 females, 4 males). Twenty-eight of the natal/neonatal teeth were located in the lower central incisor area and one tooth in the lower lateral incisor area. Almost half of the infants (n=9, 47.4%) were diagnosed with a pair of teeth, and only one infant was distinguished with a total of three natal/neonatal teeth. Three cases were associated with Riga-Fede disease, five with gingival hyperplasia, and one with enamel hypoplasia. Intraoral radiographs were taken selectively for some of the patients. Extraction was the most common treatment choice.

**Conclusion:** The occurrence of a natal/neonatal tooth is considered a rare phenomenon. It showed diverse clinical characteristics which could lead to various complications. In this study, natal teeth were more common than neonatal teeth, with a preference for females. The decision to retain or extract a natal/ neonatal tooth should be evaluated in each case, keeping in mind multiple factors like scientific evidence-based knowledge, clinical judgment, and parental opinion.

**Keywords:** Dental Enamel Hypoplasia; Gingival Hyperplasia; Oral Ulcer; Natal teeth; Vitamin K.

#### Introduction

Development of primary teeth commences at the end of the fifth week of gestation. It is not until six

months of post-natal life that lower primary central incisors erupt in the oral cavity.<sup>1</sup> However, infants can sometimes present with teeth much earlier in

life, and those present at birth are called natal teeth, and those that erupt during the first 30 days are referred to as neonatal teeth.<sup>2</sup>

In the 1950s, the terms natal and neonatal teeth were first suggested by Massler and Savara. These terms were limited to the time of the eruption and not to the anatomy of the teeth. Morphologically, the natal and neonatal teeth may be of standard size and shape.<sup>2</sup> However, most of the time, they are small, conical, and poorly developed, presenting a yellowish-brown discoloration and enamel hypoplasia.<sup>3</sup> Later in the 1960s, natal/neonatal teeth were classified into; mature & immature teeth; based on the level of development compared to the primary dentition.<sup>4</sup> Furthermore, Hebling in 1997, divided natal teeth according to the appearance into four clinical categories.<sup>5</sup> Table. 1

**Table 1: Hebling classification of natal/neonatal teeth (1997)**

<b>Class 1</b>	Shell-shaped crown poorly fixed to the alveolus by gingival tissue and absence of a root
<b>Class 2</b>	Solid crown poorly fixed to the alveolus by gingival tissue and little or no root
<b>Class 3</b>	Eruption of the incisal margin of the crown through gingival tissue
<b>Class 4</b>	Edema of gingival tissue with an unerupted but palpable tooth

The presence of natal/ neonatal teeth is a disruption in the biological chronology with an unknown etiology.<sup>6</sup> The superficial position of the germ and osteoblastic activity inside the germ area are some of the local factors that have been associated with the unexpected premature eruption of teeth in the form of natal/neonatal teeth.<sup>7</sup> Infection, malnutrition, febrile states, or endocrine disturbances to the mother during pregnancy or the infant post-birth are predisposing factors suggested in the literature.<sup>8,9</sup> Influence of genetics through an autosomal dominant inheritance trait is documented.<sup>10</sup>

The rare occasion of being born with a tooth has always been associated with myths and folklore. Some communities have believed that children born with teeth were lucky, such as Western European and Malaysian. In contrast, these children were

considered monsters in places like India, China, and Africa.<sup>11</sup> Today, it is essential to support parents with proper counseling and careful management to deal with possible negative cultural attitudes.<sup>12</sup>

Though limited papers were published in the Middle east regarding natal and neonatal teeth, none were based on Bahraini population. This paper aimed to present 29 natal/neonatal teeth in 19 Bahraini patients and described the clinical characteristics, associated disorders, and treatments.

## Materials and methods

This is a retrospective study of Bahraini neonates with natal or neonatal teeth reported to the pediatric dental clinic, Dental and Maxillofacial Center, Bahrain Defense Forces-Royal Medical Services (BDF-RMS), Kingdom of Bahrain, in a 10-year period between January 2010 and April 2020. Cases with incomplete documentation were excluded. Information about age, gender, mothers' chief complaint, natal/neonatal teeth' clinical characteristics, associated complications, and treatments were collected from dental records. These variables were descriptively analyzed, and possible relationships between these variables were assessed.

## Ethical approval

The study was carried out in full accordance with the World Medical Association Declaration of Helsinki, and the ethical approval was acquired from the Research and Ethics committee of Bahrain Defence Force-Royal Medical Services, Military Hospital, Kingdom of Bahrain.

## Results

A total of 29 teeth (20 natal, 9 neonatal) were diagnosed in 19 infants. The infants' age on the day of the visit varied from two days to one-month-old (Table 2). There were more females (n=14, 73.7%) with natal/neonatal than males (n=5, 26.3%). Of the nineteen patients, almost half of them (n=9, 47.4%) were diagnosed with a pair of teeth. However, presentation of more than two teeth was uncommon. Only one infant had a total of three natal/ neonatal teeth (case 19); where he was born with two natal teeth, and by the end of the first month of his life, another neonatal tooth erupted.

**Table 2: Clinical characteristics of natal/neonatal teeth**

Sl. No.	Gender	Age	Natal/ Neonatal	Teeth Position	Clinical features	Associated disorders & complications
1.	Male	4 days	Natal	71,81	- Severe mobility - Whitish color	None
2.	Female	8 days	Natal	71,81	- Mild mobility - White color	None
3.	Female	18 days	Neonatal	71,81	- Severe mobility - Whitish color	None
4.	Female	28 days	Neonatal	71	- Mild mobility - Whitish color and sharp incisal edge - Ulceration on the ventral surface of the tongue	Riga-Fede disease
5.	Female	2 days	Natal	71	- Very Mobile - Ulceration on the ventral surface of the tongue	Riga-Fede disease
6.	Female	26 days	Neonatal	71,81	- Very mobile - Whitish- opaque in color	None
7.	Male	7 days	Natal	71,81	- Mild mobility - Partial erupted natal teeth with Inflamed bulging gums around the teeth	Gingival hyperplasia
8.	Female	5 days	Natal	71,81	- Mild mobility - White color	None
9.	Male	7 days	Neonatal	81	- No mobility - White incisal edge seen through the enlarged surrounding gingiva.	Gingival hyperplasia
10.	Female	10 days	Natal	71	- Very mobile - Whitish color	none
11.	Female	4 days	Natal	71	- Very mobile - Soft & yellowish in color	Enamel hypoplasia
12.	Male	30 days	Neonatal	71,81	- Mild mobility - White color	None
13.	Female	7 days	Natal	81	- Severe mobility - Whitish color	None
14.	Female	8 days	Natal	81	- Severe mobility - sharp incisal edge	None
15.	Male	9 days	Neonatal	81	- Not mobile - Enlarged inflamed surrounding gums	Gingival hyperplasia
16.	Female	22days	Neonatal	71	- Mildly Mobile - White incisal edge seen from the enlarged gingival tissue	Gingival hyperplasia
17.	Female	5 days	Natal	71	- Sever mobility - Whitish color	None
18.	Female	9 days	Natal	71,81	- Mild mobility - Bluish enlarged gum around the partially erupted natal teeth	Gingival hyperplasia
19.	Female	1 month	Natal & Neonatal	71,81 82	- Very mobile - Fibrotic ulceration in the ventral surface of the tongue - Mild mobility, sharp incisal edge, whitish color	Riga-Fede disease

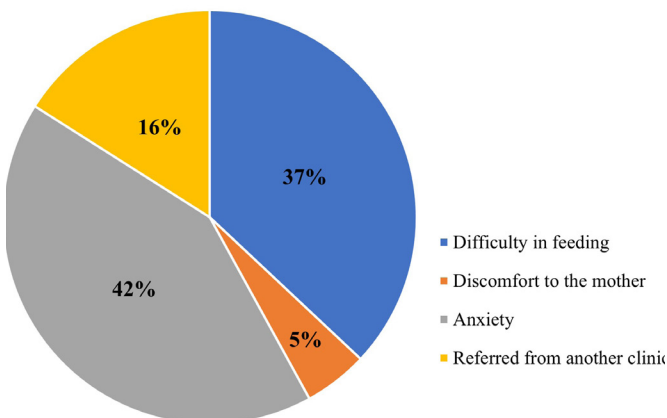
None of the patients had associated systemic diseases, congenital abnormalities, or any syndromes.

Furthermore, two patients (n=2, 10.5%) had a positive family history of natal or neonatal teeth, and one case (n=1, 3.4%) was linked with preterm birth.

Regarding the anatomical location of natal/neonatal teeth, there was a preference for the mandibular central incisor position (n=28, 96.6%). However, in addition to the natal mandibular central incisors, a neonatal tooth had erupted in the lower right lateral incisors area (case 19). No difference was found concerning the side of the mouth where the tooth erupted, although the natal/neonatal teeth were slightly higher on the left side (n=15, 51.7%) than on the right side (n=14, 48.3%).

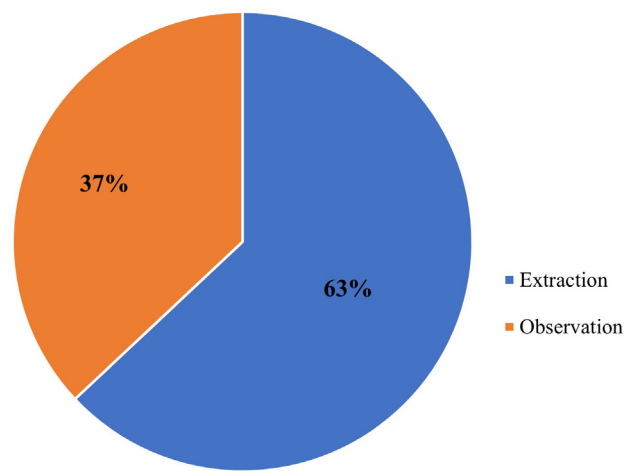
Clinically, three patients presented with Riga-Fede disease (cases 4, 5 and 19), five patients showed gingival hyperplasia (cases 7, 9, 15, 16, and 18), and one patient with enamel hypoplasia (case 11). Moreover, most of the natal and neonatal teeth exhibited some degree of mobility.

In the presented cases, natal/neonatal teeth were causing multiple complaints (Figure 1). The most common reason for visiting the dental clinic was parental anxiety, where parents were anxious either because of the tooth’s appearance or due to the fear of possible aspiration as a sequence of the tooth’s high mobility. The second most common complaint was difficulty in feeding or refusing to suckle milk, followed by referrals from other health care providers, and, finally, due to discomfort to the mother while breastfeeding.

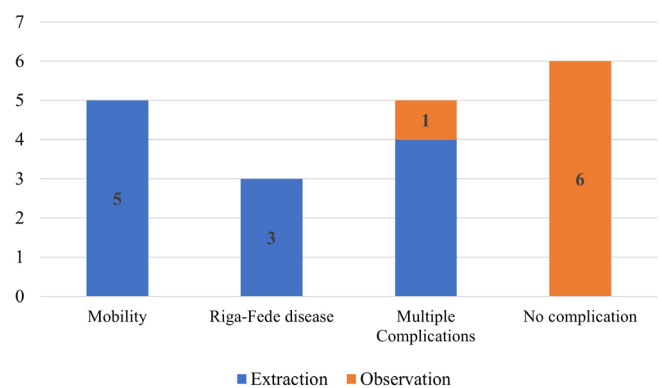


**Figure 1: The primary reason for visiting the dental clinic**

Intraoral radiographs were taken selectively to some of the patients. Whenever the tooth was to be extracted, radiographs were avoided, and the parents were informed about the high possibility of losing the corresponding deciduous teeth. Tooth extraction was the most common treatment of choice (63.2%) (Figure 2.a), and it was mostly associated with mobile natal/neonatal teeth, infants with feeding problems, or Riga-Fede disease and (Figure 2.b). Extraction was performed under topical anesthesia, and a few local anesthesia drops after confirming that the infant had received Vitamin K injection at birth. The other seven natal/neonatal teeth (36.8%) were kept under observation, with a regular follow up appointment.



(A) Distribution of treatments



(B) Relative proportions of treatments according to clinical features and complications

**Figure 2: Treatment options for natal/neonatal teeth.**

**Discussion**

The presence of natal/neonatal teeth is considered a rare condition. Most studies have found the prevalence to range between 1:1000 and 1:30,000 live births.<sup>2,9</sup> Variation in prevalence depends on

the different populations and the type of study.<sup>9</sup> Recent studies have reported a much more common frequency of natal teeth in specific populations, especially Asians. For instance, northern Taiwanese recorded one of the highest frequencies (1:140) in 2004.<sup>13</sup>

Regarding gender, many reports showed prevalence in females than males, which is similar to this study.<sup>14,15</sup> Females represented around three-quarters of the infants with natal/neonatal teeth (n=14, 73.7%). On the other hand, a few studies reported no gender difference.<sup>16,17</sup>

Few syndromes are associated with natal teeth and neonatal teeth, such as Ellis-Van Creveld, Hallermann-Streiff, Pierre-Robin, Cleft Lip, and Palate and Ectodermal Dysplasia.<sup>6</sup> However, none of the cases presented here showed syndromic features or systemic manifestations. Previous studies have also proposed a positive relationship between natal/neonatal teeth and family history. While some of these studies reported a strong connection with incidence rates ranging from 8% to 46%.<sup>2, 10, 11, 15</sup> In this study, positive family history was evident in very few infants (n=2, 10.5%). One of the infants with natal teeth was born prematurely, and, despite the connection between prematurity and delay in dental eruption in the deciduous dentition, natal and neonatal teeth have been documented as rare oral anomalies in preterm infants.<sup>18</sup>

In this study, the ratio of natal to neonatal teeth was 2.2:1, which is close to other studies (approximately 3:1).<sup>19</sup> However, it is worth mentioning that the more common presentation of the natal teeth might be explained by the fact that it is mainly diagnosed and reported by pediatricians. In comparison, the later eruption of the neonatal teeth might not be reported by the infants' parents as long as they are asymptomatic. Another possible cause for the less documented neonatal teeth is that the parents might manage the condition themselves. This concept is supported by one of the excluded patients, where he was brought to the clinic after his grandfather extracted his loose tooth at home.

The most commonly affected teeth were the mandibular primary central incisors (96.6%), followed by the mandibular lower lateral incisors

(3.4%). A survey by Bodenholff found a similar distribution in which the mandibular incisors were the most common (85%), followed by the maxillary incisors (11%), and the mandibular canines and molars (3%), and the maxillary canines and molars (1%).<sup>11</sup> The strong preference for the mandibular central incisors is not extraordinary since they are usually the first teeth to erupt. In this study, there was no preference for a specific side of the oral cavity that these teeth erupted, which is consistent with previous report.<sup>20</sup>

Teeth were in pairs in 42.1% of the infants, which was in the lower range of the previous reports [38% - 76%].<sup>8,10</sup> However, eruption of more than two teeth were sporadic. Darwish et al. reviewed 50 studies from literature involving around 500 cases of natal teeth. Only six cases reported having multiple natal teeth, and the cases were mostly associated with systemic disorders such as Ellis-van Creveld, cleft palate, Hallerman-Streiff syndrome, Riga-Fede disease, or Pierre Robinson syndrome.<sup>21</sup> Only one of our nineteen patients (5.7%) reported with three natal/ neonatal teeth (case 19), and it was diagnosed with Riga-Fede disease but without any syndromic or systemic manifestations.

Many investigators have pointed out the essence of a correct diagnosis of natal teeth.<sup>3,8</sup> They used clinical and radiographic findings to determine whether these teeth belonged to the primary dentition or supernumerary. This study has limited taking radiographs to cases where the tooth was expected to be a part of the primary dentition and did not require extraction. Whenever the tooth was to be removed, radiographs were avoided. Parents were informed about the high possibility of losing the corresponding deciduous teeth, as the majority of natal/neonatal teeth, 90-99%, are part of the primary dentition and are not supernumerary teeth.<sup>9</sup> This approach aims to minimize the infants' and parents' exposure to unnecessary radiation, primarily because; pediatric patients are much more radiosensitive than adults.<sup>22</sup>

Some factors should be considered while deciding to maintain or extract these teeth, such as the degree of mobility, inconveniences during suckling, interference with breastfeeding, the possibility of



traumatic injury, and whether the tooth is part of the primary dentition or is supernumerary.<sup>14,23</sup>

A majority of highly mobile teeth end up being extracted due to the theory of possible aspiration. Although many investigators have raised and supported this possibility, it is remarkable that there are no reported cases in the literature on the actual occurrence of such an incidence. On the other hand, spontaneous tooth exfoliation has been stated based on a report by the parents of a 28-day old baby.<sup>24</sup> They have suspected that this tooth was swallowed, a fact that emphasizes the possibility of aspiration.

Another major complication of the natal/neonatal teeth is Riga-Fede disease, where the constant trauma from the sharp incisal edge results in ulceration on the tongue's ventral surface. The resultant traumatic ulcer can interfere with the proper feeding and put the neonate at risk for nutritional deficiencies.<sup>25</sup> Treatment may include grinding to smoothen the teeth, splint with composite resin, and or extraction.<sup>26</sup> In most cases, extraction is the treatment of choice when the infant's feeding problems and infection possibility are considered.<sup>27,28</sup>

Whenever extraction is the treatment of choice, this decision should be made carefully. Infants are especially at risk of vitamin K deficiency bleeding (VKDB). Vitamin K's malabsorption can cause severe bleeding in breastfed infants due to the essential role of vitamin K in the production of prothrombin in the liver.<sup>29</sup>

However, vitamin K prophylaxis might not be needed for babies' older than ten days, as this is the time required for the commensal flora of the intestine to become established and to produce vitamin K. A case series of 15 babies with 25 natal/neonatal teeth by Allwright (1958) revealed no episode of post-extraction hemorrhage even though no therapeutic precaution had been taken, the study has also mentioned that all the extractions were performed in babies older than 20 days.<sup>15</sup>

Since 1961, the American Academy of Pediatrics (AAP) has recommended that a single 0.5 mg to 1.0 mg dose of vitamin K be administered intramuscularly (IM) to all newborns shortly after birth, proven effective in the prevention of classic

and late VKBD.<sup>30</sup> All infants born in BDF-RMS have received an Intramuscular (IM) dose of vitamin K at birth. Thus, all natal and neonatal teeth extractions were done safely under a few drops of local anesthesia.

## Conclusion

In conclusion, the occurrence of a natal/neonatal tooth is a rare phenomenon and presents in females more than males. Whenever present, it shows diverse clinical characteristics and can lead to various complications. A limitation in the current study would be the difficulty in determining this condition's potential etiologies; therefore, extensive prospective studies focusing on possible cases are recommended. Moreover, there is a need for clear guidelines to investigate the clinical indications of cases which require radiographic evaluation and recommendations on their management.

## Conflict of interest

None

## Declarations

- Funding: Not applicable
- Ethics approval: The study was conducted in full accordance with the World Medical Association Declaration of Helsinki and received ethical approval from the Research and Research Ethics Committee of Bahrain Defence Force Royal Medical Services, Military Hospital, Kingdom of Bahrain.
- Consent to participate; Not applicable.
- Consent for publication: approved by the Research and Research Ethics Committee of Bahrain Defence Force Royal Medical Services, Military Hospital, Kingdom of Bahrain.
- Conflicts of interest/Competing interests: Not applicable.
- Availability of data and material; present and available

## References

1. Koussoulakou DS, Margaritis LH, Koussoulakos SL. A curriculum vitae of teeth: evolution, generation, regeneration. *Int J Biol Sci.* 2009;5(3):26–43

2. Massler M, Savara B. Natal and neonatal teeth. *J Pediatr*. 1950; 36: 349-359.
3. Rusmah M. Natal and neonatal teeth: a clinical and histological study. *J Clin Pediatr Dent*. 1991;15(4):251-253.
4. Spouge J, Feasby W. Erupted teeth in the newborn. *Oral Surg Oral Med Oral Pathol*. 1966; 22: 198-208.
5. Hebling J, Zuanon ACC, Vianna DR. Dente natal: a case of natal teeth. *Odontol Clin*. 1997;7:37-40.
6. Mhaske S, Yuwanati M, Mhaske A et al. Natal and Neonatal Teeth: An Overview of the Literature. *ISRN Pediatr*. 2013; 2013: 1-11.
7. Jasmin JR, Clergeau-Guerithault S. A scanning electron microscopic study of the enamel of neonatal teeth. *J Biol Buccale*. 1991;19(4):309-314.
8. Leung AKC. Natal teeth. *Am J Dis Child*. 1986;140: 249-25.
9. Cunha RF, Boer FAC, Torriani DD, et al. Natal and neonatal teeth: a review of the literature. *ASDC J Dent Child*. 2001;23:158-162
10. Bjuggren G. Premature eruption in the primary dentition-a clinical and radiological study. *Sven Tandlak Tidsskr*. 1973;66(4):343-355
11. Bodenhoff J, Gorlin RJ. Natal and Neonatal teeth: Folklore and fact. *Pediatr*. 1963;32:1087-1093.
12. Khandelwal V, Nayak UA, Nayak PA, et al. management of an infant having natal teeth. *BMJ Case Rep*. 2013;2013:bcr2013010049-bcr2013010049.
13. Liu MH, Huang WH. Oral abnormalities in Taiwanese newborns. *J Dent Child (Chic)*. 2004;71(2):118-120
14. Chow M. Natal and neonatal teeth. *J Am Dent Assoc*. 1980;100:215-6.
15. Allwright WC. Natal and neonatal teeth. *Br Dent J*. 1958;105:163-72.
16. Yilmaz R, Cakan D, Mesgarzadeh N. Prevalence and management of natal/neonatal teeth in cleft lip and palate patients. *European Journal of Dentistry*. 2016; 10: 054-058.
17. Bulut G, Bulut H, Ortac R. A comprehensive survey of natal and neonatal teeth in newborns. *Nigerian Journal of Clinical Practice*. 2019; 22: 1489-1494
18. Cizmeci M, Kanburoglu M, Uzun F et al. Neonatal tooth in a preterm infant. *Eur J Pediatr*. 2012; 172: 279-279.
19. Kana A, Markou L, Arhakis A et al. Natal and neonatal teeth: a systematic review of prevalence and management. *Eur J Paediatr Dent*. 2013;14(1):27-32.
20. Basavanthappa N, Kagathur U, Basavanthappa R et al. Natal and Neonatal Teeth: A Retrospective Study of 15 Cases. *Eur J Dent*. 2011;05(02):168-172.
21. Darwish S, Sastry KA, Ruprecht A. Natal teeth, bifid tongue and deaf-mutism. *J Oral Med*. 1987;42(1):49-56.
22. Raissaki M. Pediatric radiation protection. *Eur Radiol. Suppl*. 2004; 14: 74-83.
23. Magitot. Anomalies in the Eruption of the Teeth of Man. *Am J Dent Sci*. 1883;17(8):372-375.
24. Bigeard L, Hemmerle J, Sommermater JI. Clinical and ultrastructural study of the natal tooth: enamel and dentin assessments. *J Dent Child*. 1996;2013:23-31
25. Campos-Muñoz L, Quesada-Cortés A, Corral-De la Calle M et al. Tongue ulcer in a child: Riga-Fede disease. *J Eur Acad Dermatol*. 2006; 20: 1357-1359.
26. Triches T, Mondardo B, Triches R, et al . Natal and neonatal teeth: two clinical cases report. *Rev Gaúcha Odontol*. 2018; 66: 101-105.
27. Leung A, Robson W. Natal teeth: A review. *J Natl Med Assoc*. 2006;98(2):226-8.
28. Goho C. Neonatal sublingual traumatic ulceration (Riga-Fede disease): reports of cases. *ASDC J Dent Child*. 1996;63(5):362-364.
29. Ceratto S, Savino F. Vitamin K deficiency bleeding in an apparently healthy newborn infant: the compelling need for evidence-based recommendation. *Ital J Pediatr*. 2019; 45.
30. American Academy of Pediatrics, Committee on Nutrition Vitamin K compounds and the water-soluble analogues: use in therapy and prophylaxis in pediatrics. *Pediatrics*. 1961;28:501-7.