

11



# ***Surgical studies on external swellings in farm animals***

***A thesis  
Presented to Faculty of Veterinary Medicine, Alexandria  
University***

***In partial fulfillment of the requirements for the Degree  
of  
Doctor of Philosophy of Veterinary Science***


***in***

***(Surgery)***

***By***

***Mofeed Yousef Ahmed Ismail  
( B.V.Sci., Fac. Vet. Med., Tanta Univ., 1995)  
(MCV., Fac. Vet. Med., Alexandria Univ., 2004)***

***(2008)***



---

**Supervision Committee**

**Prof. Dr / Moustafa M. Kassem**  
**Prof. of surgery**  
**Faculty of veterinary medicine**  
**Alexandria university**

Kassem

**Prof. Dr. samir R. Nouh**  
**Prof. and head of surgery Dep.**  
**Faculty of veterinary medicine**  
**Alexandria university**

Samir R. Nouh

**Dr. Ramadan E. Abdel- Wahed**  
**Associate prof. of surgery**  
**Faculty of veterinary medicine**  
**Alexandria university**

Abdel-wahed

**"Surgical Studies on external swellings in farm animals "**

**Presented by**

**Mofeed Yousef Ahmed Ismail**

**For the degree of**

**Ph.D.**

**In**


**surgery**

**Examiners committee.**

**Prof. Dr. Hani M. Johar**


Prof. of surgery and the Dean of Faculty  
Of veterinary medicine  
Cairo University

**Approved**




**Prof. Dr. Ahmed A. M. Kenawy**

Prof. of surgery  
Faculty of veterinary medicine  
Alexandria University




**Prof. Dr. Mostafa M. Kassem**

Prof. of surgery  
Faculty of veterinary medicine  
Alexandria University ( supervisor )




**Prof Dr. Samir R. Nouh**

Prof. and Head of surgery Dept.  
Faculty of veterinary medicine  
Alexandria University ( supervisor )



**Dr. Ramadan E. Abd El- Wahed**

Ass. Prof. of surgery  
Faculty of veterinary medicine  
Alexandria University ( supervisor )



**1/6/2008**

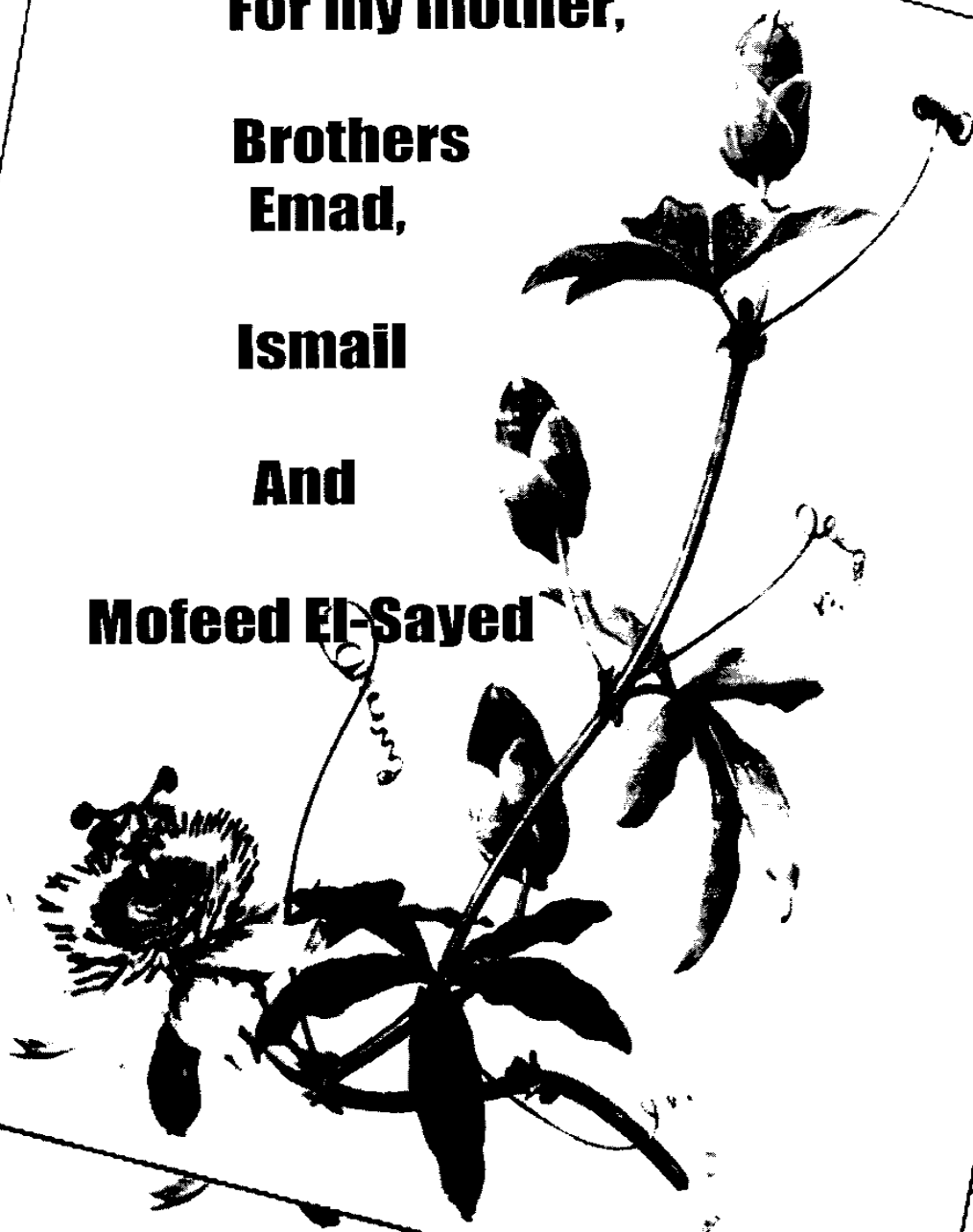
**For my mother,**

**Brothers  
Emad,**

**Ismail**

**And**

**Mofeed El-Sayed**



## **ACKNOWLEDGMENT**

*First of all prayerful thanks to our merciful ALAH almighty who gives us every thing we need.*

*As I wish to express my deep gratitude and appreciations to Prof. Dr. **Moustafa M. Kassem**, Professor of Surgery, Faculty of Veterinary Medicine, Alexandria University.*

*I wish to express my sincere thanks and appreciation to Prof. Dr./ **Samir R. Nouh** Professor and head of Surgery Dep. Faculty of Veterinary Medicine, Alexandria Univeristy.*

*Grateful thanks are due to Dr./ **Ramadan E. Abdel-Wahed**, Assistant Professor of Surgery. Faculty of Veterinary medicine Alexandria University for his continous encouragement, help and support from begining of this work.*

*My deep gratitude is to my colleague Dr. / **Mohamed Sayed Ahmed**, Lecturer of pathology, Fac. Vet. Med., Kafrel-Sheikh University for his kind help for the part of histopathology.*

*Gratefull thanks are expressed to all members of Surgery Dept., Fac. Vet. Med., Alex. Univ., for their help.*

---

## CONTENTS

1- INTRODUCTION.....	1
11-REVIEW OF LITERAURE.....	3
11-1-Neoplastic skin tumors.....	3
11-2- Abscess.....	11
11-3- Bursitis.....	15
11-4- Cysts.....	18
11-5- Swellings due to infectious causes.....	21
11-6- External Hernia.....	26
11-7- Oedema.....	31
11-8- Prolapse.....	33
111-MATERIALS AND METHODS.....	36
IV- RESULTS.....	47
V- DISCUSSION.....	75
V1- SUMMARY AND CONCLUSION.....	84
V11-REFERENCES.....	87
V111- ARABIC SUMMARY.....	

### Introduction

The term swelling in language means any raised curved shape on the surface of the body which appears as a result of injury or an illness. So, if a part of the body swells or if it is swell up it becomes larger and rounder than normal (*Sinclair, 1999*). A swelling may be considered clinically as neoplasm, cyst, hematoma, inflamed and distended synovial bursa, hernia or abscess (*O'conner, 1983*).

Tumor is described as a less precise but commonly used synonym which originally meant a swelling, but it is almost exclusively reserved for enlargement of neoplastic nature (*Smith, Jones and Hunt, 1974*).

Fluctuating swellings at the head and neck regions in farm animals are many and variable from abscesses (*Bialy, 1972; Misk, Nigam and Rifat, 1985; Ahmed, Misk, Taha, Youssef, 1990; Youssef, 1993 and Youssef, Ali and Saleh, 1993*); Haematomas (*Nigm, Misk, and Rifat, 1984 and Bolbol, 1986*); Dermoid cysts (*Makady, Aly and Youssef 1986 and Misk, Ahmed, Ismail and Bayoumi, 1994*); Tassel cysts (*Ali, 1995*); Salivary cysts (*Othman, Ismail and Obead, 1991*); Branchial cysts (*Clark, Kostolish and Mosier, 1989; Youssef, Makady and Ahmed, 1991 and Misk et al., 1994*) and venous diverticulum (*Misk, El-Guindy and Makady, 1984*).

Clinical findings were sufficient for diagnosis of swellings in ruminants in most cases. Histopathological and laboratory examination were indicated in some other cases (*Bailey, 1972; Youssef, 1984 and Ahmed, 1988*).

Bursitis, cysts, abscesses and skin tumors were prevalent surgical affections among fattening animals (*Mohamed, 1988*). Hematoma, neoplastic and non neoplastic skin tumors are prevalent. Non neoplastic skin tumors are classified into non-neoplastic non-inflammatory tumors and inflammatory tumors, like granuloma, callus pyoderma, interdigital cysts and subcutaneous abscess (*Saraha, 1997*).

Swellings may be classified in many ways and there are many factors influencing their treatment and care. Differential diagnosis of such swellings is a main target

***Aim of the work:***

The study under investigation aimed to throw a light on the common and prevalent localized external swellings of the body surface, especially from clinical point of view considering the common clinical features, differential diagnosis and the suitable approach for surgical management.



## Review of Literature

### **1- Neoplastic skin tumors:**

A neoplasm can be defined as "an abnormal mass of tissue, the growth of which exceeds uncontrolled in comparison to the normal tissue and persists in the same excess even after cessation of the stimuli which evoked the change". The cells of a neoplasm continue to multiply indefinitely irrespective of any structural or functional requirements and form an ever increasing mass of the tissue of a particular kind (*Tyagi and Sing 1996*).

Neoplasms of the skin are of particular interest in veterinary medicine and usually respond to surgical excision or other means of treatment (*Wandera, 1989*).

The most common tumors affecting the skin in domesticated animals stated by *Smith, Jones and Hunt (1974)* are cutaneous papillomas, squamous cell carcinoma, melanoma (benign or malignant), equine sarcoid, fibroma, mast cell tumour, lipoma and myxoma.

Tumors of the skin are one of the most frequently encountered neoplasms in domesticated animals (*Moulton 1978*). The variety of cutaneous tumors derived from the different epithelial and mesenchymal skin components are; tumors of the epidermis as papilloma (wart), keratoacanthoma, squamous cell carcinoma and basal cell tumors; tumors of the appendages (adenexa) as sebaceous gland tumors; melanocytic tumors as benign dermal melanoma and malignant melanoma and tumors of the dermis and subcutis as fibroma, fibrosarcoma, lipoma, liposarcoma, hemangiopericytoma, hemangioma hemangiosarcoma, neurofibroma, neurofibrosarcoma, lymphangioma, lymphosarcoma, mast cell tumors and histiocytoma in addition to equine sarcoids (*Conroy 1983, Jones and Hunt 1983, Nielsen 1983, Strafuss 1985 and Muller, Kirk and Scott, 1989*).

#### **1.1- Cutaneous papillomas:**

Papillomas are found to be common, benign and epithelial neoplastic disease in all domesticated animals especially young ones and characterized by warts formation (*Soliman and Iskander, 1963 and Amstutz, 1978a*). It could be caused by either non infectious irritants or species- specific infectious DNA viruses belonging to family papovaviridae (*Theilen and Madewell, 1979*).

Neoplasm of the skin and subcutaneous tissue may be benign, semimalignant, and malignant in nature (*Dietz and Wiesner, 1984*).

The incidence of neoplasm is variable, depending on Anatomical location, type of animal, interests of the pathologist, diagnostic criteria for classification of tumour types, and other ill- defined factors (*Roony and Robertson, 1996*).

*Runnell, Monlux and Monlux ( 1976), Nieberle and Cohrs (1966) and Smith et al. (1974)* recorded that papilloma or warts are very common tumors in all domesticated animals of all ages.

*Oehme and Prier (1974) and Semieka and Muarak (2002)* discussed the distribution of warts on the body of the animals. They stated that in horses, and donkeys papillomas were localized with the size of pea. Others were as large as the man's head. They were hard in consistency and the skin was very often cracked and fissured so that the tumours appeared having an irregular surface resembling cauliflower or bunch of grapes. Papillomas might have a broad attachment or might be pedunculated. They stated that the warts were common on the muzzle, eyelids, lips and ears

Thirty seven cutaneous and subcutaneous equine neoplasms had been recorded throughout three years by *EL-Maghraby (1996)*. Papilloma represented 8,1% from that affections and mostly affecting young horses (not more than two years old).

Cutaneous papillomatosis was recorded by *Barthold, Koller, Olson, Studer and Holtan (1974); Olson, Olson and Hubbard Vanstelle (1992); Hayward, Baird and Meischke.(1993) ; Dawlat,Salem, Ahmed and Karim (1997)and Semieka and Mubarak (2002)*. They stated that the bovine warts caused by bovine papilloma viruses (BPV) and primarily affecting young cattle under two years old.

The predilection sites of bovine cutaneous papillomatosis were found to be the neck, chin, shoulders and dewlap (*Oehme and Prier, 1974; Abu-samra, Aziz and Homeida,1982; Karram, 1985 and Ssenyomga, Onapito Nakasola-Situma and Omara-Opyene,1990*). While *Elzein, Sundberg, Housawi, Gameel, Ramadan and Hassanein (1991)* reported genital papilloma in cattle. *Olson,Olson and Easterday (1982) and Samy and Kadri (1986)* recorded bovine teat papillomas.

**Dietz and Wiesner (1984)** recorded the papillomas and fibropapillomas in the bovine nose, eyelids, lips, ear, the intermaxillary area and neck.

**Semieka and Mubarak (2002)** recorded fibropapillomas in head, neck, limbs, udder, nose and eyelids. Mean while, papillomas were recorded in nose, lower lip, head, wither and limbs. They added that generalized forms of papillomas all over the animal body were recorded in cattle but not observed in donkeys.

**Frenz (1941)** reported high incidence of papillomatosis in cattle, where lesions are mostly found on the abdominal wall, legs, hock and udder. **Formston (1953), and Frank (1964)** recorded papillomas in the genital organs in cattle particularly glans penis of the bulls.

**Nassef, Makady and Taha (1986)** recorded a case of multiple swellings surrounding the anal opening at the junction between anal mucosa and the skin. Pathological examination revealed that the swellings were fibropapillomas and treated surgically.

**Rebhun, Payne, King, Marilyn and Begg (1980)** recorded a form of outbreak of interdigital papillomas in cattle which were found to be confined to the hind feet causing lameness.

In buffaloes, cutaneous papillomatosis was recorded by **Nooruddin, Singh and Nouriyal (1989)** at the incidence of 0.4 % with high prevalence in males. The common sites were shoulders, chest and neck.

**Moustafa, Soliman, Abdel-Tawab and Ali (1989)** recorded papillomas in 25 adult she-buffaloes at the eyelids, base of the horn, skin of the concha, neck, trunk and dorsum of the tail root. The cutaneous papillomas were not found among the growing or newly born buffalo calves and buffalo bulls.

Cutaneous neoplasms are considered the majority of tumors in goats. Squamous cell carcinoma were the most frequent, (**Zubaidy 1976 and Bastianello, 1983**). On the other hand, **Damodaran and Parthasarasthy (1972) and Nobel e, Klopfer, Perl and Nyska (1979)** considered papillomas and melanomas were most commonly encountered in goats.

Cutaneous papillomatosis was recorded in goats by **Theilen, Wheeldon, East, Madwell, Lancaster and Munn (1985)**. They reported three

types of goat papillomatosis; mammary, cutaneous and genital papillomas.

It was also observed that Angora, Saanen or Saanen crossbred adults were at high risk of papillomatosis (*Smith 1981 and Theilen, Wheeldon, East, Madwell, Lancaster and Munn, 1985*).

Cutaneous papillomas, Squamous cell carcinomas, and melanomas represented the majority of skin tumors in goats (*Manning and Scott, 1985*).

*Makady, Mahmoud, Youssef and Saleh (1990)* recorded goat cutaneous papillomatosis on the udder. They were mostly present on the teats. They were of reddish brown colour and mostly had a smooth surface but in few areas, the surface was rough, the papillomas were often elongated structures that sometimes attained a length of 2cm. The majority were conical or rod-shaped growth, rather than pedunculated and papillary.

In sheep, cutaneous papillomatosis was recorded by *Gibbs, Smale and Lawman (1975)* who suggested that sheep papillomatosis caused by ovine papilloma viruses.

*Vanselow, Spradbrow and Jackson (1982)* suggested that the facial ovine papillomas might be transformed into carcinomas. *Bauomy (1988)* reported cutaneous papillomas in the ventral aspect of the neck of sheep and inguinal region in goats.

*Hayward et al. (1993)* demonstrated in sheep fibromatous component of papilloma on the anterior aspect of lower foreleg and most commonly in fetlock of sheep.

In camels, cutaneous papillomatosis was recorded by *Dioli and Stimmelmayer (1992)* at the lips in the form of cauliflower. *Ramadan (1994)* observed the camel warts on the head and neck in the form of cauliflower or small rounded elevations.

*Munz (1992)* recorded camel cutaneous papillomatosis in the ears, eyelids, inguinal and genital regions and in the legs. Most affected animals were under six years old.

General guidelines have been established for the marginal extensions of skin tumor excisions. Wide skin margins, 0.5-1.5 cm and of at least 1.0 cm

have been advocated for tumor removal (*Withrow, 1975; Harvey, 1976; Lavine and Caywood, 1985 and Laing, 1988.*).

*Sawain and Henderson (1990) and Bellah (1993)* preferred 2.0-3.0 cm surgical margin for tumors that tend to recur locally. Lymph nodes were excised in conjunction with the primary tumors and inverting lymphatics when enlarged or known to contain neoplastic cells.

Electrosurgery and cryosurgery have been considered for treatment of skin tumors (*Farris, 1980; Munroe, 1986; and Behery, 1992.*).

*Vegad (1971)* suggested that Anthiomaline probably, cures warts by cutting their blood supply. Sessile and miniature pedunculated warts were treated more successfully than large sized pedunculated warts of long standing nature.

*Bain (1979)* stated that the use of wart vaccine is of very little success. Surgical removal of large sized warts is advised. Cryosurgery is available (*Butler, 1960*). Partial excision combined with administration of autogenous vaccine is possible in calves with small pedunculated papillomas (*Amstutz, 1978a and Scenyonga et al., 1990*). *Kassem (1980), Dawlat et al. (1997) and Saraha (1997)* applied surgical excision successfully. Surgical excision and cauterization of the lesion sites with silver nitrate was applied. (*Abu-Samra et al., 1982*).

#### **1.2- Cutaneous squamous cell carcinomas (SCC).**

The chief cause of SCC is unknown. While *Jones (1997)* estimated that there is a relationship between solar irradiation and the occurrence of SCC of the eyelid in cattle.

Squamous cell carcinoma appeared as ulcerated, raised nodular growth of variable size from 3 to 15 cm. History of the cases revealed the appearance of the lesions from several months. It was the most common malignant tumors recorded in equine (*Semieka and Mubarak, 2002*) where the growths were recognized as a single mass or multiple growths. Squamous cell carcinoma were found affecting the eyes, forehead, neck, and vulva of equine.

*Frank (1964)* mentioned that carcinoma occurs so frequently on various portions of the animal's body, having a tendency to invade the

surrounding tissues. In the horse, the eye is a frequent location for carcinoma, then the mouth, sinuses, alveoli of the cheek teeth, nostril, glans penis and prepuce. *Kelly (1974)* stated that neoplasm of the skin and penis of the horse are not infrequently invaded by squamous cell carcinoma. Meanwhile, *Blood and Henderson (1979)* recorded neoplasms in the equine skin and penis.

*Pascoe and Summers (1981)* mentioned that squamous cell carcinoma was among the most frequently occurring tumors in horses.

Squamous cell carcinoma resembled 24.09% from all neoplasms recorded from 1970- to- 1974 by *Sundberg (1977)*. However, equine eye and external genitalia had been reported to be most common site for such type of tumors (*Koch and Cowles, 1971 and starfuss, 1976*). *El-Maghraby (1996) and Pulley and Stannard (1990)* mentioned that squamous cell carcinoma has a tendency to develop in areas of unpigmented skin as mucocutaneous junctions.

Cutaneous squamous cell carcinoma (SCC) was recorded in bovine eyelids, vulva and horns (*Radostitis et al., 1994*).

*Gupta, Sadana, Kuchroo and Kalra (1980)* recorded SCC in the right horn of a bull with metastatic growth in the frontal sinus.

SCC was recorded as one of the most common skin neoplasm in domesticated animals (*El-Seddawy and Abd-Elaal, 1996; Basher, Severin, Chavkin and Frank, 1997; Guedes, Filho and Lago, 1998; Mair,love,Schumacher and Watson 1998; Crocker and Rings,1998; Auer and Stick, 1999 and Mcgavin, Carlton and Zachary, 2001*).

Carcinoma is the most common types of neoplasm occurring externally in bovine. The most areas subjected to SCC are the feet, eye, eyelids, vulva, anus, penis and the base of the horn (*Adams, 1974*).

*Hamir and Parry (1980)* found that the incidence of ocular SCC in bovine represents 65.5% of the total cases of bovine tumors.

*Abou-El-Ella and Tantawy (2000)* recorded three cases of SCC in the external ears in buffaloes.

With regard to the incidence of SCC and its sites among domestic animals, *Anderson and Kirkwood (1969), Jennings (1984) and Jubb and*

**Kennedy (1993)** explained that SCC is more common in the eye and ocular adenexa than the skin of cattle and horse.

SCC is of economic importance in sheep and goats especially in those valuable animals. This tumor decrease the marketability causing more serious economic losses such as decrease milk and meat production as well as decrease skin grade and its processing (*Al-Sobayil, Ahmed and Mehana, 2005*).

**Ismail (1994)**, during a survey on some external ear affections among domestic animals, recorded 3 cases of ear SCC in sheep. Tumors of the external ear were mainly papillomas or warts and rarely chondrosarcoma and SCC.

Ovine SCC was recorded by **Damodaran and Parthasarathy (1972)** at incidence of 60.7% of the total cases of ovine neoplasm. Cutaneous SCC represented 20% of the total cutaneous neoplasm in goats.

**Bolbol, El-Shazly and Al-Ghasnawi (1991)** reported the ovine SCC everywhere on the body with no predilection sites. High incidence was found in sheep than in goats.

**Ramadan, Gameel and El-hassan (1991)** stated that the highest incidence of SCC in sheep was recorded at 3-6 years of age with high prevalence in females (92%). The eyes, abdomen, neck, ears, flank and chest were the predilection sites of SCC in sheep.

In camels cutaneous SCC was recorded by **Trageldin and Omer (1986)** as slightly indurated nodules with central ulceration or larger ulcer with raised edges and an irregular base covered with crusts.

**Ramadan and El-Hassan (1987) and Ramadan (1994)** observed the neoplasm on the camels in skin of body sides, flanks, mouth, behind the sternal pad, side of hock or at the dorsal part of the nail of the feet.

Trails for treatment of cutaneous SCC included radiotherapy (**Banks, Roberts, Morris and Hussey, 1972; Banks and Morris 1975**), cryosurgery (**Joyce, 1976; and Venkatasuany and Ramarkrishna 1996**) or surgical management (**Misk, Nigam and Rifat, 1984; Semieka and Mubarak, 2002; El-Sobayl et al., 2005**).

Complete auricular amputation including the swelling was performed without any complications and metastasis (*Abu-El- Ella and Tantawy, 2000*).

### **1.3- Fibroma and fibrosarcoma:**

*Mowen and Groot (1982)* recorded that the equine sarcoid is a sarcoma-like tumors of the dermis.

*Jones and Hunt (1983)* mentioned that the equine sarcoids are frequent in mules and donkeys. They are often multiple with variable shapes and bases in the subcutaneous tissue of the lower legs, head , and prepuce. They may reach the size of man's fist. The covering skin is thick, rough and frequently ulcerated and infected.

*Shaban, Kadri, Moursi and Kamel (1981)* found that non of the surgically excised tumors re occurred or metastasized except those of external nares (mixed tumors) which re occurred after three month, with enlargement of the submaxillary lymph nodes.

*Scott (1988)* recorded that fibromas and fibrosarcomas were common in the head, neck, flank and legs. Fibromatosis was reported in the pectoral region of an aged horse.

*Misk et al. (1984) and Gaballa and Fargaly (1991)* mentioned that the surgical excision of the skin neoplasm was satisfactory except with the diffuse neoplasm which involved a large area of the skin.

*El-Maghraby (1996)* reported that while skin tumors are more amenable to surgical excision than the other types of tumors which arise from other deeper sites, some complications as skin defect, arthritis, recurrence and/or metastasis might complicate the management.

*Kassem (1980)* recorded fibromas in the cheek, perineum and the sides of the neck of calves and camels. *Nayak, Base, Ray, Mitra and Mohapatra (1990)* reported a soft fibroma in the oral cavity of a cow. *Banga, Randdhawa, Singh and Gupta (1990)* detected a new fibroma in a bull legs, abdomen and cranial region with varying sized encapsulated nodules.

Fibroma in goats was recorded by *Damodaran and Parthasarathy (1972)* in the ear and perineum.



Myxofibroma in camels was recorded in the area of the left mandibular lymph node (*Chaffee, 1964*) and teat skin of she-camel (*Sara, Chouhan, Arya, Shatma and vays, 1982*).

*Bolbol, Bendary and Abou-Elfotouh (1992)* reported 4 cases of sternal fibromas in she-camels.

*Ramadan (1994)* stated that fibromas in camels might occur more commonly at the lateral aspect of the tarsal joint and lateral part of the foot and in front of the chest and sternum. It appeared pedunculated, covered with intact skin, tend to invade locally and re-occur after surgical excision.

## 2- Abscess:

*Oehme (1988)* stated that, an abscess may be formed as a sequel to a wound when pathogenic organisms become imprisoned in any subcutaneous tissues. The rapid formation of a purulent exudates leads to the development of a pus-filled space.

*Blood and Radostits (1989)* stated that most subcutaneous abscesses are the result of traumatic skin penetration with infection. On rare occasions, the infection may reach the site by haematogeneous means or from an internal organ.

*O'conner (1985) and Greenough (1988)* described the skin abscess as very painfull hot local swelling with soft center, then fluctuating with no febrile disturbance. Subcutaneous abscess is most commonly encountered as localized collection of pus. Pyogenic bacterium was injected under the skin when it is punctured and localized infection developed in 2-4 days (*Muller et al., 1989*).

*Soliman, El-Shair, and Abd-el Twab (1988)* recorded an abscess formation in a fattened bull due to the necrotizing toxins of isolated staph-aureus.

*Pavletic (1985)* defined an abscess as a localized collection of pus. *Radostitis et al. (1994)* reported that most subcutaneous abscesses might result from traumatic skin penetration with infection and rarely infection might be via hematogenous mean or from an internal organs, e.g. from traumatic reticuloperitonitis.

*Leil (1993)* stated that abdominal wall, thigh and urethral regions

were the most common sites for abscess formation in sheep and goats.

*Bauomy (1988)* found that abscess was localized more commonly in the intermandibular space, upper third of neck, abdominal wall and thigh in sheep and goats.

*Tadayon, Cheema and Mohammed (1980)* found that superficial abscesses occurred much higher in goat than sheep. This might be due to the goat is not well protected by the hair coat as in sheep.

*Youssef (1993)* reported that most of the swelling in head and neck region were abscesses. Most abscesses were detected in the caudal cervical region and took the same picture of caseous lymphadenitis. Abscesses may be localized in parotid region of sheep and goats or close adhesive with the jugular vein on the lateral aspect of the neck of buffaloes, camels and cattle.

*Abu-Seida (1998)* stated that the head, neck and extremities were the most commonly affected regions with subcutaneous abscesses in ruminants.

Incidence of umbilical abscess represents 72% of surgical affections in calves between 2 weeks to 6 months old. It has been reported that buffalo calves were more susceptible to umbilical infection than calves (*Khamis, 1979; Roberts, 1980; Youssef, 1984 and El-Sayad, 1991*).

*Diefinderfer and Brightlong (1983)* stated that umbilical abscess with infection into the urachus may have a connective tissue sealing it from the urinary bladder.

*Shearer (1986)* stated that internal umbilical abscessation occurred in dairy calves usually about four months old affecting both males and females. The surgery should be carried out as soon as possible while the calf is still young which reduces the possibility of the abscess bursting. Strict attention to hygiene at birth and satisfactory cleaning of the navel would limit the possibility of infection and help to prevent this condition from arising.

*Blowey (1991)* recorded a case of umbilical abscess in four-month old Friesian male. The mass was initially hard, hot, and painful. Pyrexia led to systemic illness. Parenteral antibiotics resulted in a change to a more fluctuating swelling, which was successfully lanced and drained.

*Bain (1963)* observed that navel abscess can be encountered from

**Bain (1963)** observed that navel abscess can be encountered from shortly after birth up to 30 days- old. They are quite common and should be treated as quickly as possible because of the potential danger of extension of the infection to bladder, liver, or blood stream. They are treated surgically.

**Smart, Ferguson and Vaillancourt (1978)** stated that omphalophlebitis is a common problem in the newborn calf. The usual sequelae can be an abscessed navel, bacteremia, septic arthritis, meningitis and abdominal abscesses. The two enlarged remnants of the umbilical arteries were situated lateral to the urachus. They were ligated and transected at the level of urinary bladder. The urachal abscess and the urachus were resected by removing the adherent portion of the abdominal wall and the cranial part of the bladder.

**Andrews, Blowey, Boyed and Eddy (1992)** described abscesses of the jaw which found as round discrete swelling at the cheek.

**Biale (1972); Nguhiu-Mowngi, Gathumbi, Kihurani, Mbith and Mbiuki (1989) and Daneji, Djang, and Ogunsan (1996)** reported a typical actinobacillosis of cattle and camels confined to the dermis, subcutis and lymphnodes of head and neck region without lingual involvement with the result of multiple abscessation.

**Biale (1972); Ashfaq and Campbell (1980); Tadayon et al. (1980); Falade and Smith (1985); Youssef (1993) and Loyed (1994)** mentioned that corynebacterium pseudotuberculosis are responsible for superficial abscesses in sheep and goats.

**Tadayon et al. (1980)** stated that most of the superficial abscesses in sheep and goats occur mainly due to systemic diseases such as caseous lymphadenitis.

**O'Doherty, Prendergast, Scanlon, Schofield, Doherty, Frame and Bassett (2000) and Williamson (2001)** stated that caseous lymphadenitis was a chronic contagious suppurative infection affecting sheep and goats caused by Corynebacterium Pseudotuberculosis and characterized by abscess formation on the skin, internal and external lymph nodes, and internal organs. While **Dorella, Pacheco, Oliveira, Miyoshi and Azevedo (2006)** reported that once established this disease is difficult to eradicate because drug therapy was not effective and because the clinical detection of infected animals was

of limited efficiency.

*Bialek (1972)* described many abscesses of the salivary glands. The cause was infection by several kinds of bacteria, or bruising of the jaw or wounding of the mouth lining by roughage stems or beards from plants are the main causes.

*Ahmed et al. (1990)* recorded a case of foreign body abscess in the mandibular salivary gland in a cow.

*Saraha (1997)* stated that, subcutaneous abscesses occurred most commonly in retropharyngeal region in most animal species.

*Ramadan (1994)* reported that camel abscesses were more frequent in sites of tick bite mainly around the base of the tail, neck, intermandibular space and shoulder.

*Ahmed et al. (1990); Andrews, Blowey Boyed, and Eddy (1992); and Youssef (1993)* found that most abscesses were detected in head and neck region. In buffalo and cattle, located in the caudal cervical region, jaw, salivary gland regions, and jugular furrow.

*Baomy (1988)* recorded that the predilection seats of abscesses in sheep and goats were the parotid region, upper third of the neck, right or left abdominal wall, the intermandibular space, angle of the lower jaw, and lastly the region of the thigh.

*Blood and Radostits (1989) and El-Sayad (1991)* reported that the area behind the elbow was the most predilection seat of abscess formation in cattle and buffalo, which may be caused by penetration of sharp foreign bodies from the reticulum to the abdominal wall, or may be due to external infection through a break in the skin near the elbow. The clinical signs of abscesses and other local aggregations of pyogenic lesions are fever, depression, lack of appetite, pain, arching of the back, severe lameness, weight loss, local swelling and edema. They added that in umbilical abscess, the umbilicus is enlarged, painful on palpation and may be closed or draining purulent material through a small fistula. The calf is moderately depressed, febrile, and do not suck normally.

*Frank (1981)* mentioned that some skin abscesses may be formed without any visible skin breach. On the other hand *O, connor (1985)*, recorded that a breach in the skin or mucous membranes may open way for microbial invasion then abscess formations.

*Bialely (1972) and Ahmed et al. (1990)* reported that the main symptom was swelling in the location of abscess the swelling was hard in consistency and have a loose attachment to the underlying tissues. Abscess was diagnosed by exploratory puncture and sometimes radiographic examination.

*O'connor (1985)* mentioned that the use of local antibiotics in the abscesses is preferable beside systemic antibiotics according to the type of causative agents. Cephalosporin, cloxacillin or sulphadimethoxine-trimethoprim was continued for 10 days while penicillin, ampicillin or chloromycetin was advised in abscess caused by anaerobes (*Bright and Probst, 1985*).

*Weaver (1986) and Greenough (1988)* treated such condition by surgical interference and when the abscess is encapsulated, they recommended its removal.

After maturation and pointing of an abscess by hot compresses, it is treated by surgical drainage and systemic antibiotics (*Furieux, 1975, O'connor, 1982 and Bright and Probst, 1985*).

### **3- Bursitis:**

Bursae are cavities lined by synovial membrane, which either typical (deep) present at birth or atypical (superficial) acquired after birth. Bursitis is the inflammation of bursa with resulting synovial effusions into the bursal cavity. The resulting swelling may be painful (*Venugopalan, 1994*).

*Newton, Wilson, Allen and Swenberg (1974)* mentioned that the term hygroma, is used to describe the soft, fluid- filled mass that developed on the elbows. They reported that surgical excision of hygroma is very successful which depend in a part on post operative immobilization and protection of surgical site enabling healing by second intention. Aspiration and corticosteroid infusion had yield limited success.

*Johnston (1975)* stated that hygroma of the elbow in dogs should not be treated either by aspiration and injection of a corticosteroid preparation into the cavity of the hygroma, as skin ulceration following excision of hygroma and wound break down are considered main complications. A simple drainage procedure was used successfully.

The intra-articular and intrabursal injection of adrenocortical steroids or their synthetic analogues recommended as an adjunct to general therapeutic measures to suppress inflammation in peripheral arthritic joints, tendon sheaths and bursae (*Van pelt, 1963*). Therapy is directed to prevent the continued trauma and to relieve inflammation of the subcutaneous bursa by aspiration of the synovial fluid and intrabursal injection of a synthetic corticosteroid derivative (*Bolbol, 1978*).

*Plakhotin (1981)* mentioned that bursitis appears primarily due to closed and open mechanical injuries. They less often result from spreading purulent processes from surrounding tissues and occasionally haematogenous infection as "Brucellosis and T.B. sepsis". Moreover, trauma of bursae in cattle commonly occur in crowded accommodation of animals, specially on hard concrete steel floors without litter and soft surfacing.

Concerning presternal bursitis in buffaloes and cattle, *Helmy, Fouad, Khamis and Hosny (1970)* found that 10% of the examined calves were affected with bursa presternalis and incriminated trauma to be the main cause.

Presternal bursitis was recorded and the causes mainly due to continuous traumatization of the site of presternal region with the hard manger. The traumas of bursae in cattle commonly occur in crowded farms especially those with concrete steel floors without litters (*Plackhotin, 1984 and El-Sheikh, 1996*).

Local treatment of cystic form of bursitis was successfully obtained after aspiration of cystic fluids and intracystic injection of corticosteroids. Also surgical extirpation of the fibrous form of bursitis proved to be the suitable method for treatment under the effect of local infiltration anesthesia (*El-Guindy, 1988 and El-Sheik, 1996*).

*Kenawy (1988)* stated that this type of affection was more common in buffalo especially young ones. The cyst was found at the presternal area and

began as a fluctuating small cyst. Exploratory puncture revealed serous yellow fluid. The size of cyst varied from the size of an orange to the size of a hand ball. Surgical excision of the cyst was indicated as a radical treatment.

*Abdalla (1999)* indicated surgical excision as a radical treatment especially in the hard and fibrosis cysts. Local application of iodine ointment 10% twice daily for 5-7 days resulted in recovery in some cases. Opened ulcerated cysts were treated as old wounds. Recovery occurred 3 weeks after daily dressing.

*Plakhotin (1984)* stated that inflammation of mucous and synovial bursae occurs in all farm animals. Precarpal bursa is predominantly affected in cows. Bursitis of knee and metatarsal joint, tuber coxae and navicular bone is less common. Bursitis appears primary due to closed and open mechanical injuries. Traumas of bursae in cattle commonly occur in crowded accommodation of animals on hard, especially concrete steel floors without litters and soft surfacing inflammation of presternal bursa predominantly occur.

*Dietz and Wiesner (1984)* mentioned that, aseptic bursitis often can be cured completely by repeated intrabursal injection of glucocorticoids.

*Frank (1981), and O'Connor (1985)*, advised surgical removal of the chronic form.

*McIlwraith. (1987)* stated that in bursitis associated with elbow, hock or carpus, the first principle of treatment is the prevention of further trauma to the region. Local injections of corticosteroid and pressure bandage have been used with variable results. The implantation of penrose drains in refractory cases for a period of 10 days to 2 weeks allows fluid drainage and acts to enhance fibrosis and obliteration of the cavity.

*Oehme (1988) and Venugopalan (1994)* defined a hygroma as a swelling that occurs on the knees of cattle and is caused by repeated trauma of the area. It will contain a varying amount of synovial like fluid. If the condition is acute, it will usually resolve if the cause of the trauma can be avoided. In cases where the hygroma has become established for some time there are several possible lines of treatment; 1-draining and weekly injection of cortisone and antibiotics, 2-surgical removal, and 3-destruction of the enlarged bursa may be accomplished by first draining it through a needle and then injection of 5% solution of copper sulphate or tincture of iodine.

The bursa then may be opened and either curetted or extirpated.

*Nguhiu-Mowngi, Mbiuki, and Maina (1991)* stated that cauterization of the precarpal bursa with lugol's iodine for 3 days facilitated surgical excision of the bursa and minimized ensuring haemorrhage. The bursa was simply peeled as if already detached from underlying tissues.

*Venugopalan (1994)* mentioned that, chronic bursitis can be treated by local application of absorbent topics like iodine ointement or reducine, "antiphlogestics" (reducine contains iodine 4 parts plus potassium iodide 16 parts plus glycerine 80 parts). Application of a counter-irritant like biniodide of mercury ointement (1 in 32 to 1 in 8) gave good result. Acute bursitis is treated on general principals as for acute inflammation. Injection of hydrocortisone acetate into the bursa helped to suppress the inflammation. When bursitis is due to infection, antibiotics may be injected into the bursa. Penicillin G sodium, dihydrostreptomycin and neomycin are the antibiotic commonly used. Purulent bursitis is treated like an abscess.

*Abdel-Wahed (2001)* recorded a case of olecranon bursal swelling in a heavy pregnant she-donkey. One month post parturition, subsiding of the bursal swelling was noticed.

*Honnas, Schumacher, McClure, Crabill, Carte, Schmitz and Hoffman (1995)* reported that treatment of olecranon bursitis by needle aspiration of fluid from the mass, followed by injection of corticosteroids had a good result. They added that surgical treatment of hygroma of elbow by en-bloc resection give good result and healing occurs by primary intention.

*McIlwraith and Trotter (1996)* mentioned that treatment of hygromas is varied and depends on the chronicity of the condition. Spontaneous resolution has been seen in acute cases. They added that all forms of therapy often leave some cosmetic defect in the size or appearance of the limb.

An endoscopic approach to the calcaneal bursa is recommended wherever possible to decrease complications associated with surgery in this region and improve the diagnosis of infectious and non-infectious calcaneal bursitis (*Ingle-Fehr and Baxter 1999*).



**Ramadan, Hashim and Bukhari (2007)** recorded (4 cases) of carpal hygromas in sheep one of them was attributed to brucella infections. They advised surgical excision of the hygromas containing sterile fluid while that with brucellae organisms in its synovial fluid was not operated to avoid the possibility of the infection spreading.

#### **4-Cysts:**

**Corne, Lloyd and Carter (1963)** stated that cystic skin lesions in small ruminants were associated with systemic illness and with secondary development of carcinoma.

From 69 cases of fluctuating swellings at the head and neck regions of some farm animals, **Ismail (1997)** recorded 25 cases as Dermoid cysts, 6 as Tassel cysts, 3 as Salivary neck cysts and 2 as Branchial cysts. The cutaneous cysts were included in the non inflammatory tumors (**Conroy, 1983**).

**Radostitis et al. (1994)** stated that cysts contained by an epithelial wall enclosing amorphous continents or living tissues. They could be congenital, inherited or acquired.

#### **4.1- Dermoid cysts:**

Dermoid cysts are congenital developmental failures of epidermal closure characterized by the presence of swellings lined by stratified squamous epithelium and contains a jumbled mass consisting of fluids, muddy materials and separate tufts of hairs (**Jubb and Kennedy, 1970, Misk et al. 1994, and Purohit, Chouhan, Dudi and Vyas, 1989**).

**Kassem, Kenawy, Nouh, Hassieb, Bayomi and El-Sawak (1992)** recorded dermoid cyst at the neck of camels. It was hard, sessile and of orange size.

**Fouad, Gohar, Sheta, El-Mahdy and Abu-Seida (2001)** recorded cases of dermoid cysts in camels. History of all cases revealed that all of them were congenital. The cysts appeared as circumscribed of 3-15 cm in diameter, fluctuating, movable, and painless swellings.

**Purohit et al.(1989) and Ramadan (1994)** recorded dermoid cysts in camels in the antero-lateral aspect of the upper part of the neck just over or near the jugular vein as circumscribed (5-15cm in diameter), mobile, soft, fluctuating cysts and inner surface of the cysts might be divided into compartments containing hair tufts and a coffee coloured glandular secretion.

The most common type of dermoid cysts in the donkey is the monolocular form present at the midline of the ventral aspect of the upper third of the neck. Surgical excision of dermoid cysts was indicated as a radical treatment for cosmetic purposes only, as they are not painful and do not produce a harmful effect on the animals (*Frank, 1981, Jubb et al., 1985 and Misk et al., 1994*).

*Makady et al. (1986)* reported a case of dermoid cyst in a male camel. The cyst was at the base of the right ear. From the history of the case it was enlarged slowly. Exploratory puncture revealed a muco-serous fluid. The case was treated surgically by complete excision of the swelling under the effect of local infiltration anesthesia and the subcutaneous tissue was coapitated with absorbable suture material and silk was used to close the skin wound in a simple interrupted pattern.

*Eissa (1992)* stated that dermoid cysts were observed on the ear of camels. The swellings were fluctuated and exploratory puncture revealed presence of dirty fluid mainly grayish-brown in colour and the mass can be differentiated into muddy clay-like material and separate tufts of hair. Complete surgical excision of the swellings was performed.

#### **4.2 - Branchial cysts:**

*Misk, Ahmed, Ismail and Bayomi (1994)* detected soft, fluctuating, painless swelling in the subcutaneous tissue behind the mandibular angle at the upper part of the neck. The cases were diagnosed as branchial cysts. Surgical excision of the cyst was suggested as a radical treatment.

*Ismail (1999)* diagnosed 2 cases in buffalo calves. The clinical examination revealed existence of soft, fluctuating, painless, non-inflammatory, and well defined gradually developed swellings. These swellings were present subcutaneously below the level of the ear, extending downward to the under part of the lower jaw. The size of these cysts did not exceed the size of an orange and the exploratory puncture revealed milky-like colored fluid. Surgical excision of the cysts was the radical treatment and necessitated careful blunt dissection to separate the sac from the surrounding vital structures. Histopathological examination revealed that the cystic wall was lined by stratified squamous epithelium.

*Abdalla (1999)* diagnosed 2 cases; one buffalo and one cattle located

at the ventrolateral aspect of the upper third of the neck. One case was in left side (cattle) and the other in right side (buffalo). Total excision of the intact cyst has been performed by blunt dissection after careful incision of the skin.

Differential diagnosis of brancheal cyst from other swellings (cervical abscesses, haematomas, tumors, and mucoceles) was accurately confirmed by exploratory puncture. The milky character like fluids of the cyst is highly diagnostic (*Ahmed, 1988*).

#### **5- Swellings due to infectious causes:**

##### **5.1- Lumpy skin disease (LSD):**

*Hall (1977)* mentioned that (LSD) is an acute infectious disease of cattle, characterized by eruption of large number of cutaneous nodules and by superficial lymphadenitis.

The cause of the disease is neethling virus which belongs to the family pox viridae (*Andrews, Pereira and Widly, 1978; Kahrs, 1981 and El-Kanawaty, 1989*). The most obvious and characteristic lesions were the skin nodules (*Ismail, 1990*).

*Ali and Obeid (1977)* discussed that there are at least 3 agents associated with LSD, one an "Orphan virus" is generally present in the lesion but is apparently not in any way responsible for the disease. Another virus, which is termed "the Allerton virus" is responsible for a disease syndrome and symptoms similar to but not identical with true LSD. True LSD is caused by "Neethling virus" this virus is responsible for the infectious and serious disease. It is related to pox virus of sheep.

*Kahrs (1981)* described that in LSD in addition to nodular cutaneous eruptions and lymphadenitis, there is oedema of legs and brisket.

*Hafez, Tawfik, Shaker and El-Danaf (1992)* reported that LSD clinical picture was more sever on newly – born calves. The morbidity rate changed between 7.22 and 16.93% without mortality. Skin nodules were scattered all over the body affecting soft tissues such as udder, vulva, and scrotum. They added that the animals were symptomatically treated with long acting terramycin then followed by a course of streptopenicillin. In addition, animals suffering from oedema of limbs were treated with 4% iodine ointement. Some cattle were injected with Devidri forte (AD3E). Some cases were given Arrhenal for blood parasites and citarin injections for nematodes.

*Radostits, Blood, and Gay (1994)* listed the symptoms of LSD as fever, epizootic appearance of intradermal nodules on all parts of the skin. There was only one report of natural occurrence of LSD in a species other than cattle, in water buffaloes but no further cases were recorded.

*Abu-Seida (1998)* recorded only one case of LSD in an old cow where the lesions appeared as persistent, hard painless intradermal lumps of 1-5 cm diameter each lump had central ulcerative spot.

*Weiss (1963)* discussed that the nodular lesions may cover the entire body and they involve all layers of the skin and frequently penetrate to the subcutaneous tissues.

*Hall (1977)* described that the skin nodules may indurate and persist for many years or they may develop to what are termed "sitfasts", i.e. a dry necrosed section which separates from the original nodule leaving a granular crater of varying depth and size which heals with scar tissue. This may take 1 to 2 months to occur. As the sitfasts penetrate deeply into the subcutaneous tissue they may become infected by secondary invaders, leading to deep suppurating wounds and sometimes lead to metastasis throughout the lymphatic system, the lungs and other organs. The virus does not respond to treatment, but secondary infection should be treated with antibiotics and sulphonamides. A vaccine prepared from attenuated neethling virus on lamb kidney tissue culture has been proved to be effective and is now in general use.

*Ismail (1990)* reported that complication of LSD leads to septic arthritis, blepharoconjunctivitis and septic mastitis.

#### **5.2- Oedematous skin disease (O.S.D)**

Local ulcerative lymphangitis in buffaloes is known as "oedematous skin disease" (O.S.D) It considered as another type of pathological oedema. *Corynebacterium pseudotuberculosis* was seen as the causative agent of the disease, (*Barakat and Eid, 1971; Fouad, Saleh, Khamis, Shouman and Fahmy 1974; Kassem, 1980; Khater, Deeb; Salem, Bayoumi and Taha, 1983; and Fouad; Misk and Kassem, 1984*).

*Microfilaria* parasites had been isolated from the blood of animals affected with oedematous skin disease (*Khamis, Helmy, and Fahmy, 1973; and Fadzil, 1977*).

Concerning the symptoms of oedematous skin disease, *Awad (1966)* described the symptoms in buffaloes as skin nodules with slight ulcerations as well as oedema and lameness in one or two limbs. Such nodules gradually increase in number and appear well circumscribed and firm. They were intracutaneous, varying in size from a walnut to an orange. The most common seats of affections were the neck, belly, perineum and legs. In some cases the nodules were arranged in chain along the course of lymphatics and the skin nodules had undergone necrosis, leaving deep suppurative lesions.

*Soliman Agamy and Sayour (1963)* stated that the affected animals are mainly buffaloes, much less among cattle and some old cases in horses, mules and donkeys. The affected animals usually had one or more swellings in the dewlap, side of the abdomen, shoulder or side of the head and neck. The swellings varied in size from 5 to 20 cm in diameter. These unopened edematous nodules contained bloody edematous fluid and pus in some cases. The regional lymph nodes in the affected area were swollen and contained pus in some cases. The parasitological examination was negative, but the bacteriological examination revealed presence of *C. pseudo-tuberculosis*.

*Fouad et al. (1974)* observed that oedematous skin disease affects mainly buffaloes more than cattle. The symptoms were chiefly local oedema in one or more than one limb. Sudden sloughing of an extensive area of skin at distal region of the pelvic limb was observed leaving an area of hypersensitive raw tissue. The lesions bled copiously, but no lameness was present.

*Khamis et al. (1973)* isolated microfilaria from nodular ulcerative dermatitis (oedematous skin disease). The most important clinical signs were nodular ulcerative dermatitis with or without scab formation showing special tendency to bleed. The lesions were located on chest wall, side of abdomen around the umbilical region, behind the elbow, at the metatarsal and metacarpal regions, and on the teat. Intracutaneous firm nodules usually appeared but with no pus formation. They were surrounded by subcutaneous nodules usually along the course of lymphatics. He recommended Antimosan or Neguvon (Bayer) which had distinct advantages over the arsenical preparation for the treatment of edematous skin disease. Neguvon stood as the best drug for the treatment of the disease, and was given subcutaneously in a dose of 3ml/100 kg. B.W. and repeated after one week.

*Das, Tripathy and Misra (1975)* isolated immature and adult

parasites of stenofilaria from the epidermis and dermis. There were inflammatory changes which were more pronounced around the microfilariae. The skin lesions were observed mostly on the hump nick, occasionally on the pall, base of ear, dewlap, back and chest regions.

*Ishihara, Sasaki, and Kitagawa (1982)* recorded cutaneous haemorrhagic parafilaria in 2 cows in Japan. The signs included intermittent haemorrhage from local cutaneous nodules on the neck, shoulder and the trunk. The nodules were firm, slightly raised and about 15 mm. in diameter. The hair coat was normal. The skin showed slight edema on the surface of nodules.

*Shaaban, Ibrahim, Awad, and El-Bulkeny (1986)* studied 73 buffaloes affected with the so-called edematous skin disease. Animals showed swellings on the whole of one fore or hind limb. Regional lymph node reached 10-15 cc. in size. Lymph vessels become corded with nodular chain. Exploration of such nodules revealed presence of purulent bloody material. With pressing over an opened nodules, the content with large odour less necrotic masses evulsed outside its cavity and thick septa were separating each nodule from the other.

*Hamoda (1996)* found that the clinical signs of edematous skin disease in buffaloes were mainly in the form of edematous swellings, subcutaneous nodules and cording of lymphatic vessels, enlargement and suppuration of superficial lymph nodes. Edematous swelling was aroused due to increase permeability of blood vessels and impaired drainage through early damaged lymphatics. Similar observations were found by *Abd-Elgalil, Ammar, Youssef, and Kenawy (1986)*.

*Soliman (1999)* reported that the clinical symptoms of the most infected buffaloes with the So-called edematous skin disease were hemorrhagic and ulcerative dermatitis. Multiple nodules, (opened or closed) were seen along the course of lymphatic accompanied with enlarged regional lymph node. The lesions were observed on the lateral and medial aspects of the legs and \ or lateral and ventral regions of the abdomen. Bloody exudates was seen during acute stage then become white thicken creamy during chronic stage.

Many trails were performed in field cases for treating edematous skin disease. *Soliman et al. (1963)* gave an antibiotic medicament as penicillin 3-4 million I.U. subcutaneously every 24 hours. They obtained good results in

recent cases, but old ones with already formed pus and necrosis must receive at first surgical treatment, which could be supplemented with systemic antibiotics as formerly described.

*Fouad et al. (1974)* also advised this compound, which was successfully used, for the treatment of this disease. In addition to the use of antibiotics against the secondary invaders should also be included. Many investigations proved that some cases were cured without local treatment, and the formed ulcers dried rapidly when the bleeding stopped. Other cases needed the second or third dose at one week interval. Few cases were treated locally with suitable surgical methods.

*Abdalla (1999)* stated that edematous skin disease was treated systemically by penicillin in a dose rate of 3 millions units for adult animals, given intramuscularly every 24 hours, for 4-5 successive days. Local application of 10% ichthiol ointment before surgical interference allowed fluctuation (pointing) of the lesion. Surgical interference included washing of the affected area with povidine-iodine, lancing and daily dressing with 5% tincture of iodine. *Kassem (1980)* noticed that prevalence of the oedematous skin disease was in buffaloes than in native cattle especially in summer season, and at Delta area more than Upper Egypt. Spread of the disease was influenced by the humidity, the temperature and the nature of the ground, however, its transmission was thought to be through a vector. Although it is mainly infectious in nature, yet, the skin lesions at their different phases need continuous surgical care.

*Zaghawa and El-Gharib (1996), Hamoda (1996), Al-Gaabary and Ammar (1999), Abu-Zaid (2001) and Amal (2002)* reported that the disease appeared in summer months from May to August where high temperature and humidity are relatively high. While *Moustafa (1984)* added that the disease appears all over the year but the number of the infected animals increased mainly in summer months.

*Ibrahim, Awad, Elbalkemy and Shaaban (1983)* found that the age of affected animals was eight months to six years. While *Nawal, Khalel, Seddek and Nashed (1995)* recorded that susceptible age between one to seven years.

*Zaghawa and El-Gharib (1996)* reported that cattle and buffaloes under two years were highly susceptible to oedematous skin disease than

those more than two years old. They contributed that the relative degree of resistance of old animals may be due to possessing protective antibodies from an infection acquired when young (acquired herd immunity). *Al-Gaabary and Ammar (1996)*, *Amal (2002)* and *Farghali (2007)* recorded the highest incidence of oedematous skin disease during summer months mainly in female buffaloes aged between six months to four years. *Ibrahim et al. (1983)* recorded that all affected animals were female buffaloes. While *Mostafa (1984)* noted that both sexes were susceptible to the disease but the most susceptible animals were females.

#### **6- External Hernia:**

Hernia is defined as the protrusion of the abdominal organs and localized beneath the intact skin.

It occurs mainly due to a congenital weakness of various physiological openings, and becomes apparent at birth or in the neonatal period. Under certain conditions of weakness or extreme stress, herniation of abdominal contents may also occur in adult farm animals (*Walker, 1966*).

Generally a hernial swelling is composed of covering tissues (skin and subcutaneous tissues), a peritoneal sac and any contained viscera. Particularly if the neck of the sac is narrow where it emerges from the abdomen, bowel protruding into the hernia may become obstructed or strangulated. A reducible hernia is that one in which the contents of sac return to the abdomen spontaneously or with manual pressure when the patient is recumbent. An irreducible hernia is that one whose content cannot be returned to the abdomen, usually because they are trapped by a narrow neck. The term incarceration means the inability of the hernial contents to return to the abdomen and does not imply obstruction, inflammation or ischaemia of the herniated organs though incarceration is necessary for obstruction or strangulation to occur (*Catcott and Smithcors, 1972; Heinze, Bullard and Johnson, 1972; Oehme and Prier, 1974 and Jennings, 1984*).

#### **6.1- Umbilical Hernia (Omphalocele):**

Umbilical hernias are seen most commonly in animals less than 6 months old and may be existed at birth (congenital umbilical hernias) due to developmental defects involving the umbilical opening (*Priester, Glass and Waggoner, 1970; Hayes, 1974; Bojrab and Toomy 1983 and Kraus, 1990*). Umbilical hernia may be also inherited with a genetic basis (*Angus and Young, 1972; Robinson, 1977 and Freeman and Spencer, 1991*).



Umbilical hernia is the most common type in cattle. It may be present at birth or develop during the first few weeks of life. The operation is easier in the heifer than in the bull. In the later the preputial orifice is adjacent to the operation, site. In fact, in some of larger hernias the ring may extend beneath the prepuce (*Kenawy and Kassem, 1992*).

*Venugoplan (1982)* recorded that the contents usually consist of omentum or intestines occurs in all domestic animals. It is more commonly in foals, pigs and calves. The predisposing cause usually congenital imperfect closure of the umbilicus and exciting causes as compression of the abdomen during birth, straining due to constipation or diarrhoea.

Umbilical hernia may develop after birth (acquired umbilical hernia) as a result of chronic infection of the umbilical cord (Omphalophlebitis) causing mechanical failure for natural closure of the umbilical opening or may result from excessive straining, traction of the umbilicus during birth and external trauma (*Oehme and Prier, 1974; Mckorwn, 1974; Aanes, 1980; Fretz, Hamilton, Barber and Freguson, 1983; Tulleners and Fretz, 1983; Hylton and Rousseaux, 1985 and Kaneps, 1992*).

*Misk, Youssef and Ali (1986)* mentioned that in the new- born animal, the opening of the navel is generally large and may sometimes give way to the pressure of the bowel on account of the weak and relaxed condition of the abdominal muscles. They concluded that this defective and abnormal condition of the umbilicus is frequently hereditary.

*El-Maghraby (1988)* recorded congenital umbilical hernia in 24 calves. While acquired ones were diagnosed in 84 calves. The umbilical hernia mostly occurs in male calves.

*Berge and Westhues (1984)* reported that, there are numerous methods of treating umbilical hernias. A clamp is placed on the hernial sac close to hernial ring. After about 2-3 weeks the clamp can be removed through the anterior end of skin wound. Ligation of the internal hernial sac can be used also after reduction of the hernial contents. If adhesions are present, it may become necessary to open the internal hernial sac. The intestinal loop is returned to the abdominal cavity and the internal sac inverted into the abdomen after being sutured with catgut. Then the hernial ring closed by means of u-suture.

*Fouad, Saleh and Shokry (1985)* discussed a method for treatment of umbilical hernia. General, epidural or local infiltration anesthesia may be applied. The animal is restrained in dorsal recumbency. An elliptical skin incision was made around the hernial sac. The dissection is then continued bluntly to separate the skin from peritoneum at the umbilicus, the portion of the skin over the hernial sac is discarded. The hernial content was reduced into the peritoneal cavity. If the bowel is incarcerated, the hernial sac should be carefully opened, the adhesions should be broken down, the bowel is returned to the abdominal cavity and the hernial ring is closed with horizontal mattress suture then subcutaneous tissue is closed with a continuous suture of chromic catgut. The skin is closed with horizontal mattress suture of silk or nylon. Finally antibiotics are administered for 5 days.

*Silva, Fioravanti, Eurides, Juliano, Acypreste, and Borges, (1999)* stated that umbilical hernia was treated by the conventional coat suture in 43 cattle and by a modified suture overlaying the conventional coat suture with the abdominal aponeurosis in another 43. Of the cattle treated with the former technique 11 relapsed while only three given the latter treatment relapsed. The latter technique was concluded to be more effective and easy to perform.

*Ozaydin, Kilic, Ozba, and Cihan (1999)* treated cases of umbilical hernia by applying a semi-circle like incision on the cranial part of the umbilicus. Following blunt dissection of the abdominal muscles, the abdominal cavity was reached. After treatment the lesions the abdominal muscles were sutured with silk by employing horizontal mattress or Halsted suture technique. Subcutaneous tissues were stitched with chromic catgut using the simple suture technique and the skin was closed with polyglactin - 910 using continuous intradermal suture techniques. Parental antibiotics were given to the animals for 5 days postoperatively. No complications were seen in animals during the subsequent controls

#### **6.2- Abdominal hernias (Ventral hernias):**

Ventral hernia is a term used to describe a hernia through any part of the abdominal wall other than the umbilicus or inguinal canal (*Tirgari, 1980*).

Ventral hernias may occur whenever the abdominal wall is severely traumatized. They are seen high or low in the flank, along the costal arch, or between the last two ribs. They also occur in the ventral abdomen near the

midline and higher in the iliac region of the farm animals.

Ventral hernia is an acquired type of hernia and the prognosis will depend upon many factors; size and location of the opening, thickness and firmness of the tissues forming the edge of the opening. The hernia usually caused by external violence, such as the impact of blunt objects such as kicks, blows, horn thrusts and falling objects, but may result from over stretching of the abdominal muscles by sudden unexpected effort or by violent straining during parturition (*Frank, 1964 and Mckeown, 1974*).

*Youssef (1984) and Gohar, Ramadan and Moghal (1987)* have demonstrated the preponderance of ventral hernias on the right side of the abdominal wall in cattle, sheep and goats.

In sheep, ventral hernias were found to occur on the right side twice as frequently as on the left. The direction of rupture was always along the direction of the fibers of the external oblique abdominal muscle. It usually commenced immediately behind the middle of the last rib and run obliquely downwards and backwards. Sometimes extends as far as the mammary gland (*Tirgari, 1980*).

*Bolbol and Ramadan (1992)* recorded a painless swelling located in the left ventrolateral aspect of abdominal wall in camel. It was diagnosed as post-caesarian hernia. Surgical procedures were successfully performed.

*Purohit, Chouan and Choudhary (1989)* revealed that the main cause of post-caesarian section hernias was either infection of the uterus or contamination of the surgical site leading to destruction of the suture material resulting in disruption of the muscle layers.

Incarceration, strangulation and adhesion are more likely to occur in ventral hernias (*Mansman and Mcallister, 1982*).

*Yavru, Alkan, Koc, Avki and Arican (1999)* concluded that skin autograft is superior to other hernioplasty materials due to elasticity, a viability from the animals, ease of application and low cost.

Mattress suture were described as a better method for closing the hernial ring in case of ventral hernias (*Loomis, 1967*).

*Shoukry, El-Keiey, Hanouda and Gadallah (1997)* concluded that the low cost commercial polyester fabric has excellent biocompatibility and offers a worthwhile alternative prosthesis for mesh herniorrhaphy.

### 6.3- Inguinal and scrotal hernias:

The term inguinal is used if the hernial contents descend through the inguinal ring into the inguinal canal. If the contents descend into the scrotum, the term scrotal hernia is appropriate (*Nieberle and Cohrs, 1966*). Thus all scrotal hernias were originally inguinal hernias and the vaginal ring forms the hernial orifice and the tunica vaginalis forms the hernial sac of inguinal hernia (*Jennings, 1984*).

Inguinal hernias may be classified as congenital or acquired; congenital hernias are generally apparent within the first few days of life (*Spurlock and Robertson, 1988; Van der Velden, 1988 and Livesey, 1990*): They also reported that congenital inguinal hernias associated with a rent in the common vaginal tunics.

Acquired inguinal hernia may be caused by breeding, abdominal trauma, strenuous work or any event that could increase intra-abdominal pressure (*Schneider, Milne and Kohn, 1982 and Hanson and Lindsay, 1992*).

Scrotal hernia would be considered in all stallions with signs of abdominal pain whereas palpation of a firm enlarged testicle is highly suggestive of a strangulated inguinal hernia (*Schneider et al., 1982*). The scrotum and internal inguinal ring should be evaluated in every stallion with signs of colic.

Inguinal hernias in new-born foals rarely become strangulated and usually disappear spontaneously within a few weeks. It was recommended the conservative management of congenital inguinal hernia in foals and consists of daily manual reduction of the hernia and observation to identify possible strangulation. Reducible non-strangulated hernias in foals often do not require surgical correction unless sudden enlargement of the scrotum or abdominal distress are supervene (*Jackson, 1972, Meagher 1974, Jennings 1984, Van der Velden 1988, Marlene 1988, and Spurlock and Robertson 1988*.)

Several methods have been described for immediate surgical reduction of inguinal hernias. Inguinal approach has been used for closure the internal

inguinal ring and removal of the testicle on the affected side because it is frequently oedematous due to compromised blood supply (*Frank, 1964; Wheat, 1975; Schneider et al. 1982; Van Der Velden, 1988; Livesey, 1990; and Hanson and Lindsay, 1992*).

If salvage of the testis is desired, a purse – string suture is placed around the tunica vaginalis as close to the vaginal ring as possible to reduce the diameter of tunica vaginalis while the caudal end of the external inguinal ring is left open to allow unobstructed passage of the spermatic cord (*Jennings, 1984 and Spurlock and Robertson, 1988*).

The incidence of abdominal hernias was higher in females and the incidence of inguinal hernia was higher in males. There was a positive correlation between the history of hernia and the degree of adhesion. The success rates of surgical treatment for all types of hernias were very high and there were no significant differences in the success rates among the different types of hernias in both sheep and goats regardless the types of suture materials used (*Al-sobayil and Ahmed, 2007*).

Subcutaneous herniation of the glandular tissue of the udder was observed in three goats. Soft swellings in the size of a lemon on the lateral aspect of the affected half were noticed. On digital pressure over the swelling, the contents were reduced through an opening into the parenchyma of the affected half. After surgical reduction of the herniated contents, no recurrence had been occurred (*El-Mezayen 1994*). That was attributed to focal disruption in the lateral sheet of the udder, which is an extension from the tunica flava of the abdominal wall.

#### **7- Oedema:**

Cutaneous oedema is a swelling on the surface of the body caused by increased diffusion of serous fluid into the tissue spaces of subcutis and secondarily of the dermis. It is recognized by the appearance of doughy swelling that pits on pressure with the finger-tips. Cutaneous oedema occurs either physiologically or pathologically (*Kelly, 1974*).

*Runnell, Monlux and Monlux (1976)* stated that oedema of the skin occurs when there is an increased amount of lymph in the connective tissues of the dermis and in subcutaneous tissue. It may be local or general. Local oedema occurs when a lymphatic obstruction to a local area of skin is present, in which the circulation becomes sluggish. General oedema of the

skin occurs when there is a general passive hyperemia or a hypoproteinemia. The oedema will be most pronounced in the skin of the ventral underlines, the legs, and in the skin ventral to the mandible.

Heifers were more susceptible to physiological oedema especially in late stage of pregnancy. It was characterized by a somewhat diffuse painless swelling extending cranial to the udder at the floor of the abdomen (*Stear and Moody and Nealy, 1960 and El-Sayad 1991*). They attributed the cause of udder oedema to poor circulation which resulted from pressure of fetus and fetal membranes because milkers have a tendency to leave the machines on the udder too long.

*Vestweber and Al-Ani (1984)* reported periparturient udder oedema, characterized by excessive accumulation of fluid in the interstitial spaces that showed pitting on digital pressure of the skin of the udder in goats but had received little scientific attention. The goat might be uncomfortable and difficult to milk. Differential diagnosis included mastitis, hard udder caused by caprine arthritis-encephalitis, hematoma and rupture of the prpubic tendon. Clinical signs of udder oedema appear as early as 7 days prepartum and persisted as long as 9 days postpartum. There were no significant difference in serum constituents between affected and control animals at the same stage of pregnancy or lactation.

*Roberts (1980)* mentioned that in pregnant cow the partuerant oedema may be noticeable until 2-4 weeks before parturition. It occurs mostly in high producing specially younger cows. The oedema may extend from the udder to the abdominal floor and be 2-6 inches deep.

The causes of edema in cattle varied between leaky capillaries, Blocked lymphatics, hypoalbuminurea and parasites (*Michell1996*). Treatment of edema in cattle involves management of specific causes and the use of diuretics which should be used with caution in pregnant animals. It has been suggested artificial colloids (plasma expanders) may alleviate udder edema.

Application of iodine ointment at the area of ventral abdominal swelling enhanced the absorption of physiological fluids of edematous swelling and reduced the duration of complete recovery (*El-Sayad 1991*).

Unusual out break of pathological udder edema was recorded by *Grant*

(1996) in a commercial ewe flock over the course of lambing. The udder was white in appearance, cold to touch and firm with pitiable edema. In almost all cases the teats were not affected.

Submandibular edema was observed in some cases of parasitic infestation and hypoproteinemia (*Kelly, 1974*) or with ascitis in few cases of fasciola infestation by (*Blood and Radostits, 1989*).

*El-Sayad (1991)* stated that donkeys were susceptible to the pathological edema at the ventral abdominal region and may extend to include the scrotum. The size of ventral abdominal and scrotal edema somewhat disappeared 3 days after surgical treatment, systemic antibiotic, diuretics and local treatment of skin injuries proved to be the satisfactory therapy for recovery. The main cause of pathological edema in buffaloes is traumatic pericarditis which is usually accompanied by a marked rise in body temperature, dyspnea and true jugular pulsation. At this stage there is no useful treatment. While in donkeys the causes is several skin injuries at the abdominal wall.

Scrotal edema was mentioned by *Angus and James (1993)* as a clinical appearance of orchitis in horses.

*Misk (1982)* reported edema as a complication of castration and scrotal ablation in ruminant.

Pendulous udder was diagnosed in goats. The affected udder was voluminous and showed multiple skin abrasions from continuous contact with the ground. Total mastectomy was also performed for these cases for breakdown of the supporting ligaments of large pendulous udder in cows and the same affected goats (*El-Mezayen, 1994 Greenough and Johnson, 1988*).

## **8- Prolapse:**

### **8.1- Rectal prolapse:**

It is an eversion of the caudal portion of the rectum through the anus. It is encountered in all domestic animal species. It can occur with any condition, that causing prolonged tenesmus such as, constipation, diarrhea, proctitis, intestinal parasitism, especially coccidiosis with mucosal ulceration, infectious enteritis, rectal foreign body, neoplasia, dystocia, urethral obstruction or colic, in ovines include also tail docking, fly strike, coughing due to dust and pneumonia, heavy concentration of pelvic fat. And use of growth promoting implants (*Frank 1964; Turner and Fessler 1980; Bially*

1984; Fouad, Saleh and Shokry, 1985)

The condition may be due to the results of a hereditary weakness of the sphincter ani or may be caused by the feeding of high concentrate rations or pelleted rations. Lambs on lush, legume pastures are affected (*Al-Ani, 1989*).

*Turner et al. (1980) and Kenawy (1988)* mentioned that conservative treatment of prolapsed rectum involved manual reduction, the use of purse string sutures to aid retention and epidural anesthesia to prevent further straining. And they performed amputation and suturing of the prolapsed part of the rectum in the cases of complete rectal prolapse with necrosis.

*Parish (1979)* reported that perirectal injection of counter-irritant appeared to be a rapid and economic method for the correction of rectal prolapse in lambs. A purse-string suture of umbilical tape is then placed to prevent immediate prolapse of the rectum. This suture is removed in five days. *Turner et al. (1980)* opened a case of 3-month old foal which had complete rectal prolapse. The prolapse was removed, using the modified submucosal resection. The anal sphincter was closed with a purse-string suture. While *Berge et al. (1984)* used two long strong silk threads which were introduced cross-wise through the prolapse, one ventricle and other horizontal, a finger breadth from the anus. The rectum is then cut off 1 cm behind the inserted threads. Sutures are used to hold together the serous surfaces of the two layers of rectum which will eventually adhere.

*Venugopalan (1982)* reported that reduction of the prolapsed rectum and measures to retain it are done if the case is a recent one and if there is not much damage to the prolapsed mass. Otherwise amputation is recommended by a series of haemostatic mattress sutures one passed around the prolapsed mass anterior to the proposed level of amputation.

Different forms and degrees of rectal prolapse were recorded as they were mucosal rectal prolapse or complete prolapse of the rectal wall with necrosis of its mucosa (*fouad et al., 1985*), habitual prolapse or prolapse of the rectum followed by tearing of the rectal tissues and protrusion of the omentum through it (*Frank 1864*), prolapse of the rectum in association with prolapse of the vagina (*Parish 1979*) and all previous forms were recorded by *Bolbol and El-Mezayen (1993)* who recorded all that form in 9 goats of 5 months to 4 years old. And they also mentioned that treatment of mucosal



prolapse of the rectum by purse string suture around the anus, leaving enough space for the introduction of a finger is usually sufficient and gives good results. In case of complete extensive prolapse of the rectum and\ or associated with necrosis of the prolapsed part, amputation of the rectum seems to give the best results.

#### **8.2- Vaginal Prolapse:**

Prolapse of the vagina is a condition of ruminants in late gestation. Occasionally it is seen after parturition and rarely it occurs unconnected with pregnancy or parturition. It's exact cause has not been ascertained but several factors are generally believed to play apart (*woodward and Queens berry, 1956*). Whatever the cause of prolapse of the vagina, parturition or abortion relieves the condition (*Mclean and Claxton, 1960*).

In both sheep and cattle vaginal prolapse is commoner in pluripara than primipara (*Edger, 1952*). Post parturient prolapse of the vagina of cattle is usually due to severe straining in response to vaginal trauma, or infection following a serious dystocia. Vaginal contusion at parturition, followed by fusiformis necrophorus infection exerts a high degree of irritation with frequent exhausting expulsive efforts (*Arthur, Noakes and Pearson, 1982*).

Numerous techniques have been described for both temporary and permanent repair of vaginal or cervical prolapse. This illustrates the fact that there is no "perfect procedure" instead we have several techniques that have advantages over the others for the specific prolapse presented. Most practitioner select a technique that they feel most comfortable with and employ it the vast majority of the time (*Youngquist and Threlfall, 2007*).

The Buhner technique is the most commonly used procedure because it can be easily and quickly performed and because of its retention strength. A disadvantage is that when used for the cow that is pregnant the suture must be removed prior to calving (*Wolfe and Baird, 1993*).

Regardless of which procedure is utilized for retention of the vagina proper restraint is important. Epidural anesthesia is always indicated and a pudendal block may be helpful when the bladder is also prolapsed (*Youngquist et al., 2007*). The aim of treatment is to arrest the process by early replacement



### Materials and methods

In the present study, localized swellings of the external body surface in different farm animals were recorded during the period between December 2005 and December 2007. The total number of affected animals was (1830) cases were recorded including (1036) cattle, (427) buffaloes, (128) Sheep, (48) goats, (81) horses, and (110) donkeys (Table, 1). These animals were of both sexes, variable body weight and their age ranged between few days up to 15 years old. Animal cases were collected from different localities in Kafr-El-Sheikh province in private clinics and some animal farms in addition to surgery clinic of faculty of veterinary medicine, Alexandria University.

**Table (1): Showing Species, Number and Sex of animals met with in this study.**

Species	Sex		Total
	Male	Female	
<b>Cattle</b>	<b>241</b>	<b>795</b>	<b>1036</b>
<b>Buffaloes</b>	<b>32</b>	<b>395</b>	<b>427</b>
<b>Sheep</b>	<b>22</b>	<b>106</b>	<b>128</b>
<b>Goats</b>	<b>5</b>	<b>43</b>	<b>48</b>
<b>Horses</b>	<b>71</b>	<b>10</b>	<b>81</b>
<b>Donkeys</b>	<b>65</b>	<b>45</b>	<b>110</b>
<b>Total</b>	<b>436</b>	<b>1394</b>	<b>1830</b>

#### Diagnosis of swellings:

A preliminary diagnosis was carried out based on history of the case and clinical examination. Detailed history of each case was obtained from the owner or the person being in close contact with the affected animal. Each animal was subjected to clinical examination for detecting body temperature, respiratory and pulse rate, color of the mucous membrane and rumen motility. Examination of the superficial lymph nodes was also carried out. Confirmatory diagnosis was performed in some cases such as umbilical abscess in foal using exploratory puncture (fig.1) or other diagnostic tools as histopathological examination. Specimens were collected for histopathological examination were managed according to *Bancroft and*

*Stevens (1996)*, the sample fixed in 10% neutral buffered formalin, dehydrated in alcohol, cleaned in xylol and embedded in paraffin. The blocks were cut at 6 micron thickness and the sections were stained with the suitable stain for histopathological examination.

***Drugs and Medicaments:***

Along the present study, varieties of antiseptic solutions were used (povidine iodine, hydrogen peroxide and pot. permanganate). Dressings and medicaments such as zinc oxide ointment, ichthyol ointment, iodine ointment, bin iodide of mercury blister, camphor ointment, cotton, gauze and adhesive plaster were also used according to the nature of the affection. Broad spectrum antibiotics, anti inflammatory and antitetanic serum were sometimes injected for treatment and/or prophylactic purposes. Fluid therapy, general tonics and antihistaminics were used in some cases (Table, 2).

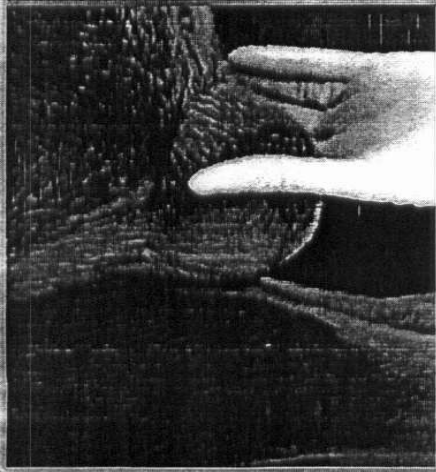
***Animal control and anesthesia:***

Animals were controlled for surgical operations by physical and/or chemical restraint. In ruminants, sedation was performed using xylazine Hcl (xylaject) given parentally in a dose rate of 0.1 mg./kg body weight. Light narcosis in equine was induced using 10 % chloral hydrate in a dose rate of 3-4 gm/50 kg body weight given by I.V. route. Local or regional analgesia using 2% lignocaine Hcl (debocaine) was performed according to the location of the lesion. Mostly, S/C infiltration around the base of the tumor was applied.


***Treatment of swellings:***

Medicinal and/or surgical treatment was conducted according to type of the lesion, considering its location and extension. Adhesion of the swelling into the deeper tissues or the covering skin was detected. The shape, size, number, color, and consistency of the swellings were considered. Varieties of external swellings were treated by suitable and available techniques. Protective bandage was applied following surgical excision in the lower part of the limb that was changed twice a week. Otherwise, when the bandage was difficult to apply, the wound was covered by adhesive plaster. Drains were inserted after treatment of cases with resultant gap (fig.2). Dressing was continued till healing achievement by the suitable intention. Local and/or systemic antibiotics, using long acting oxytetracycline one single shot at a dose rate of 1 mg/kg body weight was given intramuscularly in ruminants. In equine, 1,400,000 IU penicillin and 2 gm. streptomycin was given intramuscularly for three successive days. Single dose of prophylactic

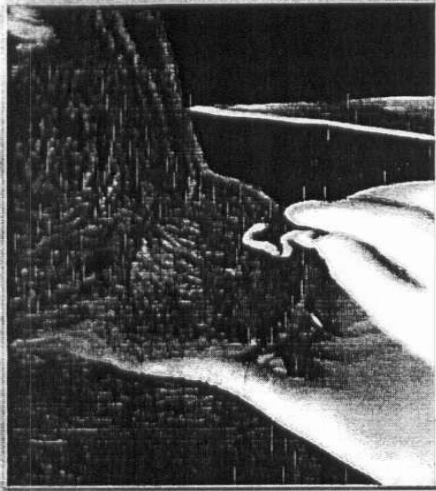
antitetanic serum (3000 I.U) was injected I.M., especially in equine.  
After 7-10 days, skin stitches were removed when applied.




Swelling palpation (1).



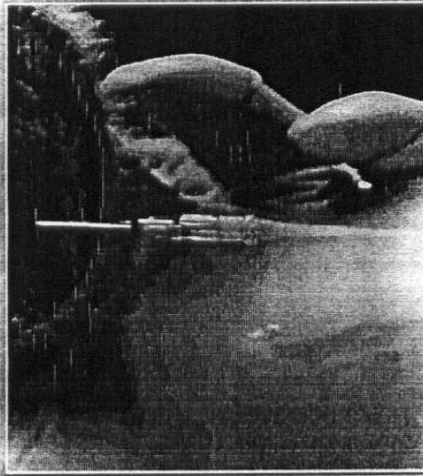Hair clipping (2).



Application of antiseptic (3).




Needle puncture (4).

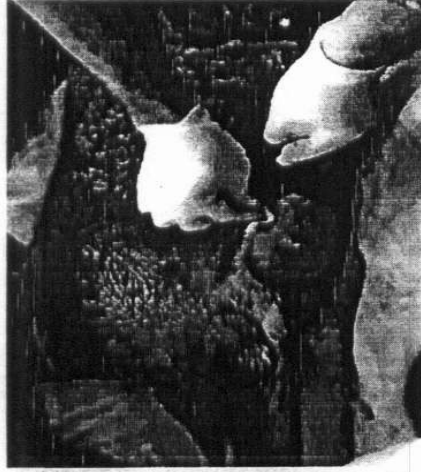

Needle drains pus (5).

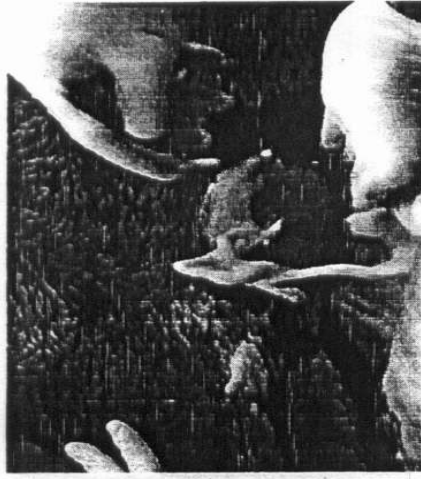Fig. (1): Showing Pre-operative considerations for aseptic puncture necessary for accurate diagnosis of a hot abscess in a foal. palpation (1), hair clipping using scissors (2), touching with tincture of iodine (3), needle insertion (4), and finally pus drains from the needle (5) confirm the swelling as mature hot (acute) abscess.




Abscess preparation (1)  
(clipping & shaving before incision).



Abscess preparation (2)  
(using antiseptic).



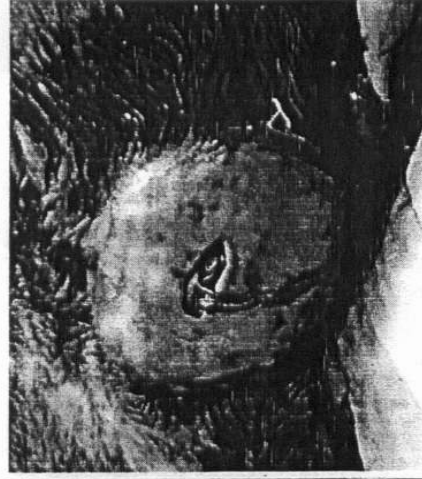Abscess evacuation (3)  
(by pencil grip incision)



Cavity examination (4)  
(orientation after incision)



Insertion of drain (5)  
(inside the abscess cavity)



Abscess cavity (6)  
(completely filled with drain)

Fig. (2): Showing surgical approach for manipulation a case of hot (acute) abscess in a foal; from preparation of the swelling before incision till insertion of drain (1 to 6).

Table (2): Showing sources and data of drugs and medicaments used in the present study

Scientific name	Commercial name	Form and application	Dose	Company
Povidine iodine	Betadine	Aqueous/locally	-	El-Nile
Hydrogen peroxide	Hydrogen peroxide	Aqueous/locally	-	Luna
Potassium permanganate	Potassium permanganate	Crystal / locally	-	El-Gomhoria
Xylazine Hcl	Xylaject	Aqueous/I.M&I.V.	0.1 mg / kg	ADWIA
Chloral hydrate	Chloral hydrate	Powder/10% I.V.	3-4 gm / 50kg	Chemical factory Co.Ltd.
Lidocaine Hcl 2%	Debocaine	Aqueous / ocaly	-	El-Debaiky
Oxytetracycline	Terramycine L.A.	Oily/I.M.	1 ml / 10 kg	Pfizer
Streptomycine and pencilline G. sod.	Streptopencid	Powder/I.M.	2gm and 1.400.000 IU	CID
Phenyl butazone & Sod. salicylate	Arthridine	Oily / I.M.	1 ml / 10 kg	Verbac
Ucimisol	Levamisol	Aqueous/S.C.	1 ml / 10 kg	Kirovest
Nitroxinil 25%	Fasciolid	Aqueous/S.C.	1 ml / 25 kg	Aventis
Furosemide	Lasix	Aqueous / I.V & I.M.	Amp. / 100 kg	
Ivermectine and clorosolone	Ivomec super	Oily solution for S/C	1 ml / 50 kg.	
Flunixin meglumine	Finadyne	Aqueous sol. For I.M	1 ml / 50 kg	Schering plough
Iodine ointment		Oint. topical	-	-
Ichthyol ointment		Oint. topical	-	-
Silk		-	-	Davis and Geck
Catgut		-	-	Suture Ltd. UK
Antititanic serum	Tetanus antitoxin	Ampoules. S/C	3000 IU	Egyptian org.



## *Results*

Nine types of external swellings were recorded in different farm animals including external neoplasms (135 cases), abscesses (408 cases), bursitis (138 cases), cysts (30 cases), the swellings due to oedematous skin disease (99 cases) and lumpy skin disease (561 cases), hernia (237 cases), localized oedema (87 cases), and prolapse (135 cases). Table (3)

### *External neoplasms:*

Among the present study, external neoplasms were recorded in (135) cases, representing 7.4 % of the total external swellings in different animal species. These cases were recorded in cattle (63 cases), in buffaloes (33 cases), in donkeys (15 cases), in horses (9 cases), in sheep (9 cases) and in goats (6 cases) (Table, 3). Neoplasms were prevalent in cattle (63 cases) representing 46.6 % of all cases. Neoplasms recorded in this study affected commonly female animals especially in cattle, buffaloes, sheep and goats. While in donkeys and horses they affected both sexes in nearly equal ratio (Table, 4). One hundred and two cases of the recorded external neoplasms affected animals aging more than 2 years old, while, thirty three cases were in animals aging less than 2 years old (Table, 5).

External neoplasms with variable forms were detected anywhere of the body surface including head, shoulder, limbs, chest and abdomen and tail (Fig., 3). Head and neck were the most common sites affected with neoplasms (78 cases representing 58.5 % of the total number), as the tail was the lowest (8 cases) (Table, 6).

Papillomas were the most common type of external neoplasms representing (71.9 %). They appeared as multiple cauliflower swellings, sessile, hard, firm with horny projections. The affected animals were infested with ticks. In two cases, lesions were hemorrhagic and inflamed as a result of traumatic injuries. Fibroma represented 17.8 % of the total neoplasms, and incidence was higher in donkeys (10 cases) and horses (8 cases) Table (7). The growth developed gradually and appeared firm, painless, and movable.

Squamous cell carcinoma represented 10.30% and were recorded more in eyes of cattle (5 cases) and respond favourably to extirpation of eye ball (Fig., 4). Healing was achieved within one month by mixed intention.

Ligation of small sized neoplasms of clear neck allowed their sloughing within two weeks leaving minute scar, healed by second intention within one week. Healing by first intention was achieved in small sized cases after 10 days without complications. Healing by first intention of medium sized cases was achieved after 11-14 days from suturing (Fig., 5).

Two cases in horses were complicated by developing of hypergranulation tissues in lower limb (fetlock region). Hemorrhage and lack of skin had developed following excision of large neoplasms. Thermocautery was effective, as it ensured hemostasis, where appositioning of these tissues by suturing was impossible. Healing of such wounds occurred successfully within 30 days following dressing.

Histopathological examination revealed huge amount of collagen bundles arranged in whorls with the presence of large number of fibroblasts indicating skin fibroma (Fig., 6, A & B). Meanwhile, the clumps of fibrous tissue formed mainly from neoplastic fibroblast with different shapes and collagen fiber with blue color are indicative for skin fibrosarcoma (Fig., 7). Increase in both the stratum spinosum (acanthosis) and stratum corneum (hyperkeratosis) proved cases of skin squamous cell papilloma (Fig., 8, A & B). Neoplastic oval cells present in irregular cords and spread in the deep layer of the dermis are basal cell carcinoma (Fig., 9).

***Abscesses:***

In the present study (408) cases of abscesses in different farm animals were recorded resembling 22.3% of the total percentage of external swellings. Cattle were the highest species in which abscess incidence (183 cases) representing 45 % of all cases (Table, 3). Abscesses were encountered in several body regions (Fig., 10). Head and neck regions proved the most common affected regions in all farm animals (161 cases). Umbilical abscesses were recorded in newly born calves, buffalo calves, sheep and goats (55, 15, 9 and 2, respectively) and not recorded in the present study in donkey or horses (Table, 8). Three cows aging 6-7 years old were recorded to be infected by umbilical abscesses that ended by umbilical hernia after 6 months to one year.

On incision, the pus color varied between creamy, yellowish and watery with variable consistency and variable amount. The hind quarter and thigh were predilection sites for abscess formation in goats, cattle and buffaloes. Daily dressing gave good recovery within two weeks. The area of

the left elbow was subjected to abscesses formation. Two cases were detected in cattle in last stage of pregnancy. Treatment was possible and curing was achieved after removing of the foreign body associated with daily dressing. Healing occurred within 3 weeks. Limbs (fore and hind) were subjected to infections and abscess formation, especially in cattle infected with lumpy skin disease.

Four donkeys were suffering from abscess formation in the fore limb. Abscesses in the sternal region were recorded in this study in 2 donkeys and one horse. Abscesses in wither region were recorded in donkeys.

In the present study, subcutaneous udder abscess was recorded in 20 cattle, 4 buffaloes, 6 sheep and 8 goats, especially after chronic mastitis. Routine daily dressing for 20–30 days gave a good results and complete healing by second intention was achieved.

Ventral abdominal abscesses were recorded in 4 cows (2 of which ended by abdominal hernia), 7 cases in goats, 15 cases in sheep, especially after shearing and one case in ventral abdominal region of a horse. Abscesses were recorded at different ages between 1 month and 7 years old. Acute abscesses appeared as painfull soft swellings containing pus and chronic abscesses appeared as cold, painless and hard swellings.

#### ***Bursitis:***

Three types of bursitis were met with in this study; chronic olecranon bursitis in buffaloes and horses, chronic presternal bursitis in buffaloes and supra spinous bursitis in donkeys (Fig., 11 A). Incidence of olecranon and presternal bursitis proved higher than supraspinous ones (70 and 61 cases versus 7 cases) (Table, 9).

Presternal bursitis was examined carefully in large animals to be differentiated from sternal edema and traumatic pericarditis (Fig., 11 B). Presternal bursitis were recorded in 50 buffalo calves aging 2-6 months, started as fluctuating swelling at the presternal area. The size of burse ranged from the size of an orange to the size of head of children. Exploratory puncture revealed a serous yellow fluid. 5 cases of presternal bursitis were recorded in cattle of 4-6 years old and 6 cases were recorded in buffaloes aging 5-7 years old. Seven cases of supra spinous bursitis were observed in donkeys. Acute cases of olecranon bursitis characterized by hot, painful inflammatory swelling, especially during movement of the elbow joint in large sized cases. Meanwhile, chronic cases characterized by absence of

pain. Size of the affected bursa ranged from tennis ball to man's head size. The consistency varied from watery to thick.

Cases of acute bursitis respond to aspiration of its content under complete aseptic condition and injection of 100 mg hydrocortisone and crystalline penicillin every week for 2-3 injections.

Very large sized bursa, especially presternal ones respond to lancing of the bursa at the most lower point for rapid evacuation and daily dressing allowed healing within two weeks (Fig., 12). Local application of 10 % iodine ointment allowed absorption of the fluids in the cavity of the bursa (Fig., 13).

One case of cystic olecranon bursitis was complicated by septic infection and the treatment was completed successfully as for abscess. Another one was fibroused and radical treatment was effective by total excision and wound closure healed within two weeks.

*Cysts:*

Cutaneous cysts were recorded in 30 animals including cattle, buffaloes and horses. Cysts were typed as branchial cysts (12 in cattle and 4 in buffaloes), and other cysts classified as meningocele in newly born calves (5 cases), ectazia of parotid duct in calves (6 cases) and subcutaneous cysts in horses (3 cases) (Table, 10).

Branchial cysts were diagnosed in cattle and in buffaloes. Clinical examination revealed existence of unilateral and bilateral soft, fluctuating, painless, non inflammatory swellings present subcutaneously. Eleven cases were easily movable and located at the ventrolateral aspect of the left side of the upper third of the neck.

The other five cases were little movable and more attached to the surrounding tissues and located below the level of the ear, extending down to the distal part of the lower jaw.

Six cases were located right to the midline of the neck, Seven cases were left and 3 cases were bilateral. Puncturing of the cyst discharged milky to grayish secretion. Surgical excision of the branchial cysts was the radical treatment and necessitated careful blunt dissection to separate the cyst from the surrounding vital structures. Healing was obtained by first intention without recurrency.

Cases of meningocele (Fig., 14 A) responded favorably to surgical excision

after aspiration. One case died in the third day with unknown cause and another died one week later due to infection. Ectasia of parotid duct (Fig., 14 B) responded to treatment by creation of a permanent intra oral fistula and the wound in the skin healed by first intention after freshening within 12 days. Cysts in the chest of horses had easily excised (Fig., 15) and subcut and skin healed rapidly by first intention within 10 days.

***Swellings due to infectious causes:***

***Lumpy skin disease:***

In the present study, the disease was seen only in cattle (native and imported breeds). About one thousand of cattle was met with suffering from lumpy skin disease characterized by dermatitis with circumscribed large numbers of cutaneous nodules which are uniform in size and situated all over the body especially abdomen, thorax and neck. Only 561 cases suffering from swellings required surgical interference (Fig., 16).

The cases characterized by edema of the legs, dewlap and brisket, swelling of the superficial lymph node and areas of phlegmone and localized abscesses. Exploratory puncture was helpful as a guide for surgical interference. Counter openings were necessary in lower parts of the lesions in 75 % of cases of the limbs. The response to surgical treatment varied according to nature and location of lesions. Healing by second intention was achieved between two weeks to two months after daily dressing with H<sub>2</sub>O<sub>2</sub> and tincture iodine.

***Oedematous skin disease (O.S.D):***

In the present study, the disease was recorded only in buffaloes (99 cases) during summer months. Buffalo cows were commonly infected (88 cases) rather male buffaloes (11 cases). The disease was common in buffaloes above 2 years old (86 cases) rather those below two years (13 cases) (Table, 11).

The disease characterized by painful, localized and diffused oedematous swellings on limbs, breast, dewlap and abdomen. Medical treatment using penicillin/streptomycin and NSAID as Flunixin meglumine in a dose rate 1ml/50 Kg B.W. alone failed to give good results. Meanwhile, surgical interference gave good and acceptable results (Fig., 19) following using of ichthyol ointment for maturation and localization of the swellings.

Injection of antiparasitic (ivermectin) proved effective in three longstanding cases. Local dressing following surgical incision and evacuation was also helpful and healing achieved in all cases within 12-30

days. Neglected cases were met with characterized by chronic abscess formation and respond favorably to evacuation and dressing (Fig., 20).

***Hernias:***

In the present study, 237 cases of hernia were recorded in different domestic animals including; 99 umbilical hernia, 54 lateral abdominal, 42 ventral abdominal and 42 scrotal hernia (Table, 12). There was a correlation between the sex, age and type of hernias (Table, 13). 189 cases representing 79.7% of total hernias were found to have no adhesions. 24 cases suffered from loosely adhesions. The remained 24 cases showed severe adhesions between the different layers of hernial sac, especially in the old cases.

Ninty cases representing 90.9 % of Umbilical hernia were recorded in newly born calves (around four months), and 10% were recorded in adult animals. Hernial ring measured between one finger to more than 20 centimeters according to time of incidence, causative agent, location and species. One hundred sixty and five cases representing 69.6 % were reducible, circumscribed, painless and doughy swelling. 3 cases of umbilical hernia were accompanied by umbilical abscesses.

Opening reduction and closure of the hernial ring were proved to be the accurate procedures for treatment of the different cases of hernia (Fig., 19). Healing was obtained 10-14 days post operation. The V- shaped skin incision technique for open reduction proved successful and ensured better exposure of umbilical hernia in males. Healing was achieved 10 days after surgery. No complications were observed. Silk proved advantageous to chromic catgut for closure of hernial ring in various species.

Lateral abdominal hernia was recorded in 54 cases including; 24 cases in cattle, 15 cases in sheep, 9 cases in horses and 6 in donkeys. All cases of lateral abdominal hernia were recorded in right side in ruminants. Ventral abdominal hernia was found in various sites of the ventral abdominal aspects according to species, age and sex. In cattle, it was found close to lower part of costal arch and cranial to udder in cows, sheep and goats and in horse the abdominal hernia were located between the umbilicus and the base of the scrotum (Fig., 20).

Surgical correction by open reduction was successful in all cases and healing was obtained 2 weeks post operation. Re-occurrence was observed in two cows about one month post operation.

The forty two cases of scrotal hernia were distributed as 6 cases in rams, 21 in stallions and 15 in donkeys. 37 cases of scrotal hernia were unilateral and 5 were bilateral (Fig., 21). 25 cases of unilateral hernias were observed in right scrotal sac. Surgical exploration was considered as a confirmatory diagnostic tool and reduction was then carried out. Loop of small intestine was the hernial content in all cases (Fig., 22). All cases of scrotal hernias were old cases characterized by presence of adhesions between tunica vaginalis and hernial content. Testes in 21 cases were atrophied. Castration of the involved testis was performed following opening of the tunica vaginalis.

***Oedema:***

Localized oedema was recorded in 87 animals (Fig., 23) including 21 buffaloes, 46 cattle, 8 horses, 7 donkeys and 5 sheep (Table, 14). Pathological edema characterized by edematous swellings in the chest and sternal region associated with disturbance of general health condition were found to be due to traumatic pericarditis and slaughtering was the only solution. Recent aseptic cases of edema in sheep, horses and donkeys respond within one week to medical treatment using hot fomentation, diuretics and local application of iodine ointment. Meanwhile, old septic cases associated with injuries required surgical management of the associated injuries after freshening and their response varied according to the nature of lesion. Healing by first intention was achieved within 15 days.

***Prolapse:***

In the present study, prolapse was encountered in (Table 15) 135 animals including, 52 cases of vaginal prolapse (Fig., 24), 18 cases of rectal prolapse (Figs., 25 & 26) and 62 cases of uterine prolapse. Cases of rectal prolapse were recorded in donkeys (15 cases), especially young ones aging from 1 to 6 months, and calves (3 cases) around 9 months age. Partial or mucosal prolapse was seen as a reddish spherical swelling protruded at the anus with transverse folds. Treatment was effective and manual reduction was easily performed following washing of prolapsed part with antiseptic solution and lubrication with medical Vaseline. Complete prolapse of the rectum was recorded in 11 donkeys. All cases were recent and respond to manual reduction and fixation by a purse string suture around anal opening.

Vaginal prolapse was encountered in the present study in 52 animals; 6 donkeys, 25 buffaloes (15 of which were heavy pregnant, 7 were detected within one week post partum and 3 were non pregnant) and 15 cows (10

heavy pregnant, 3 post partum and 2 non pregnant). Induction of posterior epidural analgesia, washing of the prolapsed part by antiseptic solution and lubrication with Vaseline was helpful for reduction and fixation by a long single mattress stitch around vulvar opening.

In severe cases with edematous and inflamed tissues, especially in buffaloes, tannic acid was applied allowing minimizing the size of the prolapse, facilitating its reduction. Recurrence did not occur except in one case (pregnant buffalo, one week before parturition) and required observation till birth.

Uterine prolapse was observed in 65 animals; 17 buffaloes, 33 cattle and 15 sheep. It was noticed that 13 cases of buffaloes and 22 cases of cows were suffering from vaginal prolapse prior to uterine prolapse. Manual reduction and fixation was performed successfully without complication.

**Miscellaneous cases:**

Four cases of unclassified external swellings were recorded. The first case was heavy pregnant cow suffering from chronic incurable mastitis with enlarged udder. Exploration revealed presence of loop of intestine prolapsed inside the udder tissues and diagnosed as udder hernia (Fig., 27). Animal slaughtering was the only recommended request.

The second case was a newly born calf aging few hours old with soft rosey red swelling hanged in umbilical region. Clinical examination revealed the case as epitheliogenesis imperfecta and prolapse of the intestine the calf respond to surgical treatment by reduction after preparation for aseptic surgery, especially when the peritoneum was found intact enclosing the intestinal loop (Fig., 28). Healing achieved successfully within 8 days.

A six months old calf with umbilical swelling was met with and suspected for first time as an umbilical hernia. Examination revealed absence of hernial ring and inflammatory signs. Surgical incision of skin as for umbilical hernia and excision of the localized swelling intact was successfully performed. Subcutaneous tissues and skin were sutured easily. Incision of the excised swelling revealed the condition as old caseated abscess (Fig., 29). Good healing was achieved after 9 days.

The last case was one year old ram with swollen testis subjected to diagnosis



by surgical exploration that revealed the condition as bilateral septic degenerative orchitis. Treatment was successful by total aseptic castration (Fig., 30). Healing by first intention was obtained before 10 days of operation.

Table (3): Showing number of cases and different affections recorded in the study under investigation

Species	Cattle		Buffaloes		Horses		Donkey		Sheep		Goat		Total	
	No.	%	No.	%	No.	%	No.	%	No.	%	No.	%	No.	%
Swellings	63	46.7	33	24.5	9	6.7	15	11	9	6.7	6	4.4	135	7.4
Neoplasms	183	44.8	72	17.7	21	5.1	36	8.8	60	14.8	36	8.8	408	22.
Abscesses	5	3.6	125	90.6	1	0.8	7	5	-	-	-	-	138	7.5
Bursitis	19	63	8	27	3	10	-	-	-	-	-	-	30	1.6
Cysts	-	-	99	100	-	-	-	-	-	-	-	-	99	5.4
O.S.D	561	100	-	-	-	-	-	-	-	-	-	-	561	30.7
L.S.D	108	46	27	11.4	39	16.5	21	9	36	15	6	2.5	237	13
Hemias	46	53	21	24	8	9	7	8	5	6	-	-	87	5
Oedema	51	38	42	31	-	-	24	18	18	13	-	-	135	7.4
Prolapse	1036		427		81		110		128		48		1830	100

Table (4): Showing distribution of neoplasms in different animals with regard to their sex.

Sex and Species	Cattle	Buffaloes	Sheep	Goat	Donkeys	Horses	Total
Male	10	9	2	2	8	5	36
Female	53	24	7	4	7	4	99
Total	63	33	9	6	15	9	135

Table (5): Showing distribution of neoplasms in different animals with regard to their age

Age	Cattle	Buffaloes	Sheep	Goat	Horse	Donkeys	Total	%
< 2 years	14	8	3	2	2	4	33	24.5
> 2 years	49	25	6	4	7	11	102	75.5

Table (6): Showing neoplasms in different animals with regard to their body regions.

Site of neoplasms in different species	Cattle	Buffaloes	Donkeys	Horse	Sheep	Goats	Total
Head and neck	38	20	8	4	5	3	78
Limbs	13	7	4	2	3	2	31
Chest and abdomen	8	4	2	2	1	1	18
Tail	4	2	1	1	-	-	8
Total	63	33	15	9	9	6	135

Table (7): Showing types of neoplasms in different farm animals.

Species	Cattle	Buffaloes	Horses	Donkeys	Sheep	Goats	Total	
							No.	%
Neoplasm								
Papillomas	54	27	1	3	7	5	96	71.90
Fibromas	4	2	8	10	-	-	25	17.80
Squamous cell carcinomas	5	4	-	2	2	1	14	10.30
Total	63	33	9	15	9	6	135	100

Table (8): Showing abscesses distribution in different animals with regard to their body regions.

Species	Cattle	Buffaloes	Sheep	Goats	Donkeys	Horses	Total
Body region							
Head and neck	69	34	23	13	14	8	161
Umbilical	55	15	9	2	-	-	81
Abdomen and chest	12	6	15	7	12	7	59
Limbs	27	13	7	6	10	6	69
Udder	20	4	6	8	-	-	38
Total	183	72	60	36	36	21	408

Table (9): Showing types of bursitis in the present study

Affection/species	buffaloes	buffalo	cattle	horse	donkeys	Total	
						No.	%
Capped elbow	69	-	-	1	-	70	50.7
Prestermal bursitis	56	5	5	-	-	61	44.2
Supra-spinous	-	-	-	-	7	7	5.1
Total	125	5	5	1	7	138	100

Table (10): Showing types of cysts among the present study

Species \ cyst	buffaloes	Cattle	Horses	Total	
				No.	%
Branchial cyst	4	12	0	16	53
Other cysts	4	7	3	14	47
Total	8	19	3	30	100

Table (11): Showing number of cases of edematous skin disease with regard to animal's age and sex

Age (years)	Below 2 years	Above 2 years	male	females	total
Number of cases	13	86	11	88	99
%	13%	87%	11%	89%	100%

Table (12): Showing types of hernia in different animals in the present study

Species	Type	Umbilical	Abdominal		Scrotal	Total
			Lateral	ventral		
Cattle		63	24	21	-	108
Buffaloes		27	-	-	-	27
Sheep		6	15	9	6	36
Goats		-	-	6	-	6
Horses		3	9	6	21	39
Donkeys		-	6	-	15	21
Total		99	54	42	42	237

Table (13): Showing types of hernia with regard to animal's sex and age

Type	Sex	Male		Female		Total
		young	adult	young	adult	
umbilical		40	-	50	9	99
abdominal		24	10	55	7	96
Scrotal		-	42	-	-	42

Table (14): Showing different types of edema in the present study

Type	buffaloes	cattle	Sheep	donkeys	horses	Total
physiological	15	25	2	-	3	45
pathological	6	21	3	7	5	42
Total	21	46	5	7	8	87

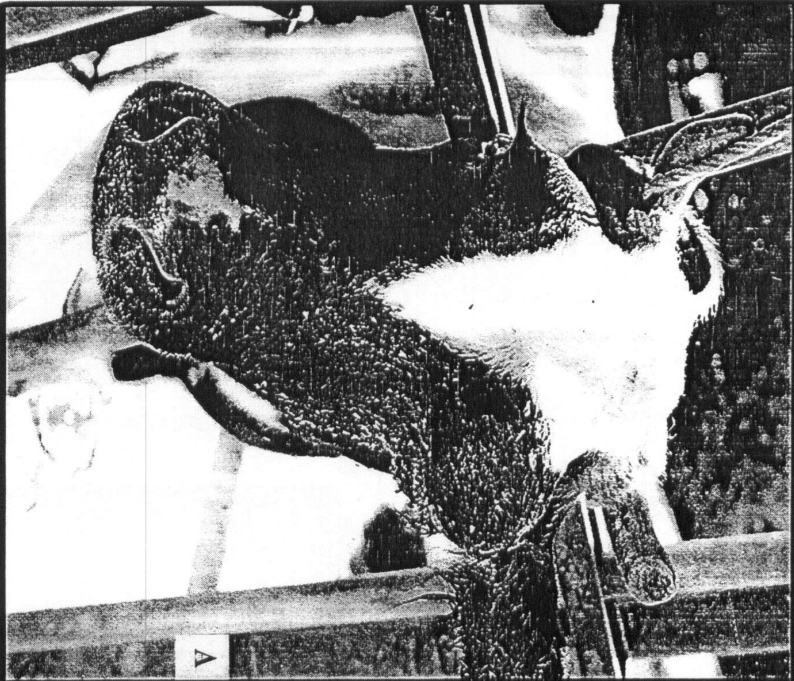
Table (15): Showing different types of prolapse in the present study

Prolapse \ species	cattle	buffaloe	sheep	goats	donkeys	Total
Rectal prolapse	3	-	-	-	15	18
Vaginal prolapse	15	25	6	-	6	52
Uterine prolapse	33	17	12	-	3	65
Total	51	42	18	-	24	135

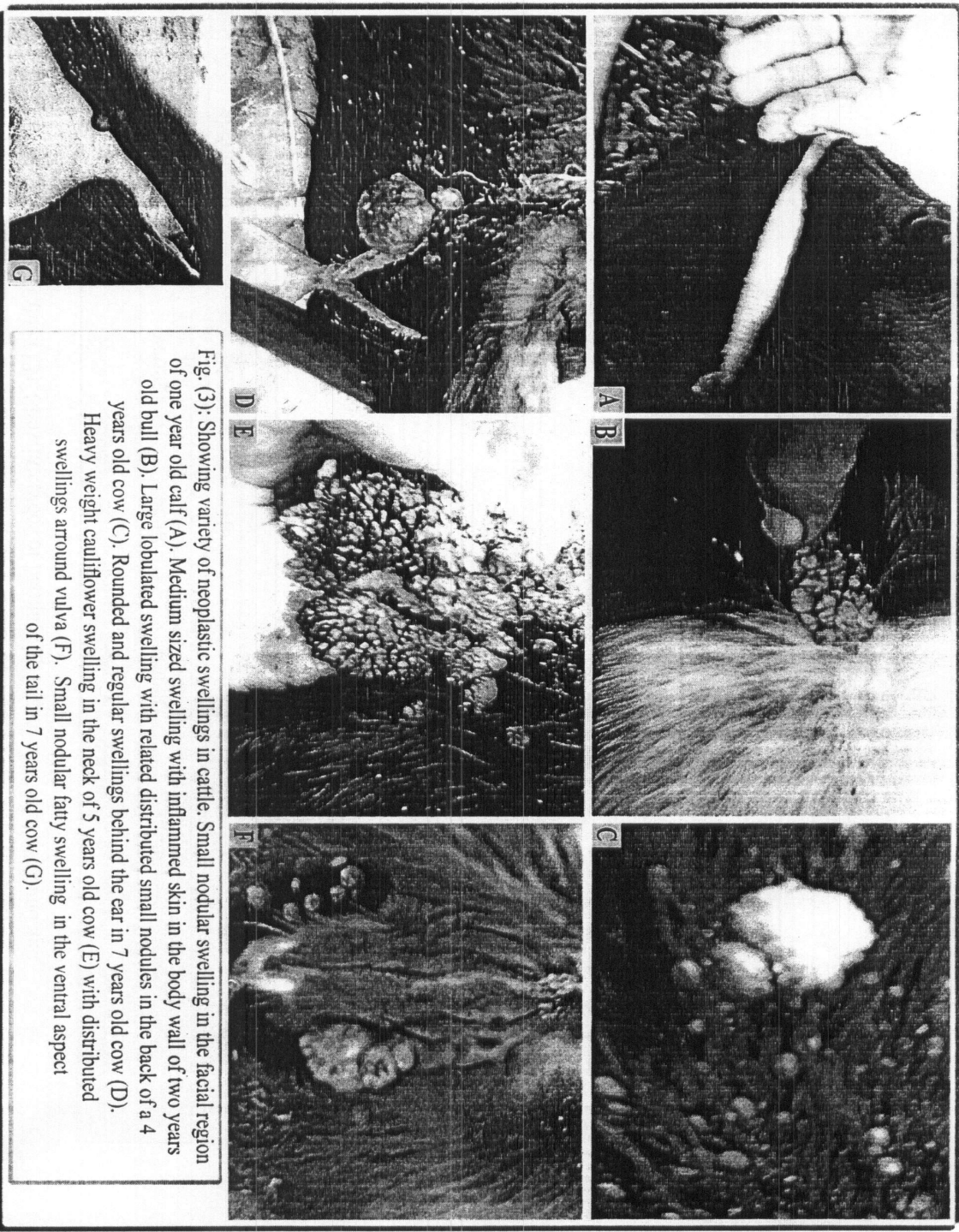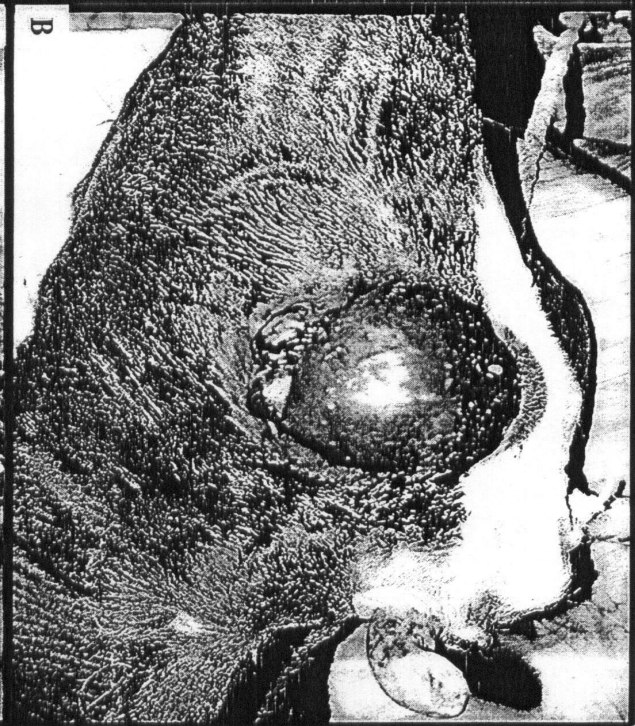


Fig. (3): Showing variety of neoplastic swellings in cattle. Small nodular swelling in the facial region of one year old calf (A). Medium sized swelling with inflamed skin in the body wall of two years old bull (B). Large lobulated swelling with related distributed small nodules in the back of a 4 years old cow (C). Rounded and regular swellings behind the ear in 7 years old cow (D). Heavy weight cauliflower swelling in the neck of 5 years old cow (E) with distributed swellings around vulva (F). Small nodular fatty swelling in the ventral aspect of the tail in 7 years old cow (G).

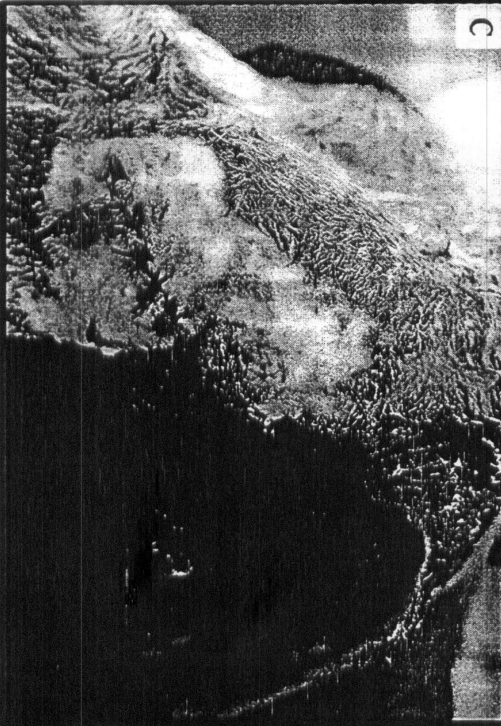




A



B



C

Fig. (4): Showing left ocular swelling in 7 years old cow (A). The swelling is fibrous and the eye ball is displayed to inside (B). Extirpation of the eye ball was the only suitable treatment of such case (C).

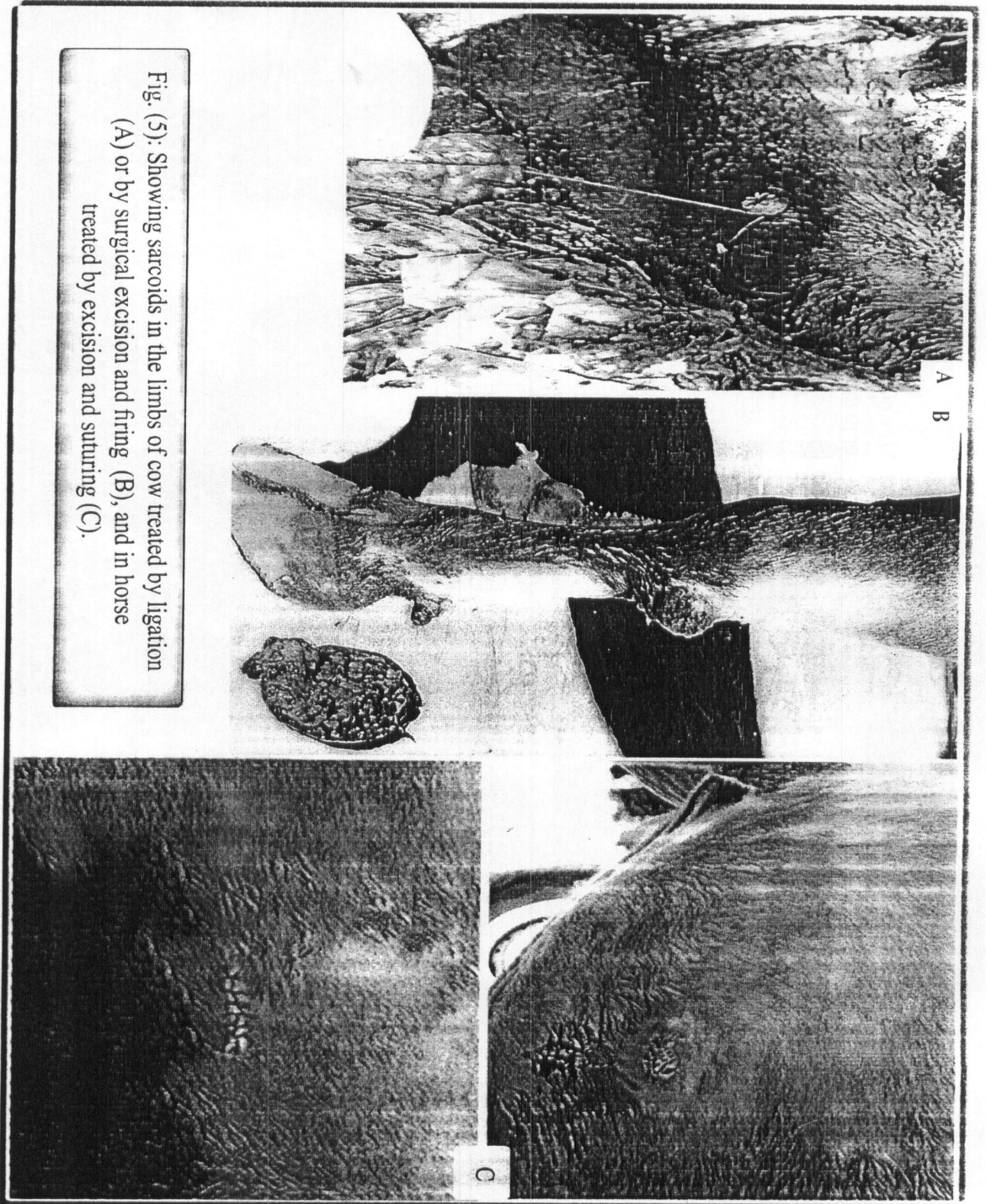


Fig. (5): Showing sarcoids in the limbs of cow treated by ligation (A) or by surgical excision and firing (B), and in horse treated by excision and suturing (C).

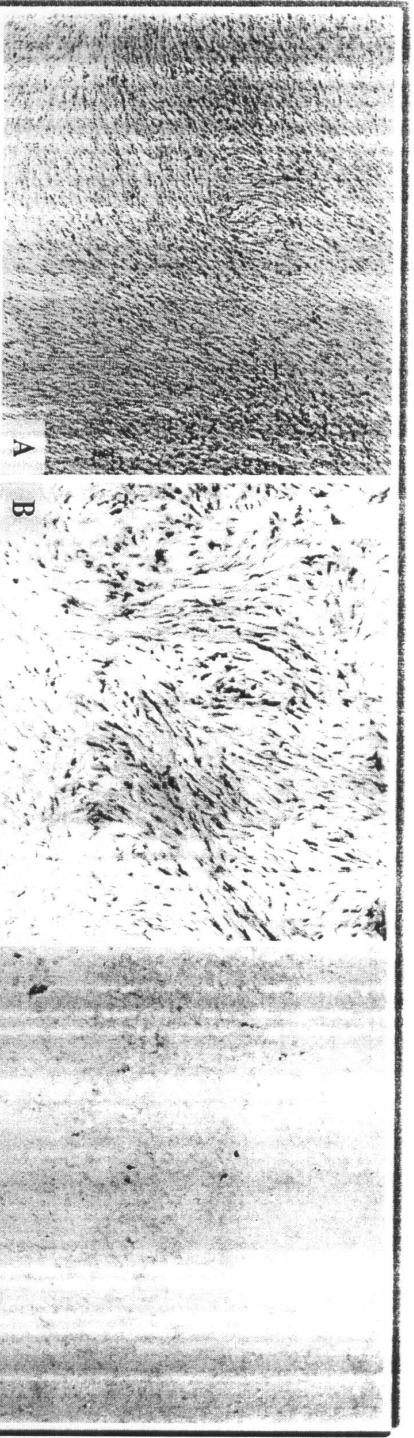


Fig. (6): Showing hard fibroma in skin characterized by huge amount of collagen bundles arranged in whorls with presence of large number of fibroplasts (A, H&E, 100 and B, Trichrom, 100).

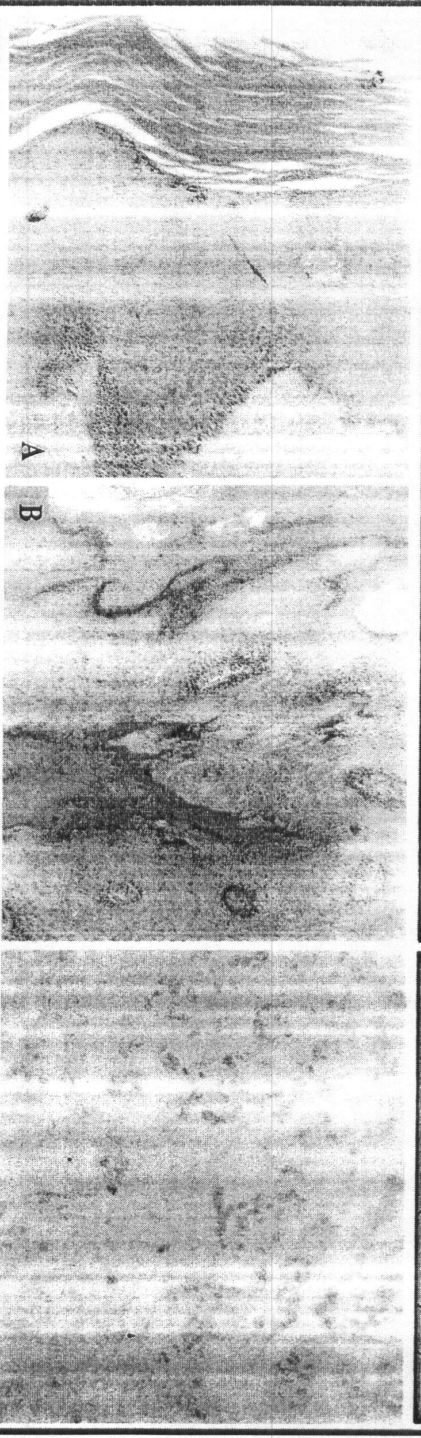


Fig. (8): Showing skin squamous cell papilloma, characterized by increase in both stratum spinosum (Acanthosis) and stratum corneum (hyperkeratosis) (H&E, 200, A). The dermal papillae invade the dermis (H&E, 100, B).




Fig. (7): Showing skin fibrosarcoma c.c.c. by clumps of fibrous tissue formed from neoplastic fibroblast with different shapes and collagen fiber with blue color (Trichrom, 100).

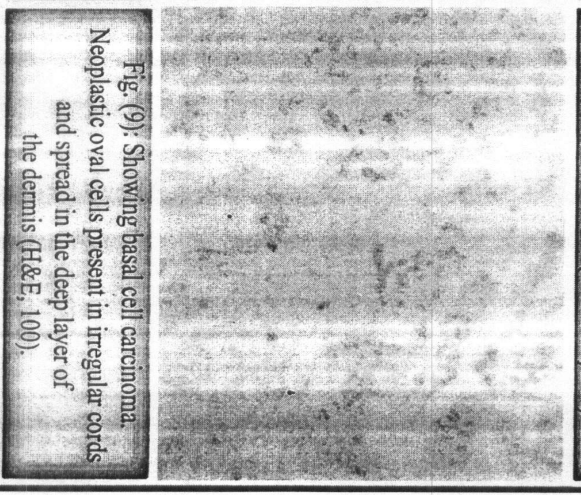


Fig. (9): Showing basal cell carcinoma. Neoplastic oval cells present in irregular cords and spread in the deep layer of the dermis (H&E, 100).

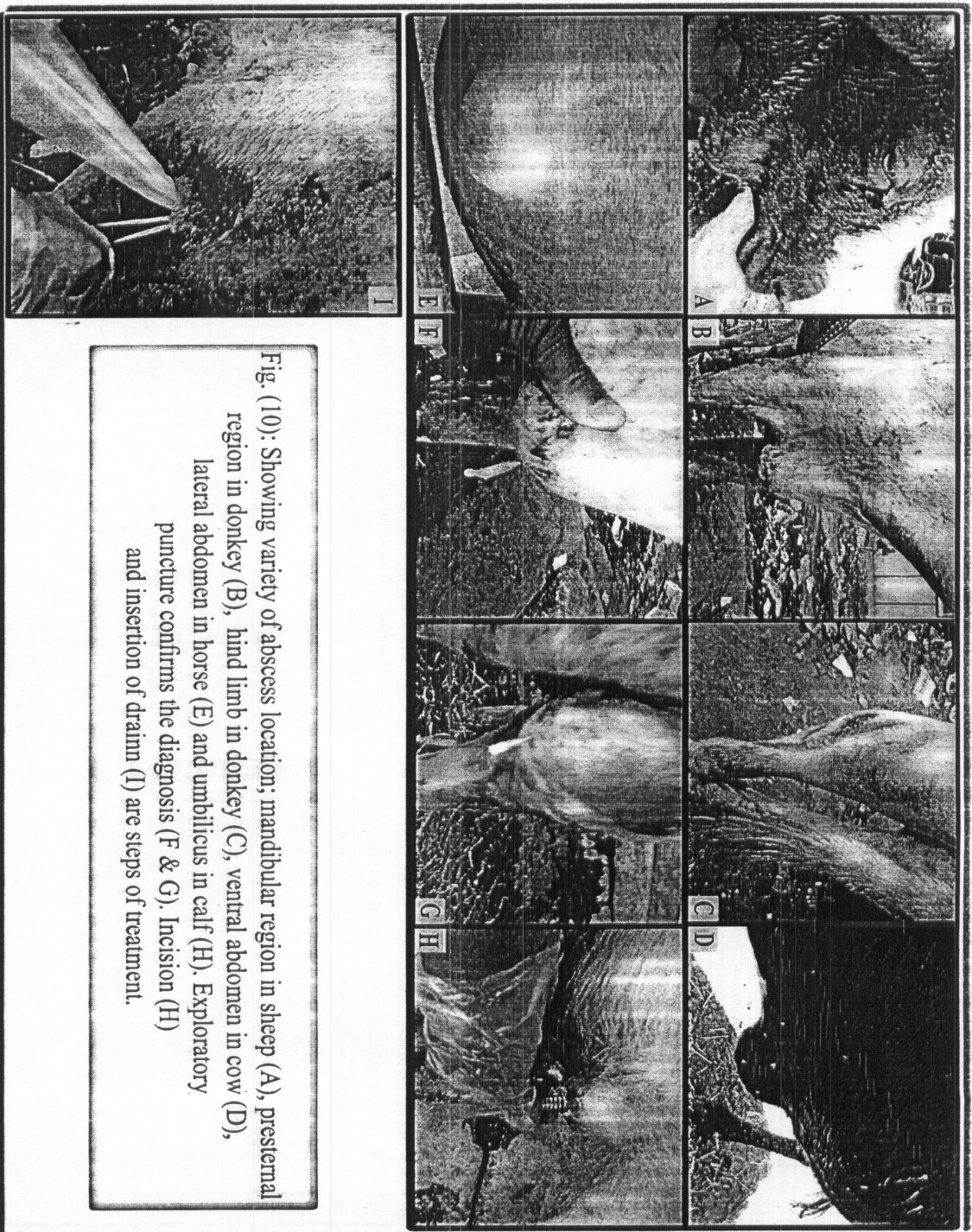


Fig. (10): Showing variety of abscess location; mandibular region in sheep (A), prestermal region in donkey (B), hind limb in donkey (C), ventral abdomen in cow (D), lateral abdomen in horse (E) and umbilicus in calf (H). Exploratory puncture confirms the diagnosis (F & G). Incision (H) and insertion of drain (I) are steps of treatment.




Fig. (11 A): Showing cystic swelling in the presternal bursa of 5 years old buffalo cow (A) and inflammatory swelling in suprascapular bursa of 6 years old donkey (B).




Fig. (11 B): Showing localized presternal swelling in a 5 years old cow due to presternal bursitis (A) and 8 years old buffalo cow with localized physiological edema (B) and another one due to localized pathological edema as a result of traumatic pericarditis (C) characterized by jugular congestion (arrow).




Fig. (12): Showing treatment of cystic form of bursitis. Preparation of the area of puncture with antiseptic (A). Needle aspiration (B, arrow). Bursa is punctured with scalpel tip to induce large opening (C).




Fig. (13): Showing olecranon bursitis in 5 years old horse (A), presternal bursitis in 9 months old buffalo calf (B). The same calf one week after treatment with 5 % iodine ointment (C), and after 14 days (D) later.

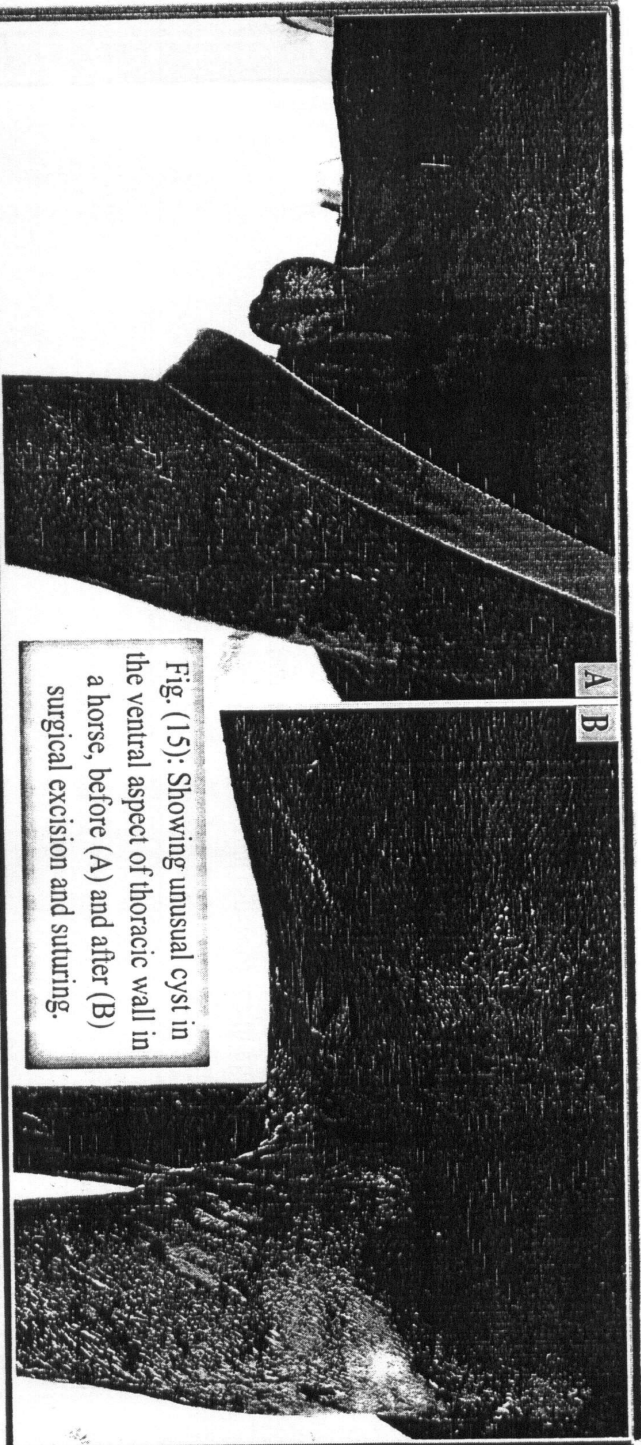


Fig. (15): Showing unusual cyst in the ventral aspect of thoracic wall in a horse, before (A) and after (B) surgical excision and suturing.

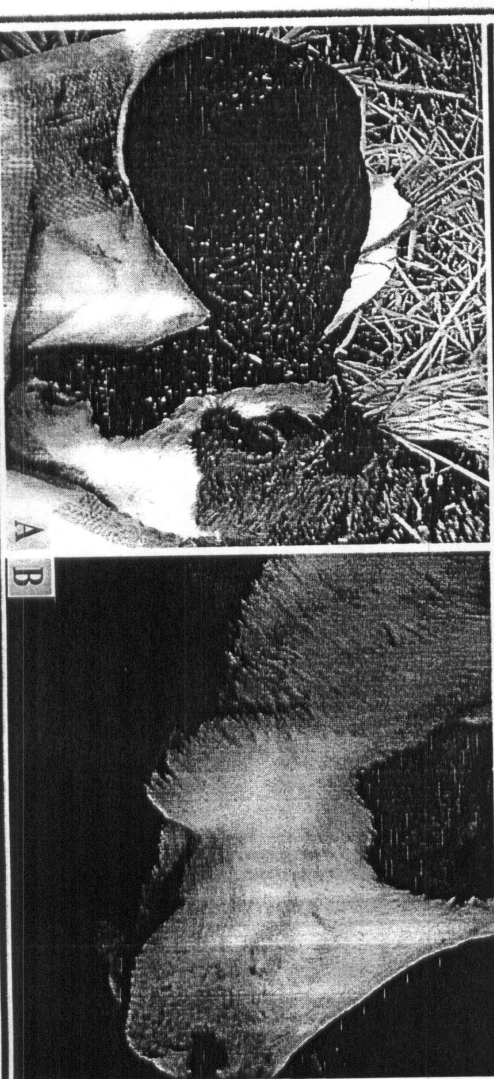


Fig. (14): Showing a case of meningocele in newlyborn calf (A) and a nother case of sialocele in one year old calf (B).

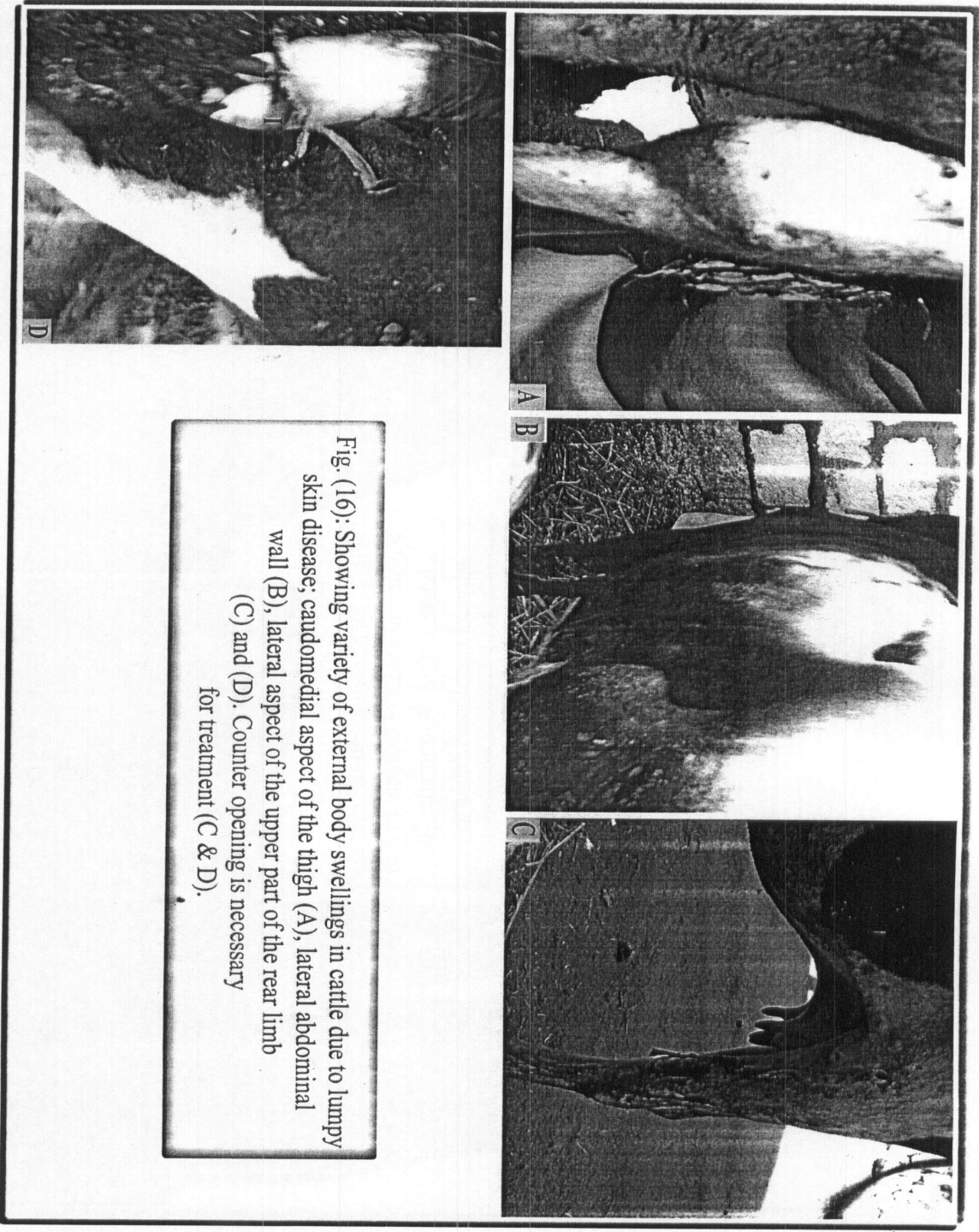


Fig. (16): Showing variety of external body swellings in cattle due to lumpy skin disease; caudomedial aspect of the thigh (A), lateral abdominal wall (B), lateral aspect of the upper part of the rear limb (C) and (D). Counter opening is necessary for treatment (C & D).



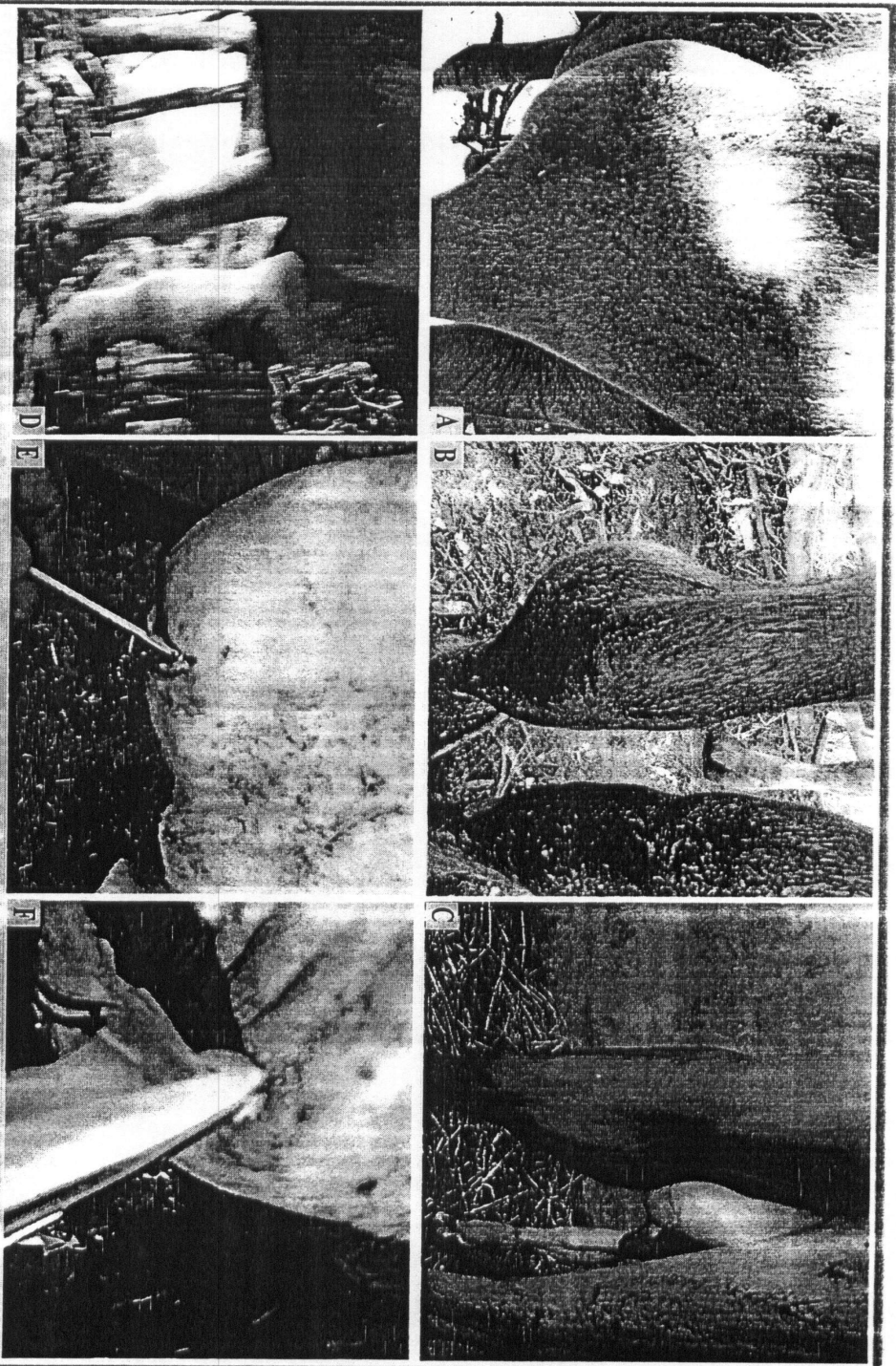


Fig. (17): Showing variety of body swellings in buffalo due to oedematous skin disease; in stifle region (A), anteriolateral aspect of hock region (B), anteromedial aspect of hock (C), whole fore limb (D) and ventral abdomen (E). Mature swelling was surgically treated as abscess (F).

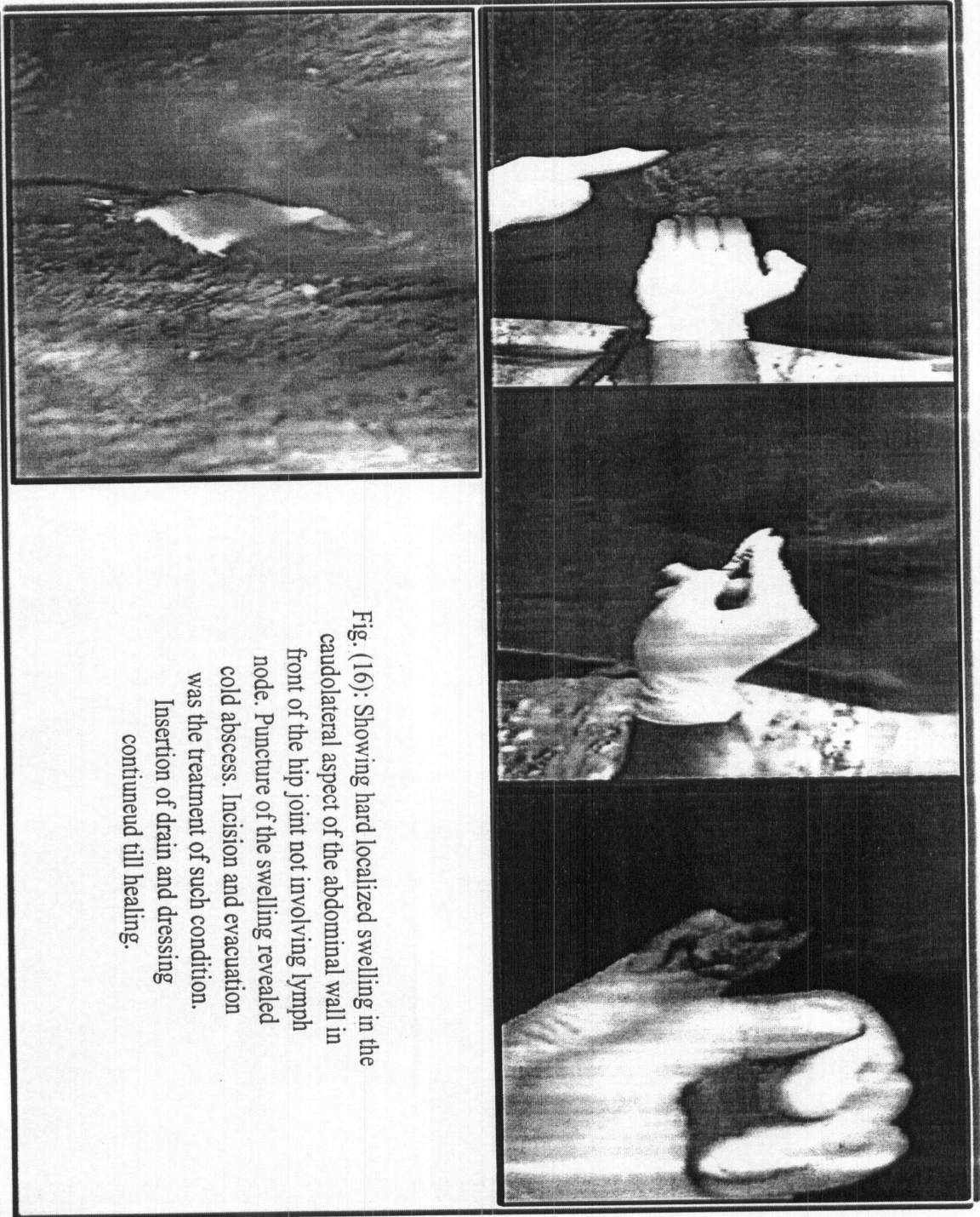


Fig. (16): Showing hard localized swelling in the caudolateral aspect of the abdominal wall in front of the hip joint not involving lymph node. Puncture of the swelling revealed cold abscess. Incision and evacuation was the treatment of such condition. Insertion of drain and dressing continued till healing.

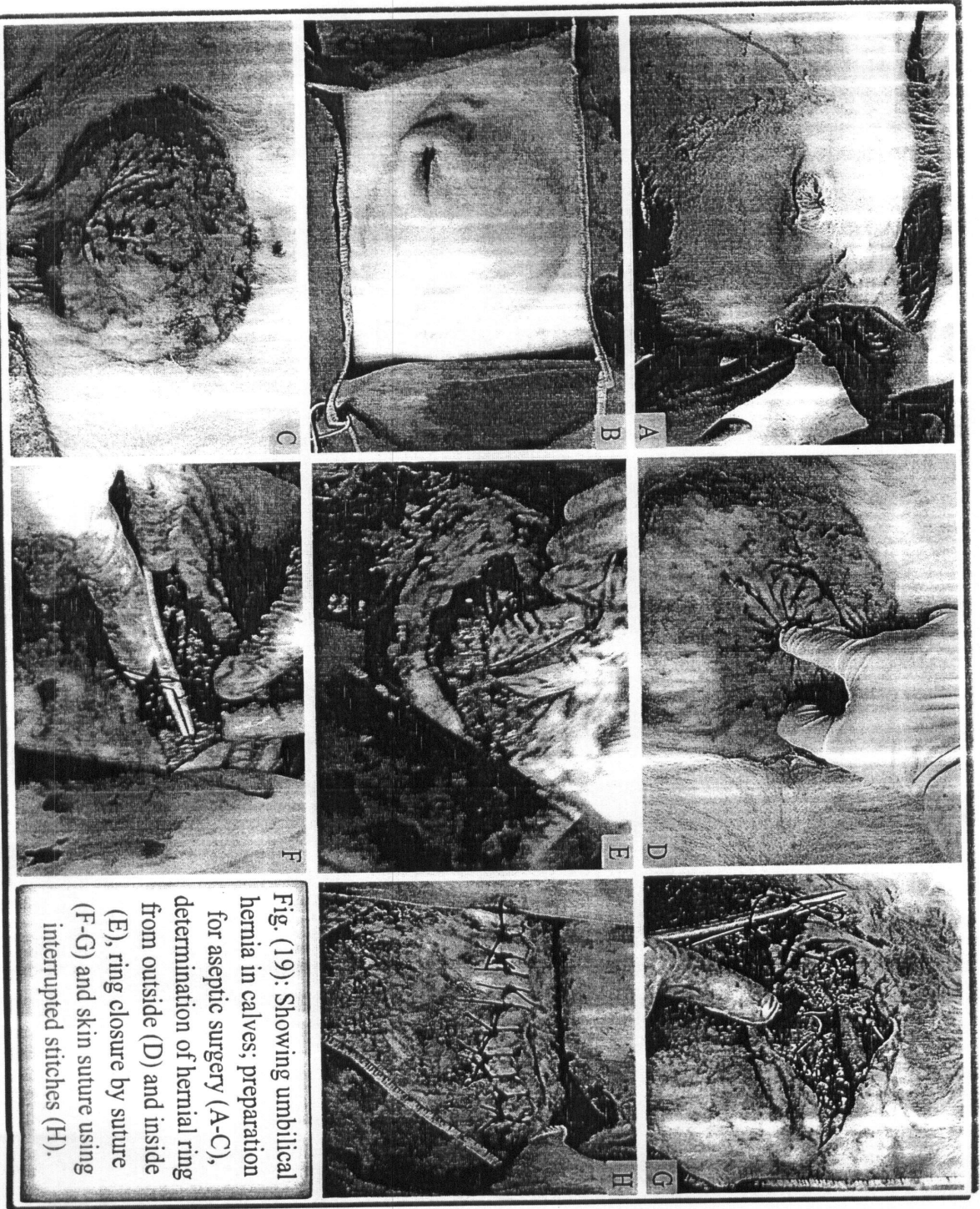


Fig. (19): Showing umbilical hernia in calves; preparation for aseptic surgery (A-C), determination of hernial ring from outside (D) and inside (E), ring closure by suture (F-G) and skin suture using interrupted stitches (H).

Fig. (20): Showing ventrolateral abdominal swelling in 8 years old horse as a result of a motor accident.

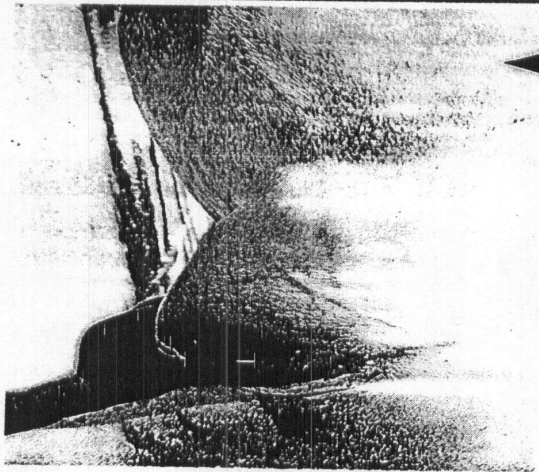


Fig. (22): Showing treatment of scrotal hernia. Scrotal incision, castration, reposition of hernial content and ring closure.

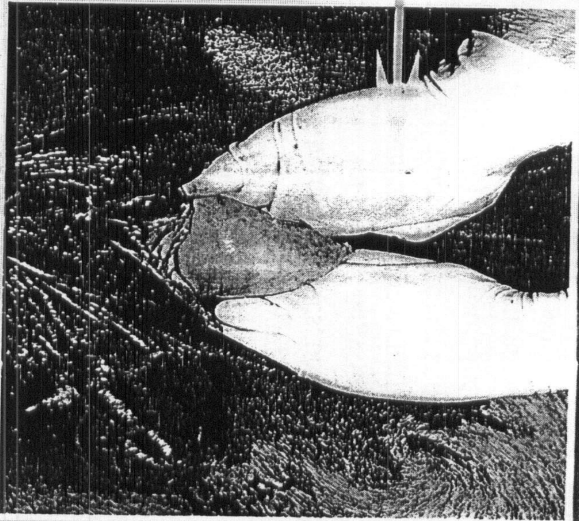
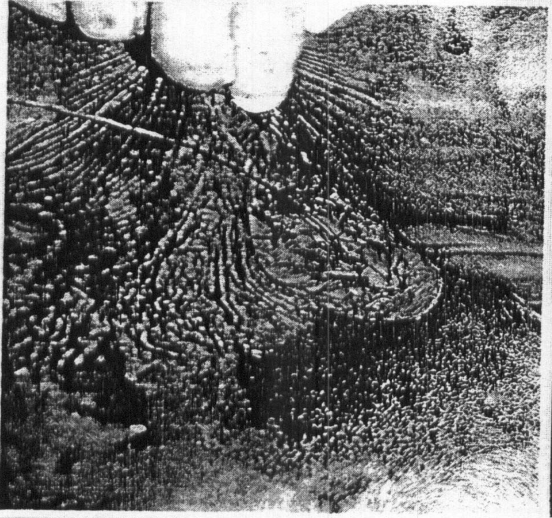
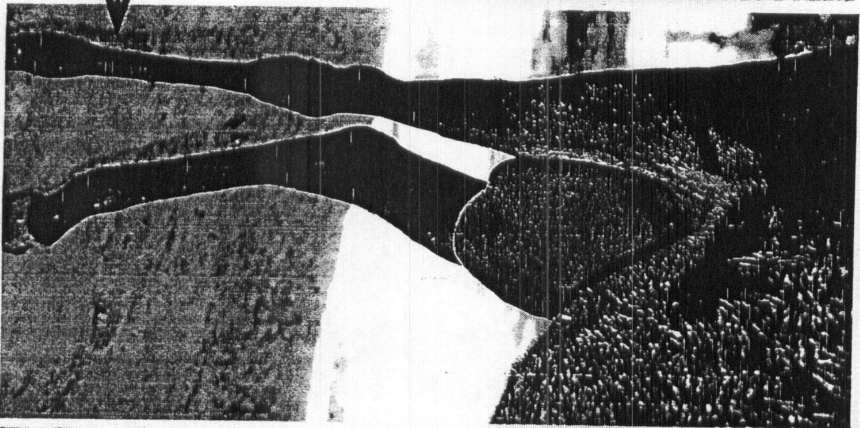
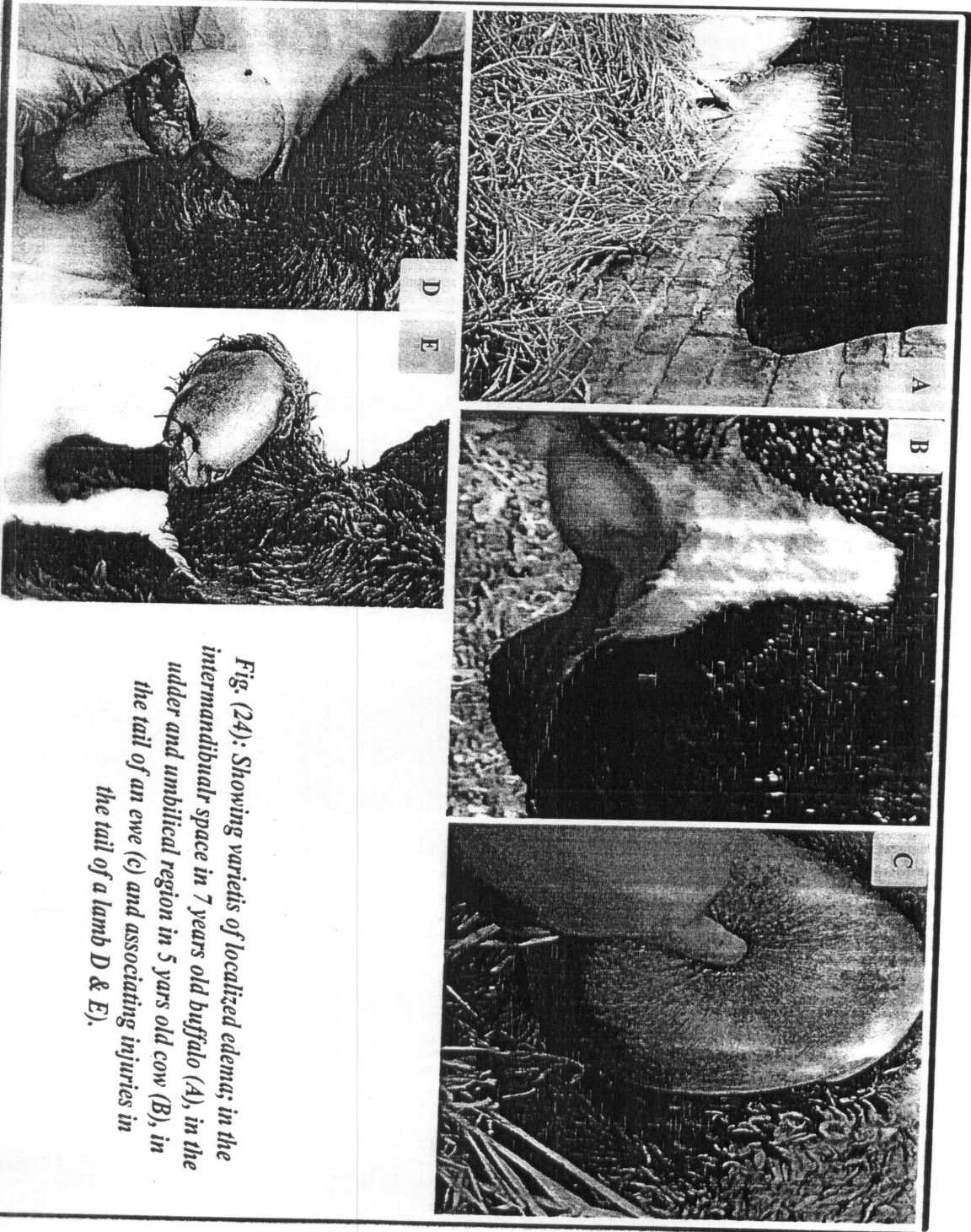


Fig. (21): Showing bilateral scrotal swelling in 7 years old donkey. Examination revealed that the condition is due to scrotal hernia.





*Fig. (24): Showing varieties of localized edema; in the intermandibular space in 7 years old buffalo (A), in the udder and umbilical region in 5 years old cow (B), in the tail of an ewe (C) and associating injuries in the tail of a lamb D & E).*

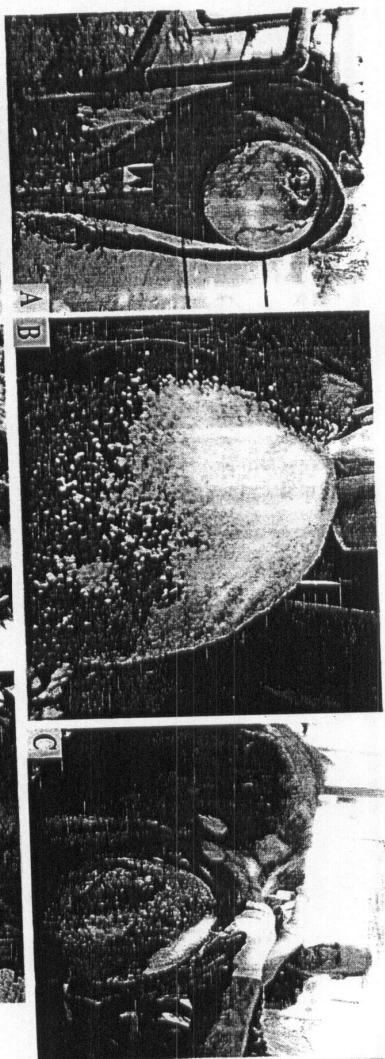


Fig. (24): Showing large round perineal swelling in buffalo cow (A). Washing and disinfection of the prolapsed swelling using antiseptic and dehydrating agent (B). Epidural analgesia before reduction (C).

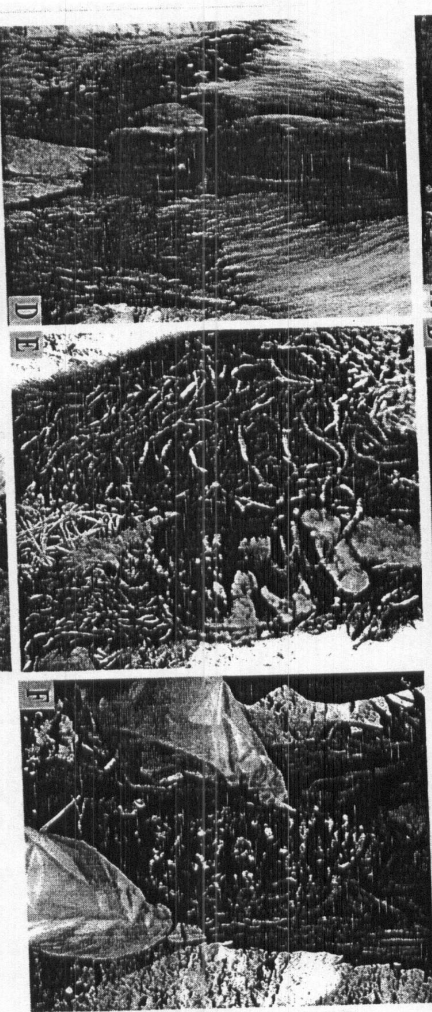

Fig. (25): Showing variety of cases of partial vaginal prolapse (D), complete rectal prolapse (E) in donkeys and complete uterine prolapse in an ewe (F)

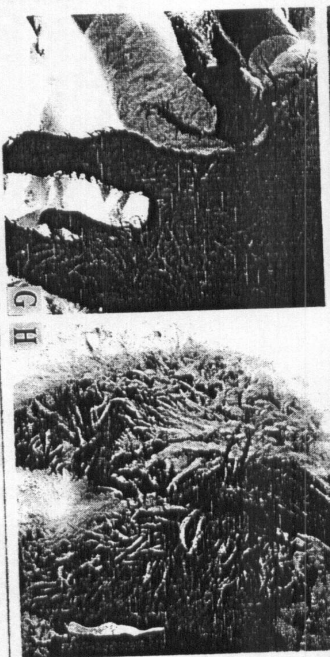

Fig. (26): Showing recent complete rectal prolapse in donkey immediately before (G) and after reduction (H).

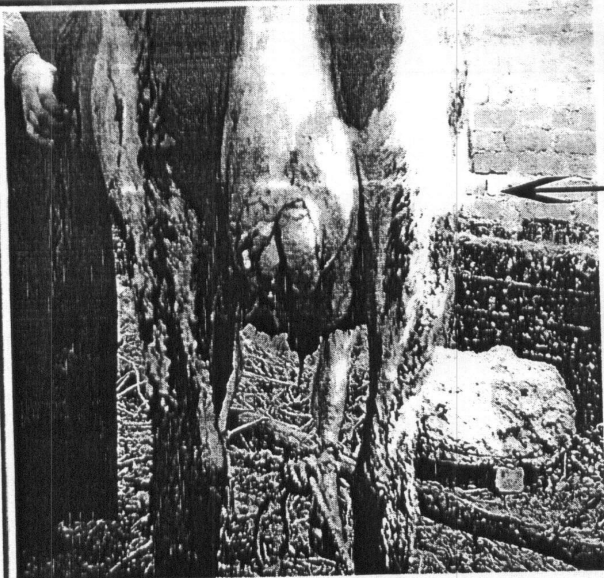
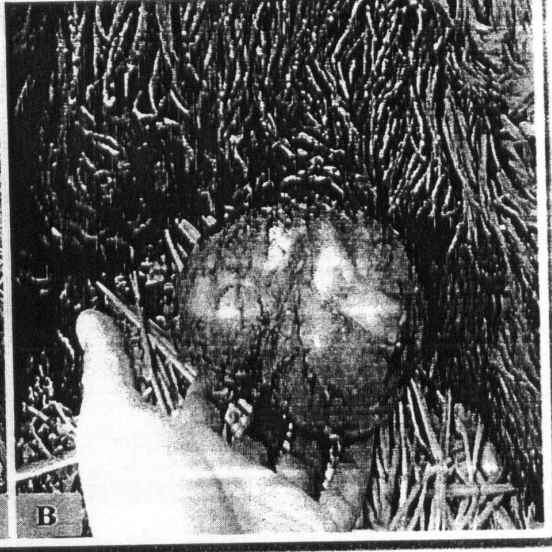

Fig. (27): Showing unusual abdominal hernia in the udder tissues of 5 years old cow (A) and large and ellongated clitoris in 1.5 years old heifer (B).



Fig. (28): Showing epetheliogenesis imperfecta with intact peritoneum in newlyborn calf (A & B).



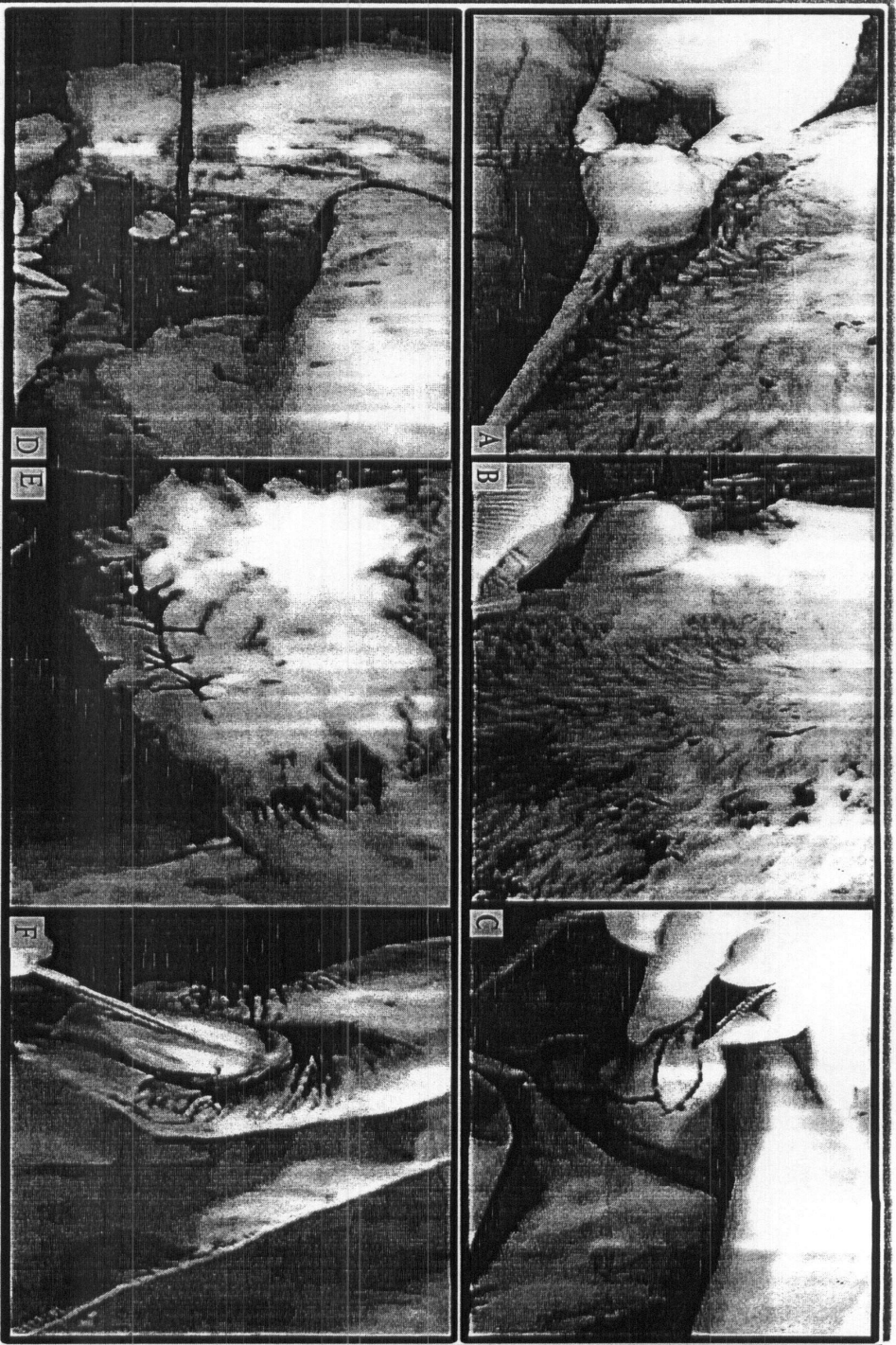


Fig. (29): Showing Localized umbilical swelling in a calf (A). Infiltration analgesia after area preparation (B). Elliptical incision for swelling exploration and excision (C). Excision of the swelling and ligation of the umbilical cord (D). Wound closure by skin suture (E). Opening of the removed intact swelling revealed presence of caseated pus (F).



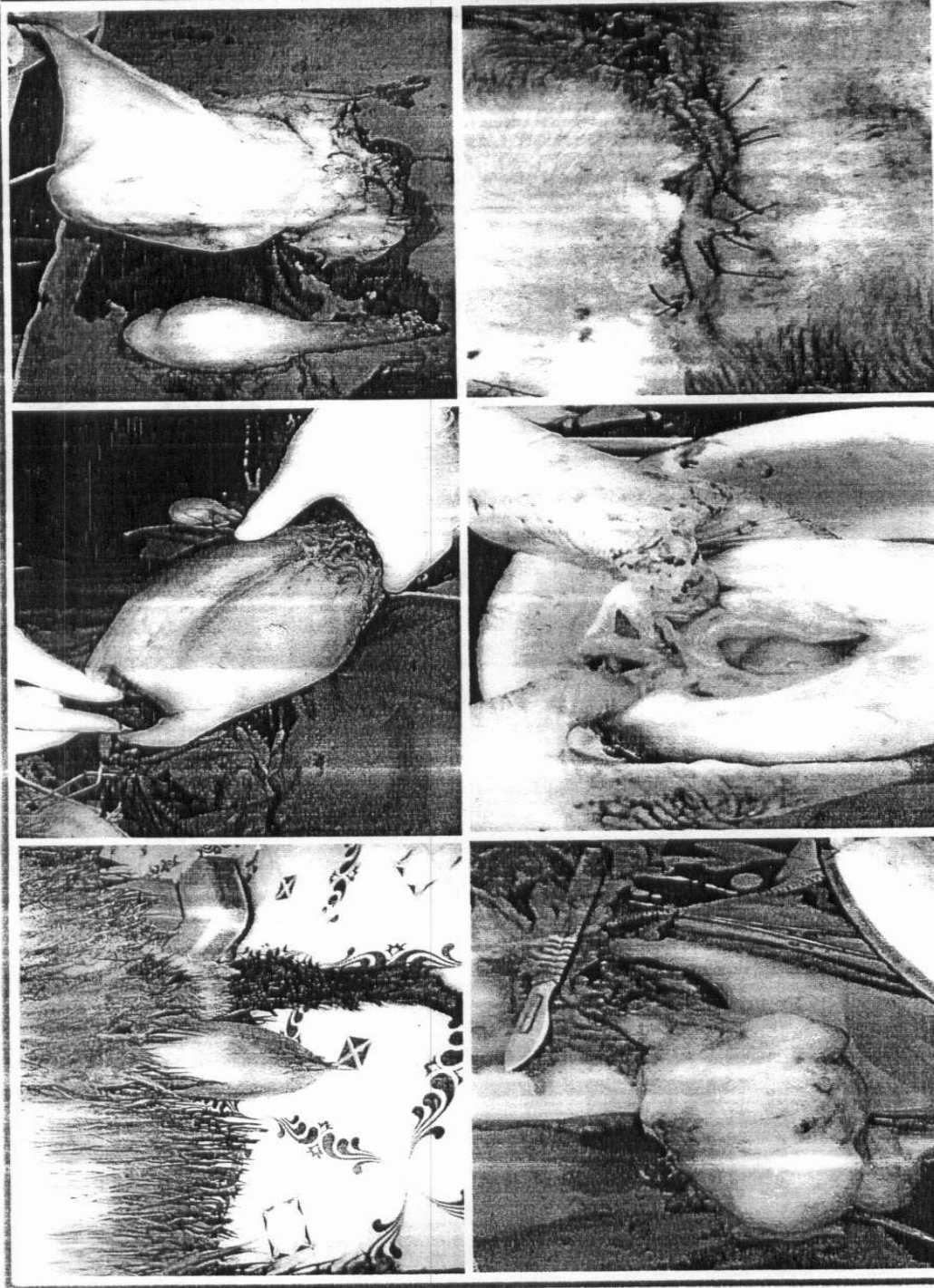


Fig. (30): Showing testicular swelling in a ram, preparation for aseptic castration, unequal excised testes, punctured testis revealed pus and degenerative changes. Wound coaptation.

## Discussion

In the present study, varieties of external swellings were recorded in different farm animals including external neoplasms, abscesses and, bursitis, cysts, infectious swellings due to oedematous skin disease (O.S.D) and lumpy skin disease (L.S.D), hernia, localized oedema, and prolapse. Otherwise lumpy skin disease that appeared in a period related to the time of this study, the most common swellings recorded here were abscesses, hernias, bursitis, neoplasms, prolapse, edematous skin disease, pathological edema and cysts. Abscess was the most prevalent swelling, while cyst proved to be the least, resembling the results described by *Oehme (1988)*, *Blood and Radostits (1994)*, *Ismail (1999)* and *Abdalla (1999)*.

Incidence of neoplasm is variable, depending on anatomical location, type of animal, diagnostic criteria for classification and other ill-defined factors these are in agreement with *(Roony and Robertson, 1996)*. on the other hand different types of cutaneous neoplasms were reported in different domesticated animals by *(Blood and Handerson, 1979; Kassem, 1980; Abdalla, 1999 and Semieka and Mubarak, 2002)*.

In the present study, neoplasms were detected in different regions among body surface, especially head and neck region similar to the findings of *Oehme and Prier (1974)* and *Semieka and Mubarak (2002)*. There were no great difference between papilloma and fibroma regarding their origin and characteristics. Cutaneous neoplasms represented high incidence among other external swellings. Lesions were more common in cattle and appeared in form of warts scattered in different regions of the skin. *Jenning (1984)* and *Ismail (1999)* described similar findings.

Incidence of neoplasms in old aged cattle and buffaloes come in agreement with the findings of *Moustafa et al. (1989)* who mentioned that warts usually affect old aged buffaloes. On the othe hand *Abdel-Aal (1976)*, *Blood and Handerson (1979)*, *Jenning (1994)*, *Ali (1995)* and *Abdalla (1999)* recorded their higher incidence in young animals especially heifer under two years old. Meanwhile, *Bagdonas and Olsen (1953)*, *Soliman and Iskander (1963)* and *Kassem (1980)* recorded their incidence in all ages.

Incidence of equine neoplasms in the present study was rare as compared with other species. They were recorded in localized form. These findings resembled those described by *Semieka and Mubarak (2002)*. The observed features of neoplasms in donkeys represented the same described by *Kassem (1980) and Oehme (1988)*. *Fargaly and Gaballa (1991) and El-Magrhaby (1996)* who recorded that fibroma is more common in donkeys than papilloma.

Higher incidence of neoplasms in females than males, in all species, may be attributed to sex that plays a role in the incidence of neoplasms. This come in agreement with *Moustafa et al. (1989)*, *Rooney and Robertson (1996) and Semieka and Mubarak (2002)* who found a link between sex and incidence of neoplasms. While *Nooruddicin et al. (1989)* recorded that buffalo bull were commonly affected than buffalo cows in India, and attributed these findings to the high ratio of males in the examined buffaloes.

Concerning treatment of cutaneous neoplasms, surgical excision proved to be the radical treatment and was not followed by recurrence. Excision followed by suturing or thermocauterization was helpful according to the size and the site of neoplasms. When the neoplasm is present in less movable part and the size is extended to a limited permit re-apposition of the skin edges, suturing is the most reliable method (*Kassem, 1980; Venugopalan, 1994 and Abu-Seida, 1998*). while *Jenning (1984) and Vagel (1996)* noticed that 50% of the tumor will reappear after surgical treatment especially when the tumor occurs in highly movable part.

Treatment of the neoplasms by thermocautery following excision proved to be effective especially in very large size ones when suturing is so difficult. A similar protocol is adopted by *O'Connor (1985)*, *Greenough (1988) and Johnson (1988)*. *Meanwhile, Borthwick (1972) and Mohamed (1988)* recorded that thermocautery failed to give good results.

In the present study ligation of small sized neoplasms for 15 days appeared to be satisfactory, where obstruction of blood vessels and stoppage of nutrition of this part lead to its atrophy and sloughing. Excellent outcome obtained at overall skin neoplastic tumor treatment indicated the effectiveness of surgical treatment and acceptable character of tumors for treatment. This may be due to most of cases met with in this study were benign.

In the present study, abscesses were frequently seen in different farm animals. These agreed with *Blood and Radostits (1989)*, *Ramadan (1994)*, *Abu-Seida (1998)*, *Abdalla (1999)* and *Ismail (1999)* attributed occurrence of abscesses to the invasion of skin by pyogenic bacteria via ticks or fly bites, punctured wounds, bites from other animals, trauma, infected hematoma or secondary other skin diseases as pox.

Clinical signs and exploratory puncture of the abscess may help to determine the accurate diagnosis and the line of treatment. Soft abscesses in this study were surrounded by thin wall. While in old cases, the pus was usually inspissated and caseated due to absorption of its fluid contents. In long standing cases it becomes hard in consistency as in case of caseous lymph adenitis. Similar findings were observed by *Ali (1995)* and *Ismail (1999)*.

On exploratory puncture, abscesses usually contain pus of various colors, odours and consistency. The colour of pus was creamy, yellowish, watery or thick and varied in volume from very scant to about 250 ml. *Senna (1994)*, *Abu-Sieda (1998)* and *Ismail (1999)* added that the colour is tinged with blood in traumatized abscesses.

Concerning the seats of abscess formation, abscesses were encountered anywhere of the body but the most common seats of abscesses among farm animals were head and neck region. These findings similar to that observed by *Bauomy (1988)*, *Andrews et al. (1992)*, *Danji et al. (1996)*, *Saraha (1997)* and *Abu-Seida (1998)*. They attributed that to trauma of different source as hitting to the manger, animal kicking its head and neck by hind limb when suffering from ticks or mange or fault subcutaneous injection of highly irritant drugs.

Concerning umbilical abscesses, in the present study it was more common in unhygienic environment and bad management of umbilical cord after parturition. Young calves between 1 month to 1 year old showed higher incidence, the same observation are in agreement with *Khamis (1979)*, *El-Sayad (1991)* and *Geishauser and Grunder (1992)* and *Kenawy 1988*. The recorded cases of umbilical abscesses in cows were attributed to trauma from the floor or as complication to biting from another animal. Umbilical hernia in cows may develop in minute cases as a complication to umbilical abscess

Higher incidence of umbilical abscesses in calves than buffalo calves

came in agreement with the findings of *Senna (1994)* and disagreement with the results recorded by *Khamis (1979)*, *Roberts (1980)*, *Youssef (1984)*, *El-Sayad (1991)*, *Gishauser and Grunder (1992)* and *Abdalla (1999)*. Who concluded that umbilical abscesses were high in buffalo calves than calves. This observation may be attributed to the high number of cattle in related to buffaloes in our localities. While *Roberts (1980)* noticed that foals suffer more frequently from the umbilical infection than calves and other species of young farm animals.

Recording of abdominal abscesses at the ventral abdominal wall of cattle, sheep, goats and equine rather buffaloes, may be due to the histological nature of the buffalo skin and its specific immunity. Incidence of the udder abscesses was higher in cattle than sheep and goats. These results are similar to that obtained by *El-Sayad (1991)* and *Abdalla (1999)*.

Higher incidence of abdominal abscesses in sheep than goats may be attributed to infection of the skin by pyogenic microorganisms especially after shearing. These are in agreement with *Abu-Seida (1998)* and *Abdalla (1999)* obtained similar results. On the contrary, *Tadayon (1980)* found that goats were highly affected by abscesses than sheep. That may be due to the less protection of the goats by hair coat as in sheep.

Presence of abdominal abscesses behind the left elbow may be attributed to a penetrating wound as a sequellae to traumatic reticulitis. The sharp foreign body penetrates the reticulum downwards toward the ventral abdominal wall. The same results were obtained by *Oheme and Prier (1974)*, *Blood et al. (1989)*, *El-Sayad (1991)* and *Misk et al. (2005)*.

Hind quarter and thigh abscesses may be attributed to faulty injection, especially highly irritant drugs by unsterilized needle. This determines why these abscesses are commonly deeply seated. Most of these abscesses require counter opening to promote free and easy complete drainage. Concerning predilection seats of abscesses in equine, it was observed mainly in limbs, withers and sternum due to repeated trauma by shoe, saddle and manger.

Considering line of treatment of abscesses, maturation of unripened abscesses was considered a very important point in treating abscesses. Hot application or mild rubefacients are beneficial in these cases. These come in agreement with the results recorded by *Pavletic (1985)*, *Oehme (1988)* and *El-Sayad (1991)*. Although surgical interference for abscesses is the only

solution for treatment, any trail to open an abscess before sufficient maturation is very high mistake these agreed with (*Oehme, 1988*).

Routine treatment by opening, evacuation and drainage is the most suitable treatment (*Smart et al., 1978; Othman et al., 1984; El-Sayad, 1991 and Abu-Seida, 1998*).

*Khamis (1979), Ramadan (1994) and Ali (1995)* advised that total excision was the best approach for some cases, especially in head and neck.

Lancing of the abscesses at the most lower point is essential to maintain an easily way for drainage of accumulated pus. Attention should be put in mind in abscesses at the critical site as in the level of jugular vein, parotid duct or udder abscesses to avoid injury of untreated quarter. These results are in agreement with (*Kinght et al., 1980; Pavletic, 1985; Oehme, 1988 and Nguttu- Mawangi et al., 1989*).

As regards, bursitis in the present study, it was highly recorded in buffaloes (mainly olecranon and presternal bursitis) as compared with horse and cattle. These results come in agreement with *Frank (1961), O'connor (1965) and Plackhotin (1981)* who showed that the common cause of capped elbow was trauma due to hitting of the point of elbow by the foot of the affected limb, when the animal is lying down on hard ground or with lack of bedding.

Regarding presternal bursitis it was recorded mainly in buffalo calves and to a lesser extends in cattle and the main cause was trauma in crowded farm especially those with concrete steel floors without litters and with hard manager. This comes in agreement with *Helmy et al., (1970), Plackhotin (1984), and El- Sheikh (1996)*.

Supraspinous bursitis was recorded in the present study in equine only. Trauma due to friction of the saddle with the affected part proved to be the cause (*Sullivan, 1981*). *Bolbol (1978)* recorded supraspinous bursitis in buffaloes and attributed the main cause to continuous friction of the subcutaneous bursa. Meanwhile, *Frank (1961, 1964 and 1981)* and *O'connor (1985)* mentioned that supraspinous bursitis rarely occur in beef cattle. and *Frank (1981)* attributed the main cause to actinomycosis or brucellosis. while *O'connor (1985)* showed that bacillus abortus or oncocerca reticulate may be the causative agent.

The most recorded cases had no general effect on health and no

lameness. In acute cases, there is local pain especially during extension and flexion of the joint in the affected region. *Venugopalan (1994)* confirmed these results.

Many literatures discussed clinical symptoms and treatment of bursitis. The cases required immediate treatment were those showing symptoms disturbing general health condition. Medical and/or surgical treatment were available according to the nature and condition of the lesions these results are in agreement with those mentioned by (*Newton et al., 1974; Bolbol, 1979; Greenough et al., 1981; Dietz and Turner, 1984; Mellwraith, 1987; Oehme, 1988; Nguhiu-Mowngi et al., 1991; Das et al., 1992; Venugopalan, 1994; Honnas et al., 1995*).

Two types of cysts were recorded in the present study (retention cysts and branchial cysts). Branchial cyst was the most common type of cysts recorded in the present study. The swelling began as a fluctuating small cyst and increased gradually in size. This observation comes in agreement with that observed by *Abdalla (1999)*.

Branchial cysts in the present study were recorded mainly in cows aging more than 2 years and located at the anteriolateral aspect of upper and middle third of the neck. Surgical excision of the intact cyst through sharp and blunt dissection proved to be the treatment of choice.

In our results Sialoceles were less commonly encountered. Their incidence was common in calves around one year and in buffaloes over 5 years. That may be attributed to feeding behaviour. Care should be taken during handling such cases for diagnosis and treatment as they may be complicated by salivary fistula. Our experience indicated that many cases of sialoceles are usually converted to salivary fistula due to bad handling by ointments or puncturing. Similar findings were observed by *Misk et al. (1994) and Abdalla (1999)*.

A storm of infection of lumpy skin disease occurred in Egypt between November 2004 and November 2006 and to a less extent few cases appeared in September 2007. Many hundreds and thousands of affected cattle were observed with different symptoms and complications of various degrees of severity rather than the classical symptoms these reported by *Ali and Obeid (1977), Kahrs (1981) and Hafez et al. (1992)*.

Concerning treatment of lumpy skin disease, symptomatic treatment with antibiotics and immune stimulant proved useful and effective against secondary infections and recovery was dependant mainly on the immune status of the infected animal. From the surgical point of view, surgical intervention was obligatory in many of the cases of lumpy skin disease, especially, in the period of storm infection, where most cases were complicated and long standing. Sloughing of skin nodules leaving ulcers and gap filled with pus was common. These lesions were sometimes extended for several centimeters along the course of the lymphatic vessels accompanied with chronic edema, especially in the brisket, which necessitated lancing and evacuation until complete recovery following healing by second intention. Surgical treatment was therefore an important step for the real and actual treatment of this form of the disease. It is therefore important to pay attention of different intended authorities to do their best for selecting and applying the suitable vaccine against this disease to reduce the possible economic losses.

Incidence of oedematous skin disease in buffaloes only proved to be correlated with species and breed susceptibility. This comes with the agreement of *Soliman (1996), Abdalla (1999) and Farghaly (2007)*. Meanwhile, *Kassem (1980), Fouad et al. (1984), Barakat (1985), Zaghawa and El-Gharib (1994) and Hamoda (1996)* who recorded that the disease in cattle also but in a lesser extent. All above authors coincided that spreading and occurrence of the disease in summer season indicating that the environmental conditions play a major role in the epidemiology of the disease.

It was found that the age of the affected animal with oedematous skin disease ranged from 18 -84 months. Similar results were described by *Nawal et al. (1995) and Hamoda (1996)*. While, *Amal (2002) and Farghaly (2007)* who found that the age of affected animals ranged from 6-48 months. Regarding the sex of involved animals, it was found that the females were mainly susceptible than males. That may be attributed to less number of males that are slaughtered in young ages. *Farghally (2007)* recorded the same findings, while *Ibrahim (1983)* recorded the disease in females only.

Variation in clinical signs and prognosis of cases of edematous skin disease may be related to time and line of treatment. Medical and/or surgical treatment proved to be the ideal protocol of treatment these ar in agreement with (*Kassem, 1980, Fouad et al., 1984 and Farghaly, 2007*).



Regardless the types of hernia, cattle in this study proved to be the most animal species affected with hernia. Umbilical hernia resembled the most types of hernia. The same results were mentioned by *El-Sayad (1991)*.

There were a positive correlation between the history of the hernia and the degree of adhesions. The hernial contents were rarely adherent to the hernial sac except in old and neglected cases where loosely adhesions occur these are agreed with that mentioned by (*Cutcott and Smithcors, 1972; Oehme and Prier, 1974 and Al-Sobail et al., 2007*). While *El-Sobail et al. (2007)* attributed the incidence of abdominal hernia in adult female animals, especially heavy pregnant, to stretching of the abdominal muscles as a result of pressure of fetus and fetal fluids.

Incidence of lateral abdominal hernia in right side caudal to the last rib may be attributed to anatomical considerations, as the rumen occupies the most abdominal cavity in the left side and the trauma or kicking from another animals was the main cause (*Oehme and Prier, 1974, Tirgari, 1980 and Walker, 1996*).

Ventral abdominal hernia was commonly observed close to the lower part of the costal arch in cattle, cranial to the udder in cows, sheep and goats and also found beside the penis in horses. Thrust from some blunt objects appeared to be the common cause of this type of hernia (*Hoflund, 1996, Misk, 1982 and El- Sayad, 1991*).

The V-shaped cutaneous incision followed by overlapping interrupted mattress suture of hernial ring with sterile silk or chromic catgut was successful for correction of umbilical hernia in male calves to avoid abnormal deviation of the penis after healing these results agreed with that mentioned by (*Nassef, 1990 and El- Sayad, 1991*).

Interrupted mattress suture allowed successful closure of hernial ring and good healing following surgical interference for treating the cases of ventral abdominal hernias. The obtained results similar that mentioned by *Loomis (1967), Gibbans et al. (1970 and El-Sayad (1991)* who considered interrupted mattress the best suture pattern for such cases. On the other hand, *Lokshmipathy (1975) and Trigari (1980) preferred* overlapping mattress suture for closing the muscular ring in cases of ventral abdominal hernia. Complications following open reduction may be correlated with the adapted

technique, the selected materials, and animal behaviors.

In our study scrotal hernia as a progressed inguinal hernia has a direct harmful effect on the accompanied testes. Atrophy was a common sequel. Castration via opening of the tunica vaginalis proved to be the only solution after reduction of the hernial content.

Pathological oedema was accompanied with disturbance in body condition as rise in body temperature, diffuse painful swelling and anorexia. Concerning their incidence, *El-Sayad (1991) and Abdalla (1998)* recorded such cases more in large animals, especially buffaloes, cattle and donkeys. Rare cases were found in sheep and goats.

Among the present investigation, traumatic pericarditis in buffaloes and cattle and severe skin injuries at the abdominal wall proved to be the main causes of localized pathological oedema in ruminants and equine, respectively.

Except for complicated or chronic cases, local treatment was effective and useful. *Michell (1996)* used diuretics and nonsteroidal anti-inflammatory in addition to local treatment. While *Heidrich (1968c)* made shallow skin incisions in the udder to relief oedema. Among this study, this protocol was restricted for the cases of oedema due to lumpy skin disease or those accompanying urine retention and ruptured urethra.

It is therefore clear that considering clinical features of any lesions, especially their nature and extention will help in accurate diagnosis and perfect management.

## Summary and Conclusion

The present study aimed to throw a light on the common and prevalent external swellings of the body surface in farm animals especially from clinical point of view considering the common clinical features, differential diagnosis and the right approach for surgical management. Localized swellings of the external body surface in different farm animals were recorded during the period between December 2005 and December 2007. Animals were collected from different localities of Kafr-El-Sheikh province and Surgery clinic of Faculty of veterinary medicine, Alexandria University.

A total number of (1830) cases were recorded including (1036) cattle, (427) buffaloes, (128) sheep, (48) goats, (81) horses and (110) donkeys. These animals included (436) male and (1394) females with variable body weight and ages between few days to 15 years old. Surgical interference was conducted in a routine manner according to type of the lesion considering its location and extension.

Animals were controlled physically and chemically using xylazine Hcl in ruminants given parentally and 10% chloral hydrate in equine given by I.V route. Local or regional analgesia using 2% lignocaine Hcl was also performed.

Neoplasms were recorded in (135) animals, (63) cattles (53) females and (10) males, (33) buffaloes (24) females and (9) males, (9) horses (4) females and (5) males, (15) donkeys (7) females and (8) males, (9) sheep (7) females and (2) males and (6) goats (4) females and (2) males. (33) cases were below 2 years old and 102 cases were above 2 years old.

Papillomas were recorded in (97) animals resembling 71.9%. Fibromas were recorded in (24) animals resembling 17.8%. Squamous cell carcinomas were recorded in (14) animals resembling 10.30 %.

Neoplasms were recorded in head and neck regions in (79) animals, limbs in (30) animals, chest and abdomen in (18) animals and tail in (8) animals.

Histopathological examinations were done for differential diagnosis between papillomas, fibromas and squamous cell carcinomas.

Abscesses in the present study were recorded in (183) cattle, (72) buffaloes, (60) sheep, (36) goats, (36) donkeys and (21) horses.

Abscesses were recorded in head and neck in (161) animals, umbilical (81), abdomen and chest (59), limbs (69) and udder (38). Abscesses were treated as usual by maturation and surgical opening.

Bursitis were recorded in (138) cases (5) in cattle were presternal bursitis, (125) in buffaloes where (69) cases were olecranon bursitis and (54) cases were presternal bursitis, (1) cases in horses were olecranon bursitis and (7) cases in donkeys were supraspinous bursitis which treated surgically by making opening and counter opening at the most lower point.

Cysts were recorded in 30 cases (19) in cattle (12) branchial cysts and (7) retention cysts and (8) cases in buffaloes (4) branchial and (4) retention cysts.

(561) cases of cattles infected with lumpy skin disease required surgical interference. Exploratory puncture following inspection and palpation was guide for surgical interference.

Oedematous Skin Disease was recorded in (99) buffaloes and Surgical interference gave good and acceptable results .

Hernia were recorded in (237) cases, (114) cattle, (27) buffaloes, (39) horses, (15) donkeys, (36) sheep and (6) goats. Umbilical hernias were recorded in (99) cases, (63) cattle, (27) buffaloes, (6) sheep and (3) horses. Lateral abdominal hernias were recorded in (54) cases, (24) cattles, (15) sheep, (9) horses and (6) donkeys, while ventral abdominal hernias were recorded in (42) cases, (21) cattles, (9) sheep, (6) goats and (6) horses.

Scrotal hernias were recorded in (42) cases (6) cattles, (6) sheep, (21) horses and (9) donkeys. Most cases found to have no adhesions while sever adhesions were fonud in some old cases. Most cases of umbilical hernias were recorded in newly born animals.

Surgical interference proved to be the ideal procedures for treatment of the different cases of hernias. The V- shaped skin incision technique for open reduction proved successful and ensured better exposure of umbilical hernias in males. Casteration of cases of scrotal hernia was performed following opening of the tunica vaginalis.

All cases of lateral abdominal hernias were recorded in right side in rumminants while ventral abdominal hernias were found in variuos sites of the ventral abdominal aspects. Surgical correction and management was successful in all cases.

Oedema was recorded in (87) cases, (51) cattle and ( 21) buffaloes (15 ) (9) sheep and (6) goats. They were managed by treating the actual causes. Pathological oedema characterized by oedematous swelling at chest and

sternal region and highly effect the general health condition and diagnosed as traumatic pericarditis.

Rectal prolapses were recorded in (18) cases (3) cattle and (15) donkeys. Complete prolapse of the rectum was recorded in (11) donkeys, while partial rectal prolapse was recorded in (4) donkeys and (3) calves.

Cases of rectal prolapses were treated surgically as usual.

Vaginal prolapse was encountered in (52) cases including (15) cows, (25) buffalo cow, (6) she donkeys and (6) ewes. Uterine prolapse was observed in (65) cases including (33) cows (17) buffaloe cow,(12) ewes and (3) She donkeys. After reduction of the uterus using of worm water intra- uterine was preferable to return the uterus to its normal position.

### ***Conclusion***

Based on the previous results, it could be concluded that the clinical features of each lesion, regarding its nature and extension, together with differential diagnosis will ensure the suitable approach for surgical management of any external swellings in farm animals.

## References

- Aanes, WA (1980)*: Herniorrhaphy, In: Amstutz, H.E.(ed) : Bovine medicine and surgery. 2nd ed. Am. Vet. Publ. Inc., Santra Barbara, U.S.A,pp 1221-1228.
- Abdalla AE (1999)*: Affections of skin and subcutaneous tissues in farm animals. Thesis for M.V.Sc of surgery. Fac. Vet. Med.Kafr. El- sheikh, Tanta Univ.
- Abdel-Aal ON (1976)*: Histopathological and histochemical studies of bovine papillomatosis. M.V.Sc. Thesis, Cairo Univ.
- Abd-El-Galil Y, Ammar MI, Youssef A and Kenawy A (1986)*: clinical and bacteriological studies of edematous skin disease in buffaloes and camels in Sharkia governerate. Zag. Vet. J. x1v (1) 268-277.
- Abdel-Wahed RE (2001)*: Surgical approach for some external swellings of special interest. 6th Sci. Cong. Egyptian Society for cattle diseases, 4-6 Nov. Assiut, Egypt.
- Abou-El- Ella AG and Tantawy AA(2000)*: External ear amputation for treatment of some unusual surgical conditions in buffaloes. Minufia Vet.J.1(1).
- Abu-Samra MT, Aziz MA and Homeida AM(1982)*: Clinical observations on bovine papillomatosis (warts). Br. Vet.J., 138-144.
- Abu-Seida AA (1998)*: Studies on surgical skin affections in ruminants. M.V.Sc. Thesis, Fac. Vet.Med., Cairo Univ.
- Abou-Zaid AA (2001)*: Corynebacterium Pseudotuberculosis in buffaloes and sheep. Vet. Med. J., Giza. 49, (3):435-450.
- Adams OR (1974)*: Lameness in horses. 3rd ed. , Lea & Febiger , Philadelphia , U.S.A.
- Adams SB, and Fessler JF (1987)*: Umbilical cord remnant infections in foals. J.A.V.M.A. 190, 3,316-318.
- Ahmed IH (1988)*: surgical affections of the salivary glands in some domestic animals. Thesis for the Ph.D. Fac. Vet Med. Assuit univ. Egypt.
- Ahmed IH, Misk NA , Taha M and Youssef HA (1990)*: Foreign body sialadenitis of the mandibular salivary gland in a cow. 4th Sc. Cong. Fac. Vet. Med.Assiut Univ.
- Al-Gaabary HH and Ammar KM (1999)*: Clinical and epidemiological studies on buffalo lymphangitis in Gharbia Governerate. 5th Sci Cong., Egyptian Society for Cattle Disease, 28-30. Nov. Assiut, Egypt. p.89-91.
- Al- Sobayil FA and Ahmed AF (2007)*: Surgical treatment for different forms of hernias in sheep and goats. J.V.sci.(2),8:185-91.
- Al-Ani FK (1989)*: Ovine and Caprine medicine. Vol.1, Mosul, Iraq, Higher Education press. P.105-106.
- Ali AM (1995)*: Prevalent surgical affections of head and neck in Equine and Ruminant in Assiut governorate. Thesis M.V.Sc. Surgery. Fac.Vet.Med. Assiut Univ.
- Ali BH and Obeid MM (1977)*: Investigation of the first outbreaks of lumpy skin disease in the suddan. Vet. Rec., 133: 184-189.
- Al-Sobayil FA, Ahmed IH and Mehana EE (2005)*: Surgical and pathological studies on the squamous cell carcinomas of sheep and goats. SCVMJ, VIII (2).
- Alvarenga, J., Haginwara MK, and De- martin BW., (1975)*: " Umbilical hernia in a cat" Mod. Vet. Pract., 56 (4): 260- 261.
- Amal Leil AA (1993)*: Incidence of surgical affections among sheep and goats in Domietta province. M.V.Sc.Thesis., Fac. Vet. Med., Cairo Univ.

## References

- Amal ME (2002):** Studies on Corynebacterium Pseudotuberculosis infection in buffaloes. Ph.D. Thesis, Fac. of Vet. Med., Cairo University.
- Amstutz HE (1978 a):** Treatment of warts in cattle. *Mod. Vet. Pract.*, 59(9):650.
- Anderson PH and Kirkwood Ac (1969):** The reaction in cattle to toxins of hypoderma bovine (Warble fly) larvae. *Br. Vet. J.*, 124-569.
- Andrews AH, Blowey Rw, Boyd H and Eddy RG (1992):** Bovine medicine. 1st ed. Oxford, Blackwell scientific publication, London, Edinburgh, Boston.
- Andrews C, Pereira HG and Wildy P (1978):** Viruses of the vertebrates 4th ed. London, Bailliere Tindall.
- Angus K, and Young GB, (1972):** A note on genetics of umbilical hernia. *Vet. Rec.* 90(12): 242-247.
- Angus OM and Jones LV (1993):** Equine reproduction Textbook. Lea and Febiger, Philadelphia, London
- Archibald J, Holt JC and Sokolovsky AV (1981):** management of trauma in dogs and cats (cutaneous and subcutaneous injuries) *Am. Vet. Publ. Inc.*, 321.
- Arthur GH, Noakes DE and Pearson H (1982):** vet. reproduction and obstetrics. Textbook. The English language book society and Bailliere Tindall. London
- Ashdown RR (1963):** The anatomy of the inguinal canal in the domesticated mammals. *Vet. Rec.* 75 (50):1345-1351.
- Ashfaq MK and Campbell SG (1980):** Experimentally induced caseous lymphadenitis in Goats. *Am. J. Vet. Res.* 41, (11); 1789-1792.
- Auer JA and Stick JA (1999):** Equine surgery. 2nd ed. W.B. Saunders Company. Philadelphia London Tokyo. 166-173.
- Awad FI (1966):** Studies on the So- Called "Oedematous skin disease" of buffaloes in the U.R.A. *Vet. Rec.*, 78, No.23.
- Awad FI (1966):** Studies on the so-called "oedematous skin disease" of buffaloes in U.R.A. *Vet. Rec.*, 78, No.23.
- Bailey DE (1984):** Digestive surgery in sheep and goats. In Jennings, P.B.: the practice of large animal surgery., Vol. 1, Philadelphia and London, W.B. Saunders company, p.681.
- Bailey JW (1972):** Veterinary handbook for cattlemen 4th ed., Springer publishing company, Inc. New York, p 221-424.
- Bain AM (1963):** Common bacterial infections of fetuses and foals and associated of the infection with the dam. *Australian Vet. J.*, 39, 413-422.
- Bancroft JD and Stevens A (1996):** Theory and practice of Histopathological techniques. textbook. 4th ed.
- Banks WC (1979):** Dermatologic problems in cattle. *Med. Vet. Pract.*, 60. No.2, 172-176.
- Banks WC and Barl-Morris (1975):** Results of radiation treatment of naturally occurring animal tumours. *J.A.V.M.A.*, 166, No.11, 1063-1064.
- Banks WC, Roberts R, Morris E and Hussey DH (1972):** Radiotherapy techniques in veterinary medicine. *J.A.V.M.A.*, 160(4): 446-450.
- Barakat Aa, and Eid FA (1971):** Bovine lymphangitis. *Vet. Res. Inst. Dokki, Cairo, N.A.R.*
- Barthold SW, Kollar LD, Olson C, Studer E and Holtan A (1974):** Atypical warts in cattle. *J. Amer. Vet. Med. Assoc.*, 165(3):276-280.
- Basher AP, Severin GA, Chavkin MJ and Frank AA (1997):** Orbital neuroendocrine

- tumours in three horses. *J.A.V.M.A.* 210 (5). 668-671.
- Bastianello SS (1983):** A survey of neoplasia in domestic species over a 40 year period from 1935-to-1974 in the Republic of South Africa. III tumors occurring in a pigs and goats. *Onderstepoort. J. Vet. Res.* 50, 25-28
- Bauomy AI (1988):** prevalent surgical affections in sheep and goats in Behira. M.V.Sc. thesis, Fac.Vet.Med., Alex.univ.
- Baxton N, Iris E and Cuthbert L (1981):** Gangrenous mastitis in a cow. *Mod . Vet. Pract.* July (2) 543-544.
- Behery AE (1992):** Evaluation of cryosurgery applications in animals. M.V.Sc Thesis.Fac.Vet.Med.Zagazig Univ. Egypt.
- Bellah JR (1993):** surgical management of specific skin disorders. In Slatter G.H. textbook of small animal surgery 2nd ed. W. B. Saunders, Philadelphia 341.
- Benesch F (1952):** Lehrbuch der Tierarztlichen Geburtshilfe and Gynakologie, Urban and Schwarzenberg, Wien, Innsbruck, Austria.
- Berge E and Westhues M. (1984):** Veterinary operative surgery 3rd ed. Baillire, Tindall& Cassell, London.
- Blood DC and Radostits OM (1989):** Veterinary Medicine. A textbook of the diseases of cattle, sheep, pig , goats and horses, 7th ed. English language book society, Bailliere, Tindall.
- Blood DC, and Henderson JA (1979):** Veterinary Medicine. 5th ed. Bailliere, Tandal and Gassel, London.
- Blowey RW (1991):** Navel abscesses (case report) *Ind.Vet.J.*70,302-303.
- Bojrab MJ and Constantinescu GM (1993):** Sutureless technique for repair of aural hematoma. In Bojrab, M.J.ed. current techniques in small animal surgery 3rd .ed. Philadelphia. W.B.Saunders, pp 135-136.
- Bojrab MJ and Taylor WT (1983):** Umbilical hernia. Current techniques in small animal surgery. 2nd ed.Lea and Febiger, Philadelphia, U.S.A., pp348-349.
- Bojrab MJ and Toomey AA (1983):** Perineal hernia. Current techniques in small animal surgery. 2nd ed. Lea & Febiger, Philadelphia, U.S.A., pp 401-405.
- Bojrab MJ And Toomey AA (1993):** Perineal hernia. In : Current Techniques in Small Animal surgery, edited by Bojrab, MJ.2nd ed., Philadelphia, Lea & Febiger.
- Boland WE (1951):** Anti- rheumatic effect of hydrocortisone (free alcohol), hydrocortisone acetate and cortisone (free alcohol ) as compared with cortisone acetate.*Brit.M.J.*1:559-564.
- Bolbol AE (1978):** Trails on the treatment of traumatic olecranon bursitis ( capped elbow) in buffaloes with some corticosteroids. *Assiut, Vet. Med. J.*Vol. 5, No.9 and 10, 333-341.
- Bolbol AE (1986):** haematoma at the forehead of a buffalo. *Vet. Med. Rev.*(2): 203.
- Bolbol AE, and El-Mezayen (1993):** Management of rectal prolapse in goats. *Zag. Vet. J.* Vol. 21.No. 5 pp.911-919.
- Bolbol AE, Bendary MM and Abou- Elfotouh M (1992):** Sternal fibromatosis in the dromedary camels. *Proc.1st . Int. Camel Conf.*, 419.
- Bolbol AE, Bendary MM and Abou- Elfotouh M (1992):** Sternal fibromatosis in the dromedary camels. *Proc. 1st. Int. Camel Conf.*, 419.
- Bolbol AE, El-Shazly MO and Al-Gasnawi YA (1991):** A clinicopathological study on squamous cell carcinoma in sheep and goats. *Egypt. J.Comp.Pathol.Clin. Path.*,



- 4 (1): 85-99.
- Borthwick R (1971):** The treatment of multiple perianal sinuses in the dog by cryosurgery. *J. Am. Anim. Hosp. Assoc.* 7, 45.
- Bright RM and Probst CW (1985):** Management of superficial skin wounds. In Slatter, D.H. textbook of small animal surgery, 1st . ed., W.B.Saunders Company, pp 431-443.
- Bright RM, and Probst CW (1985):** Management of superficial skin wounds. In Slatter, D.H. Textbook of small animal surgery, 1st ed., W.B.Saunders company 431-443.
- Burrow CF and Harvey CE (1973):** Perineal hernia in the dog. *J. Sm. Anim. Pract.*, 14: 315-332.
- Butler WF (1960):** Treatment of bovine cutaneous papillomata with autogenous vaccine. *Vet. Rec.*, 72(46): 1016-1017.
- Carpano M (1984):** Oedematous skin disease of the buffaloes. *Vet. Sec. Bull.*, 135.
- Catcott EJ and Smithcors JF (1972):** Equine medicine and surgery. 2nd . ed., Am. Vet. Publ. Inc. Santa Barbara, U.S.A.
- Cechner PE (1993):** Suture technique for repair of aural hematoma. In Bojrab, M.J ed. Current techniques in small animal surgery 3 rd ed. Philadelphia W.B.Saunders, pp 133-135.
- Chaffee PS (1964):** Fibromyxoma in camel. *J.A.V.M.A.*, 144 (10): 1114.
- Chakrabarti A, Pal B and Das BB (1994):** treatment of hematoma in dog- a non-surgical approach. *Indian Vet. J.* 71, 1229.
- Clark DM, Kostolish M and Mosier D (1989):** Branchial cyst in a dog. *JAVMA*. 194, No.1: 67-68.
- Coffman JR and Garner HE. (1972):** "Acute abdominal diseases of the horse." *J.A.V.M.A.*, 161(11): 1195-1198.
- Conroy JD (1983):** Canine skin tumors. *J. Am. Anim. Hosp. Assoc.* 19, 91.
- Corne HR, Lloyd LC and Carter HB (1963):** Squamous carcinoma associated with cysts of the skin in Marino sheep. *L. Path. Bact.* 86: 305-315
- Cowley F (1976):** Treatment of hematoma in the canine ear. *Vet Med Small Anim. Clin* 71, 283.
- Crocker CB and Rings DM (1998):** Lymphosarcoma of the frontal sinus and nasal passage in a cow. *J.A.V.M.A.* 213(10) 1472-1474.
- Cyriax J and Troiser O (1953):** Hydrocortisone and soft tissue lesions, *Brit. M. J.* 1: 966-968.
- Damodaran S and Parthasarathy KR (1972):** Neoplasms of goats and sheep. *Indian Vet. J.* 49, 649-652.
- Daneji AI, Djang KF and Ogunsan EA (1996):** Actinobacillus lignieresii infection in camels on the Sokoto plains, Nigeria. *Trop. Anim. Hlh. Production* 28: 4, 315-316.
- Das BK, Ojha SC and Mohanty J (1992):** Therapeutic approach of bursitis in cross bred cattle. *Indian. J. Vet. Surgery* 13, (2): 68-70.
- Das PK, Tripathy SB and Misra-SK (1975):** Studies on the patho anatomy of the skin stephanofilaria assamensis CPand (1936) infection in cattle *Indian J. Anim. Sci.* 45, (8): 543.
- Dawlat MA, Salem SA, Ahmed MH and Karim LA (1997):** Pathological and virological

- studies on bovine papillomatosis in cattle. *Egypt.J.Comp.Pathol. Clin.Path.*,10(1): 1-11.
- Dean PW, Bojrab MJ, and Constantinescu GM (1990):** Inguinal hernia repair in the dog. In *Current techniques in small animal surgery*. 3rd ed. Lea & Febiger, Philadelphia, U.S.A.pp 439-442.
- Dennis SM, and Leipold HW (1968):** Congenital hernias in sheep. *J.A.V.M.A.*, 152 (7): 999-1003.
- Diefenderfer DL and Brightling P (1983):** Dysuria due to urachal abscessiation in calves diagnosed by contrast urography. *The Canadian Vet.J.*,24(7):218-221.
- Dietz O and Wiesner E (1984):** Diseases of the horse. A hand book for science and practice part 2\1 S. Karger. Basel. Munchen. Paris.
- Dimock WW and Edward PR (1982):** Infections of fetuses and foals. *Vet. Bull.*52,9,1220-1223.
- Dingwall IS (1971):** Surgical management of abdominal trauma. *J.Am.Vet.Med. Ass.*, 159 (11): 1406-1413.
- Dioli and Stimmelmayer (1992):** In Skwartx, HJ and Dioli M.ed.The one –Humped camel in eastern Africa. A pictorial guide to diseases, health care and management. Verlag Josef margrave (scientific books). domesticated animals: General conserderations. *Am.J.Vet.Res.*,31(12): 1871-1879.
- Dorella FA, Pacheco LC, Oliveira SC, Miyoshi A and Azevedo V (2006):** *Corynebacterium Pseudotuberculosis*: Microbiology, biochemical properties, pathogenesis and molecular studies of virulence. *Vet. Res.*37:1-18.
- Edgar DG (1952):** *vet rec.*64, 852
- Eissa MA (1992):** Comparative anatomical studies on the ear in some domestic animals with special reference to ear surgery and affections Ph.D.Vet. Surgery, assiut Univ.
- El- Guindy M (1988):** Notes on regional surgery. Fac. Of Vet.Med.Assiut Univ. Assiut Egypt.
- El- Kanawaty ZA (1989):** Some studies on lumpy skin disease. Thesis M.V.Sc. Fac.Vet. Med. Zag. Univ. Benha- Branch.
- El- Sheikh MH (1996):** Studies on some surgical affection of newly born ruminants in Alexandria Province and its surroundings. A thesis for Ph.D.to Surgery Dept. Fac. of Vet. Med. Alex. Univ.
- El-Maghraby HM (1988):** studies on surgical affections of calves at Kaliobia Governorate. M.V.Sc. Thesis, Fac.Vet. Med. Zagazig Univ. Benha
- El-Maghraby HM (1996):** A retrospective study on cutaneous and subcutaneous neoplasms in equine. *Assiut Vet. Med.J.*36(71).
- El-Mezayen AF (1994):** Surgical management of certain udder affections in goats. *Zag.Vet.J.*22,4 pp.48-59.
- El-Mezayen AF And Bolbol AE (1993):** Perineal hernia in goats ( A report of four cases). *Zag.Vet.J.* Vol.21 No.5pp.920-925.
- El-Mezayen AF and Bolbol AE (1993):** Perineal hernia in goats (a report of four cases). *Zag.Vet.J.* 21 (5) pp.920-925.
- El-Seddawy FD and Abd- El- Aal AM (1996):** Surgical management of some neoplasms in sheep in Sharkia Province with special reference to cryosurgical approach.

- Zag. J.ISSN (1110-1458) 24 (1)pp9-12.
- El-Syad GA (1991):** Surgical studies on the common affections of the abdominal region in some farm animals. M.V.Sc.Fac.Vet.Alex. Univ.
- Elzein EE, Sundberg JP, Housawi FM, Gameel AA, Ramadan RO and Hassanein MM (1991):** Genital bovine papillomavirus infection in Saudi Arabia. J.Vet.Diagn. Invest.,3:36-38.
- Esplin GD (1983):** Skin tumors and other cutaneous masses. Mod. Vet. Pract. January.
- Esyutin AV, and Girin VA (1976):** Prevention and treatment of omphalitis in calves. Vet. Bull., 46,6 abst. 3454.
- Fadzil M (1977):** Stephanofilaria Kaeli infections in cattle in Penin Sular Malaysia Prevelence and treatment. Vet.Med.Review No.1: 44-52.
- Falade S and Smith (1985):** Caseous lymphadenitis of sheep in Iie Ife, Nigeria: Bull.Anim. Hlth Prod. Afr. 33,271.
- Farris HE (1980):** Veterinary Medicine . In Albin R.J. Handbook of Cryosurgery.
- Farghali HA (2007):** Oedematous skin disease in buffaloes ( Diagnosis and Surgical Approach). Ph.D.Thesis, Fac. Vet. Med. Cairo Univ. Egypt.
- Formston C (1953):** Fibropapillomatosis in cattle with special reference to external genitalia of the bull.Br. Vet.J., 109, 244..
- Fouad K , Saleh M, Khamis Y, Shouman T and Fahmy L (1974):** Oedematous Skin Disease in buffaloes and cattle. J.Egypt. Vet. Med. Ass., 34,154-170.
- Fouad K, Gohar H, Sheta EM, El- Mahdy M and Abu-Seida (2001):** Dermoid cysts in camels. J.Egypt Vet.Med.Assoc. 61,6:255-260.
- Fouad K, Misk NA and Kassem M (1984):** Studies on certain skin affections among ruminants. Assuit Vet. Med. J. 11,(22) : 182-187.
- Fouad K, Saleh M, and Shokry M (1985):** Current Concepts in veterinary surgery. Giza, Egypt, Cairo Univ.Press.
- Fox MW (1963):** Inherited inguinal hernia and medline defects in the dog. J.A.V.M.A., 143 (1): 602-604.
- Fox SM and Woody BJ (1986):** Surgical repair and management of disorders of the pinna.Vet Med 81,626.
- Frank ER (1964):** veterinary surgery 7th ed. Burgess publishing co. Minnestots U.S.A.
- Frank ER (1981):** Vetrinary surgery 1st Indian ed. C.B.S. Publishers, Distrbutors, New Delhi, India.
- Freeman DE and Spencer PA (1991):** Evaluation of age, breed, and gender as risk factors for umbilical hernia in horses of a hospital population. Am. J. Vet.Res., 52(4):637-639.
- Frenz L (1941):** Auagedehnte papillomatosis in einem junrinderbestand. Dentche Tierarztl. Wchnsche, 49,158
- Fretz PB, Hamilton GF, Barber SM, and Freguson JC (1983):** Management of umbilical hernias in cattle and horses. J.A.V.M.A., 183(5):550-552.
- Furieux RW(1975):** Management of contaminated wounds Canine Pract.2,22.
- Gab-allah MS and Farghaly SI (1991):** Surgical and pathological studies on some skin tumours in donkeys at Kalubia province. Zag. Vet.J.Vol..19, No.2.
- Geishauser T and Grunder II (1992):** Nebelentzundung beim Kalb-Ein. Ruck blick auf 104 falle. Tierarztl.Umscau, 47,304-320.
- Gibbs EBJ, Smale CJ and Lawman MJP (1975):** Warts in sheep. J.Comp.Path.,85:327-

334.

- Gohar HM, Ramadan RO and Moghal H (1987):** Umbilical and abdominal hernias in ruminants. " J.Egypt. Vet. Med. Ass., 47(1&2): 563-574.
- Grant DA (1996):** Udder oedema in ewes. The veterinary record;17:168.
- Green FH (1954) :** Lumpy skin disease. Its effect on hides and leather. Bull. Epiz. Dis. Afr. 7:63.
- Greenough PK, MacCollum FJ and Weaver AD (1981):** Lameness in cattle. John Wright & Sons Ltd, 42-44. Traingle West, Bristol, England.
- Greenough PR (1988):** Skin, Hoof, Clow, and appendages. Text book of large animal surgery by Oehme, F.W., 2nd ed. Baltimore, Williams and Wilkins, Hong Kong, London Sydney ,p. 154-220.
- Greenough PR and Johnson L(1988):** The intugumentary system. In Oehme , FW (ed): Textbook of large animal surgery. Williams and Wilkins, Baltimore, Hongkong, London, Sydney.
- Guedes RC, Filho EF and Lago LA (1998):** Mandibular lymphosarcoma in a goat. Vet. Rec. 143,51-52.
- Gupta RKP, Sadana JR, Kuchroo VK and Kalra DS (1980):** Horn cancer in an intact bull. Vet.Rec., 105:312.
- Hafez AM, Tawfik AM Shaker HM and El-Danaf NA (1992):** Clinical and Pathological studies on lumpy skin disease firstly recorded in Egypt. Bull. Anim. Prod. Afr. 40: 225-233.
- Halit HOz, Williams MD and Memon MA (1985):** Epidermal inclusion Cysts in a cow. J.Amr.Vet.Med.Asso.187(5):504-505.
- Hall HB (1977):** Lumpy skine disease. Diseases and Parasites of livestock. In the tropics 2nd ed. Veterinary School, Vorn, Nigeria.
- Hamir AN and Parry OB (1980):** An abattoir study of bovine neoplasms with particular reference to ocular squamous cell carcinoma in Canada. Vet. Rec., 106: 551-553.
- Hamoda FK (1996):** some studies on oedematous skin disease. J.Egypt.Vet. Med. Ass. 26(2):213-231.
- Hanson PD and Lindsay WA. (1992):** Correcting an acquired indirect inguinal hernia in a wealing clot. Vet.Med., 87(2): 150-154.
- Harvey J (1976):**General principles of veterinary oncology surgery. J.Am.Anim.Hosp. Assoc.12,33.
- Hayes HM (1974) :** Congenital umbilical and inguinal hernias in cattle, horses, swine, dogs, and cats: Risk by breed and sex among hospital patients. Am. J. Vet. Res., 35(6): 839-842.
- Hayward MR, Baird PJ and Meischke HC (1993):** Filiform viral squamous papillomas on sheep. Vet.Rec.,132:86-88.
- Hegazy A, Khamis Y, Fahmy L and Omer M (1982):** further studies on the buffaloe teat. Part II-acquired affection. Assuit Vet. Med.J., Vol. 10,No.19.
- Heidrich HJ (1968):** Teat Fistula. Vet. Encyclopedia.3,1476.
- Heinze CD, Bullard JF, Johonson LE (1972):** Hernias , In : Catcott EJ, Smithcors JF.(eds): Equine Medicine and surgery. 2nd ed. Am. Vet. Publ. Inc., Santa Barbara Calif,pp 468-862.
- Helmy N , Fouad K ,Khamis Y ,and Hosny Z (1970):** Special seats of bursitis in

- buffaloes . Egypt. Vet. Med. J. Cairo Univ. Vol. XV11.No.18, 64-80.
- Hoffer RE and Jensen HE (1973):** Stereoscopic atlas of Small Animal Surgery. Saint Louis, The C.V. Mosby Company.
- Hollander JL, Brown EM, Jesser RA, and Brown CY (1951):** Hydrocortisone and cortisone injected into arthritic joints. Comparative effect of the use of hydrocortisone as a local anti-arthritic agent. J.A.V.M.A. 147: 1629-1635
- Honnans CM, Schumacher J, McClure SR, Carbill MR, Carter GK, Schmitz DG, and Hofman AG (1995):** Treatment of olecranon bursitis in horses : 10 cases (1986-1993) . J.Am.Vet. Med. Asso. 206,(7) : 1022- 1026.
- Horne RD and Henderson RA (1993):** The pinna In Slatter, D.H. Textbook of small animal surgery. 2nd . ed. W.B. saunders, Philadelphia, 1545-1559.
- Horney FD, Wallace CW (1984):** The practice of large animal surgery, Vol.1.Jennings (ed). W.B.Saunders Co., Pheladelphia, U.S.A
- Hylton WE, and Rousseaux CG (1985):** Intestinal strangulation associated with omphaloarthritis in a calf. J.A.V.M.A., 186(7): 1099.
- Ibrahim MS, Awad YL, Elbalkemy EA and Shoban IA (1983):** Some studies on the so called oedematous skin disease in buffaloes. Zag. Vet. J., Zagazig Univ., Egypt. 4, 35-50.
- Ingle-Fehr JE, and Baxter GM (1999):** Endoscopy of the calcaneal bursa in horses. Vet.Bull.Vol.69 no.5.
- Ingle-Fehr JE, and Baxter GM (1999):** Endoscopy of the calcaneal bursa in horses. Vet.Bull.Vol.69 no.5.
- Ishihara K, Sasuki Y, Tagawa H (1982):** occurrence of cutaneous hemorrhagic parafilaria in cattle. J. Pr. J.Vet. Sci. 44(4): 669-673.
- Ishihara K, Sasuki Y, Tagawa H (1982):** occurrence of cutaneous hemorrhagic parafilaria in cattle. J. Pr. J.Vet. Sci. 44(4): 669-673.
- Ismail M,Ezzat M, El- Jakee J, El-Sayed Z and Abdel-Rahman M (1990):**Micro-organisms associated with closed abscesses of camels in Egypt. Vet.Med.J.Giza, 38(1):53-62.
- Ismail M,Ezzat M, El- Jakee J, El-Sayed Z and Abdel-Rahman M (1990):**Micro-organisms associated with closed abscesses of camels in Egypt. Vet.Med.J.Giza, 38(1):53-62.
- Ismail SA (1999):** Surgical studies on the swellings of the head and neck in some farm animals.Thesis Ph.D.Vet.Surgery. Fac.Vet.Med. Alex.Univ.
- Ismail SF (1990):** The clinical symptoms and complications of lumpy skin disease. The 4th Scientific Congrss, Assiut Univ. Proceeding, 2: 379-382.
- Ismail SF (1993):** Ocular dermoids in some farm animals. Assiut Vet. Med. J.29 (59): 212-216.
- Ismail SF( 1997):** Differential diagnosis of some swellings at the head and neck regions in some farm animals. Assiut Vet. Med. J. Vol. 38 No 75, October..
- Jackson RS. (1972):** Equine Medecine and surgery. Am. Vet.Publ. Inc., Santa Barbara, Calif
- Hylton WE, and Rousseaux CG (1985):** Intestinal strangulation associated with omphaloarthritis in a calf. J.A.V.M.A., 186(7): 1099.
- Jackson RS. (1972):** Equine Medecine and surgery. Am. Vet.Publ. Inc., Santa Barbara, Calif, U. S.A.,p649.
- Jennings JR. (1984):** The practice of large animal surgery. W.B.Saunders company,

- Philadelphia, U.S.A.
- Johnson JE, Beech J and Salk JR (1988)** : J.A.V.M.A. 193,1429.
- Johnston DE (1975)**: Hygroma of the Elbow in dogs . J.Am. Vet. Med. Asso. 167, (3) : 213-219.
- Jones TC and Hunt RD (1983)**: Veterinary pathology. 5th ed. Lea & Febiger, Philadelphia , U.S.A.
- Jones TC, Hunt RD and King NW (1997)**: Veterinary pathology, 6th ed., Williams and Wilkins, Pennsylvania.
- Joyce JR (1976)**: Cryosurgical treatment of tumours of horses and cattle. J.A.V.M.A.,168,no.3.226-229.
- Jubb KF and Kenedy PC (1970)** : Pathology of domestic animals. 2nd ed. (2), Academic press, NY., 173.
- Jubb KF and Kennedy PC (1963)**: Pathology of domestic animals. Academic Press, New York, p86.
- Jubb.KF, Kennedy PC and Palmer N (1985)**: Pathology of domestic animals 3rd edition Vol.2 Academic press Inc. ( Harcourt Brace Jovanovich Publishers) orland san Deigo New York London Toronto Monteral Sydney. Tokyo.
- Kahrs RF (1981)**: Lumpy skin disease. Viral disease of cattle. 1st ed. Printed by the Iowa state Univ. Press, Ames. Iowa. 50010 pp 263-268.
- Kaneps AG (1992)**:Hernias, In :Auer, J.A (ed):Equine Surgery. W.B Saunders. Co., Philadelphia, U.S.A,pp 415-422.
- Karram MH (1985)**: Some clinical studies on bovine papillomatosis. Assiut Vet.Med.J.14(28):124-129.
- Kassem MM (1980)**:Studies on surgical affections of the skin in domestic animals in Egypt. M.V.Sc. thesis Fac. Vet. Med., Alexandria Univ.
- Kassem MM, Kenawy AA, Nouh SR, Hassieb MM,Biyomi AE and El-Sawk AA (1992)**: Study on some surgical affections in camels (Camelus dromedarius). Assiut Vet. Med. J., 26(52):171-180.
- Kelly WR (1974)**: veterinary clinical diagnosis 2nd ED. Bailliere tindal, London.
- Kenawy AA (1988)**:Prevalent surgical affections of newly born farm animals with special reference to their treatment. Ph.D.degree Fac.Vet. Med. Alex.Univ.
- Khamis MY(1979)**: A study of umbilical cord inflammation in calves 4th Arab. Vet. Med. Congress.Cairo, 39: 193-197.
- Khamis Y , Helmy N and Fahmy L (1973)**: Filariasis in buffaloes and cattle. Vet. Med. Review, No.4, 305-318.
- Khater AR, Deeb S, SalemH,, Bayomi AH, and Taha MM (1983)**: Studies on the experimental infection with corynebacterium pseudotuberculosis(ovis) pathological changes. In buffaloes calves. Assuit Vet. Med. J. 10, 200: 47-53.
- Koch SA and Cowles RR (1971)**: Surgical removal of a squamous cell carcinoma of the equine eye. VM/SAC:327.
- Kraus Hk (1990)**: Umbilical hernia. Current techniques in small animal surgery. 3rd ed. Lea & Febiger, Philadelphia, U.S.A.,pp 348-349.
- Laing EJ(1988)**: Skin tumors. In Binnnington A.G and Cockshutt JR. decision making in small animal soft tissue surgery.B C Decker Inc Toronto, Philadelphia.
- Levine SH and Caywood DD (1985)**: Surgical therapy of oncology. In Slatter DH. Textbook of small animal surgery. WB Saunders company. Philadelphia, 2381.

## References

- Livesey MA (1990):** Inguinal hernia. In :N.A.White; J.N.Moore(eds):Current practice of equine surgery. J.B. Lippincott, Philadelphia, pp 321-327.
- Lloyed S (1994):** Caseous lymphadenitis in sheep and goats. In practice, January in bulls. Vet. Rec., 90: 15-16.
- Loomis WK (1967):** A ventral hernia with intestinal incarceration in The horse. Cornell Vet., 57(1): 119-122.
- Mair T, Love S, Schumacher J and Watson E ( 1998):** Equine Medicine surgery and reproduction. WB Saunders Company LTD London Philadelphia Tokyo. 272-274.
- Makady FM , Aly MA and Youssef HA (1986):** Congenital dermoid cyst in male camel. Assiut Vet. Med.J. 17(33): 245-246.
- Makady FM, Mahmoud AZ, Youssef HA and Saleh NH.(1990):** Some observations on goat tumours: 1- Cutaneous papillomas on the udder. 2- Vaginal cystic fibroadenoma. Assiut Vet. Med.J.,23(46) : 213-218.
- Manning TO and Scott DW (1985):** Caprine dermatology . part III ,parasitic , Allergic, Hormonal and Neoplastic disorders. Compend cont. Educ. Pract.Vet. 7, 437-451.
- Mansman RA and Mcallister ES (1982):** Equine Medicine and surgery. 3rd ed., Am. Vet. Publ., Santa Barbara, Calif. U.S.A.
- Markel MD, Pascoe JR. and Sams AE (1987):**Strangulated umbilical hernias in horses:13 cases (1974-1985). J.A.V.M.A.,189 (12) :1591-1595.
- Marlene SS (1988):** Bilateral inguinal hernia in a foal. J.A.V.M.A., 192 (12):1668.
- Matthews JG (1992):** Outline of Clinical Diagnosis in the Goat, London Wright.
- McKeown GH (1974):** (eds): Cited by Oehme & Prier (1974): In text book of large animal surgery. The Williams and Wilkins Co. Baltimore, London.
- Mclean JW and Claxton JH (1960):** N.Z.vet.J.8.
- Meagher DM. (1974):** Surgery of the small intestine in the horse. Arch. Am. Colt. Vet. Surg., 3:3-14
- Megavin MD, Carlton WW and Zachary JF (2001):** Thomson special veterinary pathology. Mosby London Philadelphia Sydney. 588-594.
- Mellwraith CW (1987):** Diseases of joints, tendons, ligaments, and related structures. In Stashak, T.S., Adams, Lamness in horses. 4th ed. Lea & Febiger. Philadelphia 481-485.
- Mellwraith CW and Trotter GW. (1996):** Joints diseases in horses. W.B. Saunders Company , Philadelphia. London.
- Meyer DJ and Frankspot (1986):** Cytologic characteristics of tumors. Mod.Vet.Pract.May.
- Michell B (1996):** Oedema in cattle- causes and clinical implications In practice., May 18,(5).
- Misk NA (1982):** Ventro-abdominal hernia in der Hobe des penis bei einem Esel (Kurzbericht). Veterinar-Medizinische Nachrichten, 1:89-90.
- Misk NA, Ahmed IH, Ismail SF and Bayoumi AH (1994):** Branchial cysts in buffaloe calves. Agri. Practice., Vol.15, no.1.
- Misk NA, El- Guindy MH and Makady FA (1984) :** Venous diverticulum at the intermandibular space in adonkey. Eq. pract. Vol.6,no. 9. p,31-
- Misk NA, Nigam JM and Rifat JE (1984):** Surgical management of squamous cell carcinoma and papillomatosis in cattle and sheep. Vet.Med. Rev.2/84, 144:153.

- Misk NA, Nigam JM and Rifat JF (1985):** Unusual foreign body abscesses in the inter mandibular space and pharyngeal region in cows ( case report). Assiut.Vet.Med.J.Vol.14,No.27.
- Misk NA, Yossef HA and Ali MA (1986):** Ventral abdominal hernia at the level of the udder in a goat. Vet.Med.Rev., 2:200-202
- Misk NA, Semieka MA, Ahmed AF and Misk TN (2005):** Atlas of veterinary surgery ( Digestive system) Fac.of Vet. Med. Assiut Univ. Egypt.
- Mohamed MT (1988):** Surgical affections among fattening animals. M.V.C. Fac. Of Vet. Zagazig Univ.
- Moulton JE (1954):** Cutaneous papillomatosis on the udder of milk goats.
- Moulton JE (1978):** Tumors in domestic animals. 2nd ed. Berkeley Univ. of California press, pp: 227.
- Mountux WS (1975):** Lumpy skin disease In Forein animal diseases, their diagnosis and control. Richmond, Va.: U.S. An. Hth. Asso.pp. 173-184. Cited by Kahrs, (1981).
- Mountux WS (1975) :** Lumpy skin disease in Foregein animal diseases, Their diagnosis and control. Richmond, Va,: U.S. Animal health Asso., P.P. 173-184.Cited by Kahrs, (1981).
- Moustafa MI,Soliman IA, Abdel-Tawab M and Ali AA (1989):** Clinical observations on some cutaneous neoplasms in buffaloes. Zagazig Vet.J.,17(1):160-171.
- Mostafa ME (1984):** Studies on the so- called oedematous skin disease.M.D. Thesis,Zag.University, Egypt.
- Mouwen MM and De Groot EM (1982):** A color atlas of veterinary pathology. Medical Publications Ltd.
- Muller GH, Krik RW and Scott DW (1989) :** small animal dermatology. 4th ed. W.B. Saunders Company, Philadelphia.
- Munroe GA (1986):** Cryosurgery in the horse. Equine Vet J. 18,14
- Munz E (1992):** In Schwartz HJ.and Dioli M.ed. The one -humped camel in eastern Africa. A pictorial guide to diseasea, health care and management. Verlag Josef margrave (Scientific books).
- Mwangi Nguhiu JA, Munyua SM, Mbithi PF, Mbiuki SM, and Mogoia EM (1991):** How to improve the prognosis of ventral abdominal hernias in large animals Modified overlapping technique. Bull.Anim.Prod.Afr.,39:315-320.
- Nassef MT, Makady F and Taha MM (1986):** Peri-anal fibropapilloma in a Friesian cow. Assiut Vet. Med. J.15(30): 257-258.
- Nawal G, Khalel, Seddek SR and Nashed SM (1995):** Studies on ulcerative lymphangitis in buffaloes in Assiut. Assiut Vet. Med. J.,33, 93-99.
- Nayak SN, Bose VC, Ray AK, Mitra AK and Mohapatra HK (1990):** Soft fibroma in the oral cavity of a cow. Ind.Vet.j.,67:160.
- Neunzig GJ (1983):** A modified surgical procedure for treating canine and feline aural hematoma. Vet Ned Small Anim Clin 78, 927.
- Newton CD, Wilson GP, Allen HL.and Swenberg JA (1974):** Surgical closure of elbow hygroma in the dog. J.A.V.M.A. 164,(2): 147-149.
- Nguhiu- Mowngi JA, Gathumbi PK, Kihurani DO, Mbithi PF and Mbiuki SM (1989):** Atypical cutaneous) actinobacillosis in cattle : clinical observation, diagnosis and treatment in eighteen cases. 1st. Ann.Sci. Confe. Fac. Vet.Med.Nairobi,



## References

### References

- Univ., 119-121.
- Nguhiu- Mowngi JA, Mbiuki SM, and Maina JN (1991):** Complications , management and prognosis of distal limb wounds in cattle. Bull. Ani. Hth. Prod. Africa. 39,(3): 299-305.
- Nieberle and Cohrs P. (1966):** Text book of the special pathological anatomy of domestic animals. 1st .Eng.ed., Pergamon Press Ltd, pp393-395.
- Nielson SW (1983):** Classification of tumors in dogs and cats. J.Am.Anim.Hosp.Assoc.19,13.
- Nigam JM, Misk NA and Rifat JF (1984):** Organized peritracheal hematoma in a cow . Agri.Practice.Bovine Med. Vol.5, No. 9.p.40.
- Nobel TA, Klopfer U , Perl S and Nyska A (1979):** Neoplasms of domestic mammals in Israel. 1969-1979. Isr.J.Vet.Med.36,23-26.
- Nooruddin M, Singh KB and Nouriyal DC (1989):** Cutaneous papillomatosis (warts) in buffaloes. Buffalo Bulletin ,8 (2): 37-39.
- O' connor JJ (1985):** Dollar's veterinary surgery . 3rd Ind.ed. CBS. Publishers and distributors, Delhi, India.
- O'Connor JJ (1950):**Dollar's Veterinary Surgery. 4th ed. Bailliere, Tindall and Cox, London,pp667-683.
- O'connor JJ (1955):** Dollar's Vetrinary surgery. 4th ed ., Bailliere, Tindall and Cox, London.
- O'connor JJ(1983):** Dollars. Vet surgery. 4th ed. Bailliere Tindall, London.
- O'Doherty S, Prendergast M, Scanlon M, Schofield WL, Doherty ML, Frame M and Bassett HF (2000):** Corynebacterium pseudotuberculosis infection in an imported ewe. Irish Veterinary Journal, 53: 631-634.
- Oehme FW (1988):**Text book of large animal surgery 2nd ed. Kansas State Univ. , Monhattan, Kansas U.S.A.
- Oehme FW and Prier YE (1974):** Text book of large animal surgery. The Wiliams and Walkins Co. Baltimore U.S.A.
- Olson C and Skidmore LV (1959):** Therapy of experimentally produced bovine cutaneous papillomatosis with vaccine and excision. J.Am.Vet.Med.Assoc., 135: 339-343.
- Olson C, Olson RO and Hubbard Vanstelle S (1992):** Variations of response of cattle to experimentally induced viral papillomatosis. J.Am.Vet.Med.Assoc., 201(1): 56-62.
- Olson C, Robl MG and Larson LL (1968):** Cutaneous and penile bovine fibropapillomatosis and its control. J.Am.Vet.Med.Assoc.,153(9):1189-1194.
- Olson RO, Olson C and Easterday BC (1982):** Papillomatosis of bovine teats (Mammary papilla). Am.J.Vet.Res.,43(12): 2250-2252.
- Omar MA (1973):** Surgical affections of the buffalo udder. Thesis, M.V.Sc. (surgery) Fac. Of Vet. Med.Cairo Univ.
- Othman GM, Ismail SF and Obead AS (1991):**Teath affections in Equine. Assiut Vet.Med.J. Vol.25,No. 50, 193-199.
- Othman GM, Samy MT, Hatem HE and Saleh SM (1984):** Surgical and microbiological management of the neonatal navel infection in freisian calves in Egypt. J. Vet.Med.Assoc., 12 (24): 209- 215.
- Oz HH, Foil CS, Memon MA, Al-Bagdadi FK, Turk MM. And Sims D.(1985):**

- Follicular cysts in sheep. J.Am.Vet.Med.Assoc., 187(5): 502-503.
- Ozaydin I, Kilic E, Ozba B and Cihan M (1999)** : A new technique for the operative treatment of umbilical lesions in bull calves. Vet. Bulletin 69,11, 7845.
- Parish SM (1979)** : A method for nonsurgical correction of rectal prolapse in lambs. Vet. Med. Small Anim. Clin.74 (6),871:872. Cited by Al-Ani (1989).
- Pascoe RR and Summers PM (1981)**: clinical survey of tumors and tumors- like lesions in horses in South East Queensland. Eq. Vet. J. 13, 235-239.
- Pavletic MM (1985)**: the integument. In slatter D.H. text book of small animal surgery. W.B. Saunders, Philadelphia , 420.
- Pavletic MM.(1985)**: Skin and adenxa. In Slatter DH. Ed. Textbook of small animal surgery , 1st ed. W.B.Saunders, Philadelphia , 420-533.
- Plakhotin MV (1981)**: General Veterinary Surgery . Mir Publisher , 1984.
- Plakhotin MV (1984)**:General Vet.Surgery Mir Publishers Moscow.p.292.
- Priester WA, Glass AG, and Waggoner NS (1970)**: Congenital defects in
- Pully LT and Standard AA (1990)**: Tumors of the skin and soft tissue. In: Tumors in domestic animals 3rd ed. Pp.23-87. Editor: Coulton, JE. Univ.of California Press. Berkely.
- Purchase HS (1944)**: Oedematous Skin Disease of buffaloes. J.Comp. Path. Therap. 54,238.
- Purohit NR , Chouhan DS, Dudi PR and Vyas UK.(1989)**: Dermoid cysts in camels. Br.Vet.J.,145: 89-90..
- Purohit NR, Chouhan, DS and Choudhary RJ (1989)**:Postcasesarean ventral hernia in two camels. Br. Vet. J., 145 (3):249.
- Radostits OM, Blood DC and Gay CC.(1994)**: Veterinary Med. 8th ed. Bailliere Tindall, London .
- Ramadan RO (1975)**: Squamous cell carcinoma of the perineum of the goats. Brit.Vet. J. 113, 347-350.
- Ramadan RO (1994)**: Syrgery and radiology of the dromedary camel. 1st ed.,Aljawad printing press ( Kingdom of Saudi Arabia).
- Ramadan RO and El- Hassan AM (1987)**: Tumors and tumor- like lesions in the humped camel (Camelus dromedarius ). Tenth Symposium on The Biological Aspects of Saudi Arabia, 242.
- Ramadan RO, Gameel AA and El- Hassan AM. (1991)**: Squamous cell carcinoma in sheep in Saudi Arabia. Revue Elev. Med.Vet. Pays Trop., 44(1): 45-51.
- Ramadan RO, Hashim NH and Bukhari AE(2007)**: carpal hygromas in sheep.NET.
- Rebhun WC, Payne RM, King JM, Marilyn W and Begg SN (1980)**: Interdigital papillomatosis in dairy cattle.J.A.V.M.A.,177(5):437-440.
- Roberts SJ (1980)**: Vet. Obstetric and genital diseases.3rd ed. Published by the auther, Ithaca, N.Y.
- Robinson R (1977)**: Genetic aspects of umbilical hernia incidence in cats and dogs. Vet.Rec.,100(1):9-10.
- Roony JR and Robertson JL (1996)**: Equine pathology. Iowa state Univ.press/AMES. 302-307.
- Rose WR (1977)**: Ulcers and abscesses.VM/SAC, 73,3,277-280.
- Runnel RA, Monlux WS and Monlux AW(1976)**: Principles of veterinary pathology. 7th ed. Iowa. State univ.press, U.S.A. pp 875-931.

- Saleh MS and Khamis MY (1971):** Clinical studies on buffalo teat. *Vet. Med. J.*, Giza, 19, 157-168.
- Samy MT and Kadri M (1986):** Fibropapilloma in a heifer teat (clinical report). *Vet. Med. Review*, 1:93-96.
- Saraha AB (1997):** Skine surgery in animals . for Ph. D. of Vet. Med. Sci. Zagazig Univ.
- Sastary GA (1959):** Neoplasms in animals in India. An account of neoplasms collected in 12 years. *Vet. Med.* 54, 428-430.
- Schneider RK, Milne DW, Kohn CW (1982):** Acquired inguinal hernia in the horse: A review of 27 cases. *J.A.V.M.A.*, 180(3): 317-320.
- Scott DW (1988):** Large animal dermatology. 1st ed., W.B. Saunders Company.
- Semieka M, and Mubarak M (2002):** Prevalent external neoplasms in donkeys and cattle. *Assiut Vet. Med. J.* 48(95):116-138.
- Senna NA (1994) :** Studies on the umbilical affections in calves. PH.D, Thesis, Fac. Vet. Med. Cairo Univ.
- Shaaban IA, Ibrahim MS, Awad YL and El-Bulkeny FA (1986):** complementary studies on lymphangitis in buffaloes. *Alex. J. Vet. Sci.* 2 (1): 419.
- Shabaan LA, Kadri M, Moursi A and Kamel A (1981):** Surgical and pathological studies on some skin tumours of donkeys (*Equus A sinus* ). *J. of Eg. Vet. Med. Assoc.*
- Shearer AG (1986):** Internal naval abscesses in calves. *Vet. Rec.* 118, 480-481.
- Shoukry M, El-Keiey M, Hamouda M and Gadallah S (1997):** Commercial polyester fabric repair of abdominal hernias and defects. *Vet. Rec.* 140 (23) 606-607.
- Sigler TA (1943):** Scrotal and inguinal hernia. *J.A.V.M.A.*, 102:117-118
- Silva LF, Fioravanti MS, Eurides D , Juliano RS, Acypreste CS and Borges GT (1999):** Abdominal aponeurosis overlaying in the repair of bovine umbilical hernia. *Vet. Bulletin* 69,10.7054.
- Sinclair J (1999):** New students dictionary. Univ. of Bermingham. Hasper Collins publishers.
- Singh B and Riger PR (1972):** Manning intraductal carcinoma in goats (*Capra hircus*) *Vet. Path.* 9, 441-446.
- Smart ME, Frequson JG, and Vaillancourt D (1978):** Sequela to urachal abscess in a Hereford heifer. *VM & Sac*, 73, 2, 1447-1558.
- Smith HA, Jones TC and Hunt RD (1974):** Veterinary pathology 4th ed. Lea & Febiger. Philadelphia.
- Smith MC.(1981):** Caprine dermatologic problems: A review. *J. Am. Vet. Med. Assoc.*, 178 : 724 - 729.
- Soliman HA (1999):** comparative clinicopathological studies on some skin affections for the degree of Ph.D.of Vet. Med. Science Vet. Clin. Dep. Zag. Univ.
- Soliman IA, EL-Shair MA and Abd-ELtawab M (1988):** surgical management of some foot problems in beef buffaloe calves. *Zag. Vet. J.* 16, 14: 236- 246.
- Soliman KN and Iskander M (1963):** Infectious bovine papillomatosis with special reference to its treatment with tissue vaccine . *Proc. Of the 4th. Arab. Annual Vet. Cong.*, 429-439.
- Soliman KN, Agamy FA and Sayour EM (1963):** Ulcerative lymphangitis in buffaloes and cattle in Egypt . U.A.R. (Edematous skin disease of the buffaloes ) 4th Ann. Arab. Vet. Cong. 283-295.
- Somvanshf R , KoulGL, Sharma B and Biswar JC (1986):** Clinico-pathological

## References

- observation on cutaneous bovine papillomatosis. *Ind. J. Anim. Sci.*, 56(8): 836-840.
- Spurlock GH, and Robertson JT (1988):** Congenital inguinal hernias associated with a rent in the common vaginal tunic in five foals. *J.A.V.M.A.*, 193(9): 1087-1088.
- Sra IS, Chouhan DS, Sharma GD, Arya PL and Vyas UK (1982):** Note on myxofibroma in camel. *Ind. J. Anim. Sci.*, 52(11): 1150-1151.
- Ssenyomga GZ, Onapito JS, Nakasola –Situma J and Omara-Opyene AL (1990):** Therapeutic value of partial excision of lesions combined with administration of an autogenous vaccine during an episode of cutaneous papillomatosis in cattle of Uganda. *J. Am. Vet. Med. Assoc.*, 197(6): 739-740.
- Stear JH., Moody KM. and Nealy J (1960):** Open teat sinus surgery. *J.A.V.M.A.*, 136:123-127.
- Strafuss AC (1976):** Sebaceous gland carcinoma in dogs. *J.A.V.M.A.* 169,325
- Strafuss AC (1985):** Skin tumors. *Vet. Clin-North Am. Small Anim. Pract.* 15, 473.
- Suillivan BM (1981):** Brucella abortus titres and bursitis in the horse. *Aust. Vet. J.* 57(2):103-104.
- Sullivan BM (1981):** brucella abortus titres and bursitis in the horse. *AUST. Vet. J.* 57, 920; 103-104.
- Swaim SF and Henderson RA (1990):** Small animal wound management. Lea & Febiger, Philadelphia.
- Tadayon RA, Cheema AH and Muhammed SI (1980):** Microorganisms associated with abscesses of sheep and goats in the South of Iran. *Am. J. Res.*, 41(5):798-802.
- Tageldin MH Omer fA (1986):** A note on squamous cell carcinoma in a camel. *Ind. Vet. J.* 63:504.
- Tennant B, Wheat JD and Meagher DM (1972):** Observation on the causes and incidence of acute intestinal obstruction in the horse. *Proc. 18th Annu. Conv., Am. Assoc. Equine Pract.* 251-257. The English Language Book Society and Baillere Tindall
- Theilen G, Wheeldon, EB, East N, Madwell B, Lancaster WD and Munn R (1985):** Goat papillomatosis. *Am. J. Vet. Res.*, 46(12): 2519-2525.
- Theilen GH and Madwell BR (1979):** *Veterinary cancer medicine*. Lea & Febiger. Philadelphia.
- Tirgari M. (1980):** Ventral hernia in the sheep. *Vet. Rec.*, 106(1):7-9.
- Tulleners EP and Donawick EJ (1983):** Secondary closure of infected abdominal incisions in cattle and horses. *J.A.V.M.A.*, 182(12): 1377.
- Tulleners EP and Fretz PB (1983):** Prosthetic repair of large abdominal wall defects in horses and food animals. *J.A.V.M.A.*, 182(3): 258-262.
- Turner TA, and Fessler JF (1980):** Rectal prolapse in the horse. *J.A.V.M.A.*, 177,(10), 1028-1032.
- Twafik AM (1990):** Pathological studies of Odematous skin disease. *Egypt. J. Comp. Path. Clin. Path.*, 3(1): 1-9.
- Tyagi RS and Sing (1996):** *Ruminant surgery*. 1st ed. CBS. Publisher and distributors, Delhi, India. 223.
- Van der Velden MA (1988):** Surgical treatment of a cquired inguinal hernia in the horse: A review of 51 cases. *Equine. Vet. J.* 20(3): 173-177.
- Van pelt RW (1963):** Clinical and synovial fluid response to intrasynovial injection of 6-

- alpha- methyl prednisolone acetate into horses and cattle. J.A.V.M.A. 143, 738-788.
- Van pelt RW and Conner GH (1963):** synovial fluid from the normal bovine tarsus. B. relative viscosity and quality of mucopoly Saccharides. Amer. J.Vet.Res. 24: 527-544.
- Van pelt RW and Riley WJ (1968):** Trumatic subcutaneous calcaneal bursitis ( capped hock) in the horse. J.A.V.M.A. 153: 1176-1180.
- Vanselow BA, Spradbrow PB and Jackson AB (1982):** Papillomaviruses, papilloma and squamous cell carcinomas in sheep. Vet.Rec., 110:561.
- Vaughan JT (1972):** Surgical management of abdominal crisis in the horse. J.A.V.M.A., 161(11): 1199-1212.
- Vaughan JT (1974):** Male horse: Scrotal hernia, In Oehme & Prier(ed): Text book of large animal surgery. The Williams and Wilkins Co., Baltimore, London, pp1199-1212
- Vegad JL (1971):** Treatment of pedunculated warts in an indogenous Cattle by injection Antiomatine (Mayand Baker).J.F.K. V. V. Res. J.5(1): 64.
- Venkataswamy M and Ramakrishna O (1990) :** Cryosurgical treatment of ocular squamous cell carcinoma in cattle.Ind. Vet.J., 67:59-60.
- Venugopalan A (1982):** Essential veterinary surgery . 4th ed. Oxford & IBH publishing co.NewDelhi 278-285.
- Venugopalan A (1994):** Essential of veterinary surgery. 7th ed. Oxford & IBH Publishing Co. New Delhi.
- Vestweber JE and Al-Ani FK (1984):** Udder oedema: Biochemical studies in Holsien cattle. Cornell Vet.79:366-372.
- Vogel CJ (1996):** An illustrated Guide to veterinary care of the horse. Manson publishing, England.
- Vogt DW and Eilersieck MR (1990) :** Heritability of susceptibility to scrotal herniation in swine. Am.J.Vet.Res.,51(9): 1501-1503.
- Walker RG (1966):** Hernia. International Encyclopedia of Vet. Med.3: 1420-1424
- Wandera JG (1989):** Cancer in animals in Kenya.Emphasis on food animals and dogs proc.1st ann.Sci.Conf. Fac. Vet. Med., Nairobi Univ.91-100.
- Weaver AD (1986):** Teat surgery.Bovine surgery and lameness.141-149. Balckwell Scientific Publicaitions.
- Weiss KE (1963):** Lumpy skin disease In Emerging diseases of animals FAO Agric. Stud., 61: 179-201.
- Wheat JD (1975):** Causes of colic and types requiring surgical intervention. J.S.Afr.Vet.Assoc., 46 : 95-98.
- Williamson LH (2001):** Caseous lymphadenitis in small ruminants. Vet. Clin. North Am. Food Anim. Pract. 17:359-371.
- Wilson JW (1983):** treatment of auricular hematoma using a teat. Am.Vet.Med.Assoc. 182, 1081.
- Wintzer HJ (1962):** Methods for surgical treatment of bovine abdominal hernias.
- Withrow S (1975):** Surgical management of cancer. Am. Anim. Hosp Assoc Sci Proc 2,93.
- Wolfe DF, Baird AN(1993):** Female urogenital surgery in cattle .vet. clin.North Am Food Anim. Pract.9:369-388

## References

- Woodward RR and Queensberry JR (1956):** ( J.Anim.Sci. 15, 119.
- Wright JG (1963):** The surgery of inguinal canal in animals. Vet.Rec.,75(50): 1352-
- Yavru N, Alkan F, Koc B, Avki S, and Arican M (1999):** Large hernial defects fixed with skin autografts. Vet. Bulletin, 69,12,8651.
- Youngquist RS and Threlfall WR (2007):** text book of large animal theriogenology.2nd edition, by Saunders, an imprint of Elsevier Inc.U.S.A.
- Youssef AH (1984):** Prevalent surgical affections of the abdominal wall in farm animals with special reference to hernias.Ph.D.Thesis, Fac.Vet.Med.,Assiut Univ.,Egypt.
- Youssef HA (1992):** The use of antibiotics in camels. Proc. Of the 1st Int.Camel Conf., 385.
- Youssef HA (1993):** Management of some swellings in the head and neck regions in ruminant. Assiut Vet.Med. J. 29(57):215-226.
- Youssef HA , Ali MA and Saleh AS (1993):** Some surgical affections of the nictating membrane in cattle and sheep . Assiut Vet. Med. J.28(56):277-282.
- Youssef HA , El- Sebaie A, Taha MM and Makady F (1987):** Lymphosarcoma in a Dromedary. Vet. Med. Rev. 1: 68-71.
- Youssef HA, Makady FA and Ahmed IH (1991):** Branchial cyst in a buffaloe calf. Assiut Vet. Med. J. 26(56):226-229
- Zaghawa AA, and El-Gharib SA (1996):** An outbreak of oedematous skin disease in Alexandria during 1994: Clinical investigation and assessment of epidemiological parameters.7th Sci. Cong. 17-19 Nov., 1996, Fac. Vet. Med., Assiut, Egypt. 617-636.
- Zubaidy AJ (1976):** Caprine neoplasms in Iraq: case reports and review of the literature. Vet. Pathol.13,460-461.



## الملخص العربي

اجريت هذه الدراسة فى الفترة ما بين شهر ديسمبر ٢٠٠٥ حتى ديسمبر ٢٠٠٧ تهدف هذه الدراسة الى إلقاء الضوء على التورمات المرضية الخارجية الشائعة الظهور على سطح الجسم فى حيوانات المزرعة خصوصا من نظرة اكلينيكية أخذة فى الاعتبار أشكالها والتشخيص المقارن لها والطرق الجراحية الصحيحة ( المناسبة ) للتعامل معها .

سجلت الحالات من مواقع مختلفة بمحافظة كفر الشيخ مشتملة العيادات الخاصة وبعض مزارع الحيوانات وكذلك المستشفى البيطرى بكلية الطب البيطرى بادفينا – جامعة الاسكندرية عدد الحيوانات التى سجلت فى هذه الدراسة (١٨٣٠) حالة اصابة تشمل (١٠٣٦ من الأبقار ، ٤٢٧ من الجاموس ، ١٢٨ من الأغنام ، ٤٨ من الماعز ، ٨١ من الخيول ، ١١٠ من الحمير تم التدخل الجراحى لكل حاجة حسب نوع الإصابة وحجمها موقعها بالنسبة للجسم وانتشارها وتم التخدير بالطريقة التى تناسب كل حالة .

أورام الجلد سجلت فى ١٣٥ حيوان (٦٣) من الأبقار ( ٥٣ اناث + ١٠ ذكور) فى الجاموس (٣٣) حيوان ( ٢٤ اناث + ٩ ذكور ) ، ( ٩) خيول ( ٤ اناث + ٥ ذكور ) ، (١٥) حمار ( ٧ اناث + ٨ ذكور ) ، (٩) أغنام (٧ أنثى + ٢ ذكور ) ، ( ٥ ) ماعز ( ٤ اناث + ٢ ذكر) . - (٣٣) حالة كانت أصغر من عامين بينما (١٠٢) حالة كانت أكبر من عامين - بعد اجراء الفحص الهستوباثولوجى تبين أن الباميلوما سجلت أعلى نسبة من انواع سرطانات الجلد (٩٧) حيوان بنسبة (٧١,٩%) بينما سجلت (٢٤) حالة مصابة بالورم الليفى بنسبة (١٧,٨% ) كما سجلت (١٤) حالة مصابة بسرطان الخلايا الحرشفية بنسبة (١٠,٣%) - منطقة الرأس والرقبة كانت أكثر الأماكن اصابة بسرطان الجلد حيث تم تسجيل (٧٩) حالة اصابة بينما كانت منطقة الذيل الأقل اصابة حيث سجلت (٨) حالات اصابة فقط . - تم التدخل الجراحى بالطرق المختلفة حسب حجم ومكان الورم حيث تم اسئصال الأحجام الكبيرة جراحيا ثم تم استخدام الكى بالنار حيث لا تكون الخياطة متاحة . بينما تم الاستئصال والخياطة فى الأورام المتوسطة الحجم وفى الأحجام الصغيرة والتى لها عنق تم ربطها بخيط و تركها حيث سقطت بعد (١٥) يوم . - تم تسجيل (١٨٣) حالة مصابة بالخراريج فى الأبقار و(٧٢) حالة فى الجاموس ، (٦٠) حالة فى الأغنام ، (٣٦) حالة فى الماعز ، (٣٦) حالة فى الحمير ، (٢١) حالة فى الخيول . سجلت



منطقة الرأس والرقبة أعلى نسبة إصابة (١٦١) حالة ثم منطقة السرة (٨١) حالة ، منطقة الصدر والبطن (٥٩) حالة ، الأرجل (٦٩) حالة بينما سجلت خراجات الضرع (٣٨) حالة . الخراج الذى لم ينضج بعد تم دهانه بمزيج ١٠% من مرتين يوميا لعدة أيام حتى تم نضجه بينما الخراج الناضج تم فتحه من اسفل نقطة بعد تجهيز مكان الفتح . بالنسبة للخراج كبير الحجم تم عمل فحطان له ليسهل تنظيفه .

سجلت (١٣٨) حالة إتهاب الكيس الزلالي ( Bursitis ) ، (٥) حالات فى الإبقار إتهاب الكيس الزلالي أمام عظمة القص ( Presternal Bursitis ) (١٢٥) حالة فى الجاموس (٦٩) حالة منهم كانت فى منطقة الكوع ( Olecranon Bursitis ) ، (٥٦) حالة كانت ( Presternal Bursitis ) ، (١) حالات فى الخيول فى منطقة الكيس الزلالي للكوع (٧) حالات فى الحمير

#### Supraspinous Bursitis

الحالات الحادة تم علاجها بحقن ١٠٠ ملليجرام هيدروكورتيزون وبنسلين مليون وحدة مرة كل أسبوع لمدة (٣-٢) أسابيع والحالات ذات الحجم الكبير تم علاجها بعمل فتحة بالمشروط فى أسفل نقطة لتفريغ محتواها . الحالات المزمنة والمتليفة تم استئصالها جراحياً .

سجلت (٣٠) حالة من الحويصلات (١٩) حالة فى الأبقار (١٢) Branchial ، (٧) Retention ، (٨) حالات فى الجاموس ، (٤) Branchial ، (٤) Retention الاستئصال الجراحى للحويصلات كان العلاج الفعال والأكيد مع الحذر فى التعامل أثناء فصل الحويصلة عن الأجزاء الحيوية المحيطة بها .

أثناء اجراء هذه الجراحة ظهرت عاصفة من الاصابة بمرض التهاب الجلد العقدى الفيروسى فى مناطق اجراء الدراسة حيث سجلت (٥٦١) حالة تطلب اجراء التدخل الجراحى لها . حيث ظهرت أعراض أوديميا فى منطقة الارجل والصدر اسفل الرقبة وكذلك تورمت الغدد الليمفاوية الخارجية وتم التعامل الجراحى مع هذه الحالات كأنها خراجات كبيرة الحجم . سجلت (٩٩) حالة من التهاب الجلد الأوريمى البكتيرى فى الجاموس حيث ظهرت تورمات مؤلمة موزعة على مناطق مختلفة من أنحاء الجسم خاصة الأرجل والصدر وأسفل الرقبة مما اثر على الحالة الصحية العامة للحيوان وكذلك تأثرت قدرة الحيوان على الوقوف متزنا والمشي الطبيعى والعلاج بالمضادات الحيوية ومضادات الألتهايات وحدها لم يعطى نتيجة مرضية بينما مصحوبا بالتدخل الجراحى أعطى النتيجة المأمولة

سجلت حالات الفتاق فى (٢٣٧) حالة ، (١١٤) من الأبقار ، (٢٧) حالة فى الجاموس ، (٣٩) حالة فى الخيول ، (١٥) حالة فى الحمير ، (٣٦) حالة فى الأغنام ، (٦) حالات فى الماعز .

حالات فتاق السرة سجلت (٩٩) حالة معظمها فى الحيوانات حديثة الولادة ، (٦٣) حالة من الأبقار ، (٢٧) حالة فى الجاموس ، (٦) حالة فى الأغنام (٣) فى الخيول .

حالات الفتاق فى جدار البطن الجانبى سجلت (٥٤) حالة معظمها فى الناحية اليمنى لجدار البطن ، (٢٤) حالة فى الأبقار ، (١٥) أغنام ، (٦) فى الخيول ، (٩) فى الحمير . بينما سجلت (٤٢) حالة اصابة بالفتاق فى جدار البطن السفلى فى مواقع مختلفة (٢١) حالة فى الأبقار ، (٩) أغنام ، (٦) من الماعز ، (٦) من الخيول

تم تسجيل (٤٢) حالة فتاق فى جدار الصفن المبطن للخصيتين معظمها فى ناحية واحدة جهة اليمين (٦) حالات فى الأغنام ، (٢١) حالة فى الخيول ، (١٥) حالة فى الحمير .

التدخل الجراحى المناسب أثبت انه الطريقة النموذجية لعلاج الفتاق فى الحيوانات .

سجلت (٤٢) حالة من الاودىما المرضيه (٢١) فى الأبقار ، (٦) فى الجاموس ، (٣) فى الاغنام ، (٧) فى الحمير و (٥) فى الخيول.

سجلت (١٣٥) حالة انقلاب خارجى (١٨) حالة انقلاب مستقيم ، (٥٢) حالة انقلاب مهبلى و (٦٥) حالة انقلاب رحمى وتم العلاج جراحيا بما يناسب كل حالة.

## الخلاصة

بناء على النتائج السابقة يمكن استخلاص الاتى :

الوصف الظاهري لكل اصابه بالنظر إلى طبيعتها و امتدادها بالإضافة إلى التشخيص المقارن سوف يؤدى إلى التدخل الجراحى المناسب لكل حالات الأورام الخارجية فى حيوانات المزرعة .



دراسات جراحية للأورام الخارجية فى

حيوانات المزرعة

مقدمه من

ط.ب/ مفيد يوسف أحمد اسماعيل

للحصول على درجة

دكتور الفلسفة فى العلوم الطبية البيطرية تخصص ( جراحة )

لجنة الحكم والمناقشة على الرسالة

التوقيع

اللجنة

١. السيد أ.د/ هانى محمد جوهر  
أستاذ الجراحة وعميد كلية  
الطب البيطرى - جامعة القاهرة

٢. أ.د/ أحمد عبد المنعم قناوى  
أستاذ الجراحة - كلية الطب  
البيطرى - جامعة الإسكندرية

٣. السيد أ.د/ مصطفى محمد قاسم  
أستاذ الجراحة  
كلية الطب البيطرى - جامعة الإسكندرية  
والمشرف على الرسالة

٤. السيد أ.د/ سمير راشد نسوح  
أستاذ ورئيس قسم الجراحة  
كلية الطب البيطرى - جامعة الإسكندرية  
والمشرف على الرسالة

٥. السيد د./ رمضان السيد عبد الواحد  
أستاذ مساعد الجراحة  
كلية الطب البيطرى - جامعة الإسكندرية  
والمشرف على الرسالة

تحريرا فى ١ / ٦ / ٢٠٠٨

لجنة الإشراف

الأستاذ الدكتور / مصطفى محمد قاسم

أستاذ الجراحة - كلية الطب البيطري

جامعة الإسكندرية

الأستاذ الدكتور / سمير راشد نوح

أستاذ ورئيس قسم الجراحة

كلية الطب البيطري

جامعة الإسكندرية


الدكتور / رمضان السيد عبد الواحد

أستاذ مساعد الجراحة

كلية الطب البيطري

جامعة الإسكندرية

٨١



## دراسات جراحية للاورام الخارجية فى حيوانات المزرعة

رساله علميه

مقدمه الى الدراسات العليا بكلية الطب البيطرى - جامعة الاسكندريه  
استيفاء للدراسات المقرره للحصول على

درجة  
دكتور الفلسفه فى العلوم الطبيه البيطريه

تخصص  
(الجراحه)

مقدمه من

ط.ب / مفيد يوسف أحمد أسماعيل  
(بكالوريوس العلوم الطبية البيطرية - جامعة طنطا ١٩٩٥)  
(ماجستير العلوم الطبية البيطرية جامعة الاسكندرية ٢٠٠٤)

٢٠٠٨