

ULTRASONOGRAPHIC AND HISTOPATHOLOGICAL DIAGNOSIS AND MANAGEMENT OF SOME SURGICAL AFFECTIONS IN DOGS AND CATS

BY

Zaghloul, A.E.I.; *Hala M. F. EL Miniawy; **Abuzaid, S. M. and Karrouf, G.I.A.

Department of Surgery, Anesthesiology and Radiology, Fac. Vet. Med., Mansoura Univ.

**Department of Pathology Fac. Vet. Med, Cairo Univ.*

*** Department of Anatomy and Embryology, Fac. Vet. Med., Suez Canal University.*

ABSTRACT

The present retrospective study was carried out on seven dogs and eight cats from a total of 50 dogs and 30 cats admitted to the Veterinary Clinic of Suez Canal and Mansoura Universities in the period from 1998 to 1999. The animals were examined on the basis of case history, physical examination, ultrasonographic examination and confirmative histopathology. Animal age, sex, breed and anatomical location of the lesions were also reported. The recorded lesions in cats were cystic hyperplasia-pyometra complex (1), lymphosarcoma (1) and hepatic lipidosis (6), while in dogs were mammary adenocarcinoma (1), vulvovaginal lymphosarcoma (1), Vaginal histiocytoma (2), cutaneous melanoma (1) and cutaneous haemangioma (1).

Surgical excision was the possible treatment of choice of the mammary, cutaneous and vulvovaginal neoplasm, while euthanasia preferred for the inoperable metastatic cases of neoplasm.

INTRODUCTION

Cancer is considered a major cause of pet animal death. In one study, it caused death in 45% of dogs in a series of 2,000 autopsy cases. Regardless the exact numbers, cancer is one of the killers of pet animals (Bornson, 1982).

Bitches have greater incidence of mammary neoplasia than other female domestic animals (Brodey, 1983). The frequency increases dramatically after 6 years and peaks at 10-11 years (Fowler, 1974 and Mulligan, 1975). Its occurrence is most common in the two caudal pairs (Cotchin, 1958; Misdorp, 1971; Brodey, 1970; Mulligan, 1975, Warner, 1976 and Misdorp and Hart, 1979).

The vaginal and vestibular tumors are the most common female reproductive neoplasm in bitches (Engle and Brodey, 1969 and Schmidt and Langham, 1967). Most canine vaginal tumors are transmissible venereal tumors followed by leiomyomas, lipomas, squamous cell carcinomas, nerve sheath tumors, fibrous histiocytoma, benign melanoma, myxoma, myxofibroma and adenocarcinoma (Howell, 1970 and McEntee and Nielsen, 1976).

Ultrasonography made a major impact on the diagnosis of the abdominal diseases in small animals. Ultrasonography of the abdomen is particularly useful for measurements of organs, obtaining anatomical information not easily obtained by other

means, investigating peritoneal fluid, determining the origin and structures of masses and guiding biopsy.

The aim of this study was to evaluate the use of ultrasonography as noninvasive technique and histopathology in diagnosis and management of the recorded cases, specially the neoplasms, reporting their common types, site of occurrence and clear out the operable from inoperable ones in dogs and cats.

MATERIAL AND METHODS

A total number of 30 cats (10 males and 20 females) and 50 dogs (15 males and 35 bitches) were admitted to the veterinary clinics of Suez Canal and Mansoura universities through the period from 1998 to 1999. Fourteen cases of which (8 cats and 6 dogs) suffering from surgical and nonsurgical disorders were subjected to thorough investigations. The case history, physical examination, ultrasonography and confirmative histopathology were used for the examination of such cases.

Ultrasonography

Ultrasonography was performed by B-mode, gray scale 2D-imaging system using 7.5MHz linear transducer for cats and 5MHz linear transducer for dogs. It was carried out in the ultrasonography unite of the Central Lab for Medical and Veterinary Medical Service at Suez Canal University using Acuson Computed Color Doppler 128XP, 5c ultrasonic machine *.

Patient was placed in dorsal recumbence for most ultrasound procedures. Also, right and left lateral recumbence positions were used. The hair on the ventral and bilateral aspects was clipped and ultrasound gel was applied as coupling agent between the skin and the surface of the transducer.

Systemic scanning of the abdomen has been started with the structures that have fixed locations and consistent architecture.

Histopathological examination

The histopathological specimens were obtained at necropsy after euthanasia from two cats, during laparotomy in one bitch and by surgical excision biopsy from six cats (hepatic lipidosis) and six dogs (three vulvovaginal tumors and three cutaneous tumors).

The specimens were fixed in 10% neutral buffered formalin, dehydrated in serial grades of ethyl alcohol (70%, 80%, 96% & absolute) and cleared in xylene. The tissue specimens were then embedded in paraffin wax, sectioned at 4-6 microns and stained with Hematoxylene and eosine (Bancroft, Stevens and Jurner (1990).

* Acuson corporation, 1220 Charleston Road, Mountain View, California

RESULTS

The diagnosed cases and sex distribution in the present study were given in the following table

| Type of affections | No. of cases | Male cats | Female cats | Male dogs | bitches |
|--------------------------------------|--------------|-----------|-------------|-----------|---------|
| Cystic hyperplastic pyometra complex | 1 | | 1 | | |
| Lymphosarcoma | 1 | | 1 | | |
| Hepatic lipidosis | 6 | 4 | 2 | | |
| Mammary adenocarcinoma | 1 | | | | 1 |
| Vaginal histiocytoma | 2 | | | | 2 |
| Vulvovaginal lymphosarcoma | 1 | | | | 1 |
| Cutaneous hemangioma | 1 | | | 1 | |
| Melanoma | 1 | | | 1 | |
| Total | 14 | 4 | 4 | 2 | 4 |

Case No.1

A five years old Siamese cat of 3kg body weight was presented with a history of abdominal enlargement, inappetance and reluctant to move. Physical examination revealed severe dehydration, subnormal temperature and weak pulse. Cardiac arrhythmia was detected on auscultation of the thorax. The cat was referred for abdominal ultrasonography.

The sonographic picture showed widely dilated tubular uterus with thick irregular hyperechoic uterine wall. The uterine lumen was filled with hypoechoic fluid containing small hyperechoic particles (Fig. 1A&B). The other internal organs showed normal size and echogenisity except for the liver that showed diffuse hyperechogenic pattern increased at its portal area (Fig.1C). There was neither intra-abdominal masses nor ascetic fluid. The preliminary diagnosis was pyometra. At necropsy, the uterine horns appeared distended; sausage shaped and filled the pelvic cavity (Fig.2A).

Microscopic picture

The histopathological findings of the uterus showed marked endometrial hyperplasia. The epithelial lining the mucosa and the uterine glands were enlarged and vacuolated. Masses of neutrophils were collected in the uterine lumen and in the glands. The latter were mainly dilated and cystic. The migrating leukocytes were collected near the surface and penetrated the epithelium (Fig.2B). The endometrial stroma was expanded by edema and fibrinocellular exudate. The ovary seemed to be in metestrous with developed corpus luteum. The liver showed focal lipidosis and the affected hepatocytes revealed microvesicular pattern and few of them were manifested by macrovesicular changes forming signet ring appearance (Fig.2C). The portal triads were markedly thickened with fibrosis and widely dilated blood vessels. The bile ducts exhibited prominent hyperplasia (Fig.2D). Retained bile pigments were distinct in some hepatocytes and in Kupffer cells.

Case No.2

A seven years old Balady cat weighing 4kg was presented with a history of gradual enlargement of the abdomen, off food, dyspnea and unable to move. Physical examination revealed body temperature within normal range; weak pulse on auscultation, enlarged and tender abdomen on palpation and the internal organs could not be identified. Exploratory puncture revealed dark bloody fluid.

Ultrasonography, the left kidney appeared enlarged with irregular contour and loss of the demarcation between the cortex and medulla. The parenchyma showed multiple hypoechoic foci (Fig.3A). The right kidney showed normal size and echogenic pattern (Fig.3B). The liver showed mild enlargement, diffused mixed echogenic pattern, rounded margins and clear interlobar fissures (Fig.3C). The abdomen presented severe enlarged lymph nodes with hypoechoic pattern (Fig.3D). The spleen seemed to be normal while the pancreas was obscured by the abdominal masses. The abdominal and pelvic cavities were filled with ascetic fluid to a degree that the organ ligaments could be easily identified sonographically as hyperechoic lines. A comparison of the peritoneal effusion with the sonographic appearance of the urine within the urinary bladder, indicated nearly anechoic effusion (Fig.3E).

The case was inoperable and euthanasia was performed and most organs were used for histopathological examination.

On post-mortal examination multiple whitish masses occupied the abdominal lymph nodes (Fig.4A). The left kidney was markedly enlarged with multiple distributed cortical masses and disconfiguring renal surface (Fig.4B).

Microscopic picture

The histopathological picture of the tumor had great variability, as the bulk of the tumor mass was composed of groups of pleomorphic cells separated by fine strands of connective tissue septa (Fig.5A). The latter appeared to be intimately associated with the tumor cells. The nuclei of the neoplastic cells were pleomorphic, hyperchromatic and some of them were cleaved. Other nuclei were markedly enlarged and vesicular with prominent one or two nucleoli. Typical and atypical mitosis were frequent (Fig.5B). The cytoplasm tended to form strands of eosinophilic material (reticulin or collagen) (Fig.5C). In some areas of the tumor, the neoplastic cells were distinctly vacuolated and sometimes arranged around a central cavity giving false appearance of tubular structures. Large areas of necrosis and haemorrhage were observed.

The tumor mass seemed to be reticulum cell type of lymphosarcoma. The architectures of the affected regional lymph nodes was obscured by proliferated pleomorphic vacuolated cells and the lymph sinuses were greatly enlarged and eroded by the infiltrated neoplastic cells (Fig.5D). The spleen and lungs showed non-significant pathological changes while the liver showed perivenular hepatic lipidosis.

Cases No. 3-8

Six cats (4 males and 2 females) 6-8 years old had clinically apparent hepatobiliary disorder on the basis of history and physical examination. They suffered from anorexia, mildly hepatomegally on palpation and severe muscle wasting.

Ultrasonography, the liver showed diffuse hyperechogenicity on comparing with falciform and omental fat with poor visualization of the intrahepatic vessel borders. The gall bladder showed thick wall and its lumen contained little echogenic materials (Fig.6A&B).

Microscopic picture

The hepatic parenchyma revealed diffuse fatty changes of moderate severity (Fig.7). The lipid accumulated in the hepatocytes in a microvesicular and macrovesicular form. Both patterns of lipidosis were distinguished in all affected cases.

Case No. 9

Eleven years female dog weighing 17kg and never get married was presented for a mass of 3x3 cm on the right inguinal mammary gland, subcutaneous lobulated 2x2 cm masses on the left thoracic gland, small (1x0.5 cm) masses distributed allover the mammary glands and diffuse subcutaneous edema.

Ultrasonography, revealed homogenous masses of complex mixed echogenicity surrounded by subcutaneous edema in the mammary glands (Fig.8A). Similar masses were attached to the uterine wall and projected into its lumen (Fig.8B). There was little hypoechoic fluid in the uterine lumen. The liver showed diffuse hyperechogenicity with poor visualization of the intrahepatic vessel's borders (Fig.8C). Ovario-hysterectomy was indicated.

Under the effect of routine general anesthesia and aseptic preparations, both ovaries and uterus were excised using three clamps technique on the ovarian pedicle. Transfixation ligature between the uterine body and cervix and inverting stitches on the uterine stump. The excised mass, ovaries, uterus and surgical biopsy from the liver were used for histopathological examination.

Microscopic picture

The excised mass revealed tumor consisting of small clusters or cords of infiltrating cells embedded in thick connective tissue stroma (Fig.9A). The neoplastic cells showed cellular and nuclear pleomorphism. The nuclei were mostly vesicular with margination of their chromatin. Other cells possessed hyperchromatic nuclei with prominent one or two nucleoli. Many of the nuclei were extremely large and occupying the whole cell and mitosis was frequent. There was attempt for acinus formation and the neoplastic cells arranged themselves around central cavities. On the other side, few large well-formed acini containing secretions were observed. They were lined by exuberant epithelium showing high mitotic activity (Fig.9B). The tumor mass showed large areas of necrosis and hemorrhage. The histopathological picture revealed scirrhous adenocarcinoma.

The uterus showed marked endometrial hyperplasia, the epithelial covering was thrown into folds protruded towards the lumen forming polypoid structures. The uterine glands were hyperplastic and their lining were enlarged. Some glands appeared dilated and cystic. Focal hemorrhage with vascular congestion was observed in the endometrial stroma (Fig.9C). The ovaries showed no abnormal cysts. The hepatic parenchyma revealed diffuse vacuolar degeneration and the hepatocyte appeared swollen, vacuolated and reticulated (Fig.9D). Some isolated hepatocytes were greatly

enlarged, vacuolated forming signet ring appearance and pigmented brown by retained bile pigments.

Case No. 10

A six years female Great-den weighing 60kg was presented showing a cauliflower mass of 3cm diameter popped out from the vulva with repeated trauma and ulceration (Fig. 10A). Tenesmus, obstruction of the vaginal vestibule and a sanguinous vaginal discharge were clear. On the basis of the case history and physical examination, it was diagnosed as vulvovaginal tumor.

Surgical treatment

Under the effect of general anesthesia, the bitch was placed in a perineal stand with padding at the end of the table. A purse-string suture was placed around the anal opening to prevent faecal contamination during surgery. The urethral papilla was located and the bladder was catheterized by a Foley catheter 8 french. Hair was removed from the perineal region and the proper vagina and vestibule were flushed with betadine 1/10. Complete surgical excision of the tumorified mass was done with great care for controlling bleeding by clamping and ligating the bleeders (Fig.10B). The idea of ovariohysterectomy was refused by the owner.

Microscopic picture

The tumor cells were mainly oval or ovoid with poorly stained cytoplasm. Their nuclei attained large size and hyperchromatia. There were distinct mitosis and intercellular reticulum between the neoplastic cells. The tumor mass was invaded with large number of eosinophils (Fig.11). The mass seemed to be lymphosarcoma (transmissible venereal tumor).

Cases No. 11 & 12

Six years old Great Den and 7 years old Black jack intact bitches weighing 50 and 40 Kg respectively were presented with vulvovaginal mass since one month. The mass of the Black jack had a cauliflower appearance, pedunculated and completely popped out from the vulva. It was firm, pink red in color and measures 2x2 cm (Fig. 12A). The mass of the Great Den bitch was smooth and slightly popped out from the vulva (Fig.12B). The mass of both bitches was treated by the same way as in case number 10.

Microscopic picture

The tumor originated mainly in the submucosa and had delicate vascular stroma run between the neoplastic cells in a form of fine trabeculae. The histological appearance of the cellular components was round or polyhydral with indistinct boundaries. The nuclei were greatly enlarged in proportion to cell size and the cytoplasm was scanty but clear. The cell size was markedly variable and mitosis was frequent. Toluidine blue stained section was negative for mast cell granules. The mass gave the appearance of histiocytoma (Fig. 13).

Case No. 13

Seven years old Great Den male dog weighing 55kg was presented with a history of multiple cutaneous small nodular or lobulated pinkish masses on different body regions; thigh, olecranon and ventrum of the abdomen (Fig.14A).

Surgical treatment

Under the effect of routine general anesthesia and aseptic preparation, the cutaneous masses were excised and submitted to histopathological examination.

Microscopic picture

The excised masses revealed wide vascular channels filled with blood (Fig.14B). It could be diagnosed as cavernous haemangioma.

Case No. 14

Five years old male Great Den dog weighing 45kg was admitted with a history of a cutaneous black soft and ulcerative nodule on the cranio-medial aspect of the thigh region (Fig.15A).

Surgical treatment

Under the effect of routine general anesthesia and aseptic preparations, the mass was surgically excised and submitted for histopathological examination.

Microscopic picture

The epidermis of the mass area was ulcerated and infiltrated with large number of polymorphs, lymphocytes and plasma cells. Columns of melanocytes invaded the dermis. The melanocytes attained oval, ovoid or rounded shape with scanty eosinophilic cytoplasm and large vesicular nuclei (Fig.15B). The melanocytes exhibited marked mitotic activity (Fig.15C) and some of them carried melanin (Fig.15D). Acute inflammatory reaction accompanied the invaded melanocytes.

DISCUSSION

Cystic endometrial hyperplasia-pyometra complex was recorded in bitches in response to progesterone during diestrus (Hardy and Senior, 1980 and Goddard, 1995). Pyometritis appears to develop as complication of cystic endometrial hyperplasia (Burke and Reynold, 1981). The disease is less prevalent in cats (Colby, 1980). However, pyometra in case 1 was seen in unbred house cat. Such finding agreed with Stone (1985) who speculated that the female may respond sexually to mild stimulation that is sufficient to cause a cessation of estrous and ovulation occurs with the formation of corpus lutum.

Fluid, electrolytes and acid-base imbalance; renal dysfunction, sepsis, hypoglycemia, liver damage, anemia and cardiac arrhythmia were recorded as complications to pyometra (Marretta et al, 1989).

The sonographic picture of the uterus reported here simulates the findings of Goddard (1995). Goddard added that the uterine diameter may vary depending

whether the pyometra is open or closed. He also mentioned that the hyperechogenic particles within the uterine lumen represent the infiltrating depress or haemorrhage.

The hepatic cell injury and intrahepatic cholestasis and retention of bile pigments may be due to toxicity, secondary to sepsis, endotoxemia or poor hepatic perfusion secondary to dehydration (Stone, 1985).

More than 90% of the primary renal tumors in the dog and cats are malignant. Renal adenocarcinomas usually arise in the renal cortex or one of the renal poles. They may be highly invasive to the regional structures and may invade the vena cava. Metastasis to the regional lymph nodes, lungs, liver and bones occurs in more than 50% of cases (Klein et al, 1988). Renal neoplasia is low in human and dogs and more frequent in males than females (Baskin and Depaoli, 1977). Renal lymphosarcoma in cats is considered the most important secondary tumor of the kidney. It is one manifestation of several hemopoietic diseases caused by the feline leukemia virus FLV (Whitehead, 1967). In the present study, the tumor masses in the kidney and mesentric lymph nodes were highly anaplastic and associated with desmoid reaction resulted in separation of the neoplastic cells into groups. The poorly differentiated tubular structure arrangement of the tumor cells, may be confused with those of the renal adenocarcinoma. The latter, is usually well differentiated, in animals, forming tubular or papillary structures lined by clear vacuolated cells (Moulton, 1986). It often contains remnants or compressed renal tissues (glomeruli and tubules). Here, the undifferentiated neoplasm was neither contained residual renal tissue nor resembled differentiated adenocarcinoma. Moreover, the pattern of focal distribution of the tumor on the renal cortex and the involvement of the regional lymph nodes suggested lymphosarcoma.

The anechoic appearance of the peritoneal effusion in the present study indicates that the fluid is of transudate type. In this connection, Spaulding (1993) reported that the peritoneal effusion derived from carcinomatosis may have either anechoic or echogenic appearance depending on the chronicity and exfoliation nature of the tumor. She added that hepatic enlargement and severe renal diseases are most often associated with either transudate or modified transudate. Transudate is usually anechoic while the modified transudate is frequently more echogenic but less than exudate. Like that mentioned by Biller, Kantrowitz and Miyabayashi (1992b), the loss of the sharpness of the liver borders had been seen here, may be attributed to its enlargement.

The excellent ability of ultrasonography to correctly identify severe hepatic lipidosis in cats was expected as fatty tissues are hyperechoic and attenuate sound more rapidly than other soft tissues (Behaw and Kazam, 1978). In the current study, two cases of hepatic lipidosis were associated with uterine cystic hyperplasia and lymphosarcoma and were evidenced histologically. The next six cases were similarly diagnosed ultrasonographically. In this respect, Yeager and Mohammed (1992) mentioned that ultrasonographic examination is useful and reliable test for detection of hepatic lipidosis in cats having hepatobiliary disorders. Hepatic lipidosis has been recorded in small animals in case of starvation, obesity diabetes mellitus, drugs and toxins (Strombeck and Guilford, 1990).

Moulton (1986) reported that about 50% of mammary neoplasms are benign and most of them are fibroadenoma. They added that the common metastatic sites in malignant types include the liver, ovaries and uterus that showed different characteristic changes.

The findings recorded in the case of mammary tumor in the present study showed no metastases in the internal organs, similar to those described by Fidler and Brodey (1967), Misdrop (1971), Theilen and Madewell (1979) and Brodey (1983). The associated endometrial hyperplasia indicates that the tumor may be hormonal dependent. In this concern, MacEwen (1982) mentioned that endocrine dysfunction predisposes the animal to mammary gland neoplasia.

The vaginal and vestibular tumors are the most common female reproductive neoplasms in bitches (Kydd and Burnie, 1986). Brodey and Rozzel (1967) and Thacher and Bradley (1983) mentioned that most of such neoplasms are leiomyoma and transmissible tumors. It occurs in sexually intact or spayed bitches and metastasis are rare. Macy and MacEwen (1989) denoted that histiocytomas are a common tumor in bitches characterized by macrophage population. Histiocytomas are usually solitary tumors although multiple forms have been reported. Recurrence is uncommon and metastasis does not occur (Bender and Mueller, 1989). The recorded cases in the present study were happened in intact female Great-Den dogs and were treated by wide surgical excision like that recommended by Amber and Henderson (1982). Case follow up revealed no recurrence and bitches get pregnant and delivery was smooth.

Similar case of vaginal lymphosarcoma like that in the present study was reported by Calvert et al (1982) in dogs less than 5 years old as transmissible tumor. They described such tumors as multilobulated, pink and friable masses involving the vaginal vestibule. Wide surgical excision was successful treatment, however follow up of the case was not possible.

Haemangioma is a vascular hamartia rather than tumor. It is more prevalent in older dogs with pigmented skin (Stantond and pulley, 1978). Its macro- and microscopic pictures simulate those described by Thronburg and Breitschwert (1976) and Ogburn (1993).

Tumors of melanocytes are common in dogs and horses. They are found most often in the skin but may also occur in the oral cavity and eye of dogs, horses and pigs (Thomson, 1984). In the current study, the melanin pigment containing melanocytes invading the dermis, made the tumor easily identified.

REFERENCES

- Amber, E.I. and Henderson, R.A. (1982): Canine transmissible venereal tumor. Evaluation of surgical excision in primary and metastatic lesions in Zaria-Nigeria; *J. Am. Anim. Hosp. Assoc.* 18: 350.
- Bancroft, J.D., Stevens, A. and Jurner, D.R. (1990): Theory and practice of histological technique. 3rd ed. Churchill Livingstone, London and New York.

- Baskin, G.B. and Depaoli, A. (1977):** Primary renal neoplasms of the dog. *Vet. Path.*; 14: 591-605.
- Behaw, M. and Kazam, E. (1978):** The echogenic characteristics of fatty tissue and tumors. *Radiology*; 129: 143-151.
- Bender, W.M. and Mueller, G.H. (1989):** Multiple resolving cutaneous histiocytoma in a dog. *JAVMA*; 194: 535.
- Biller, D.S., Kantrowitz, B. and Miyabayashi, T. (1992b):** Ultrasonography of diffuse liver disease: A review. *J. Veterinary Internal Medicine*.6:71-76.
- Bornson, R.T. (1982):** Variation in age at death of dogs of different sexes and breeds. *Am. J. Vet. Res.*; 43: 2057-2059.
- Brody, R.S. (1970):** Canine and feline neoplasia. *Adv. Vet. Sci. Comp. Med.* 14: 309.
- Brodey, R.S. (1983):** Canine mammary neoplasms. *J. Am. Anim. Hosp. Assoc.*; 19: 61.
- Brodey, R.S. and Rozzel, J.F. (1967):** Neoplasms of the canine uterus, vagina and vulva. A clinicopathologic survey on 90 cases. *JAVMA*; 151: 1294-1307.
- Burke, I.D. and Reynolds, H.A. (1981):** The female genital system. In, Bojrab, *Pathophysiology in small animal surgery*. Lea and Febiger, Philadelphia, 427-429.
- Calvert, C.A., Leifer, C.E. and MacEwen, E.G. (1982):** Vincristine for treatment of transmissible venereal tumor in the dog. *JAVMA*; 181: 163.
- Colby, E.D. (1980):** The estrous cycle and pregnancy. In, Morrow, *Current therapy in theriogenology*. W.B. Saunders Co. Philadelphia, 832-839.
- Cotchin, E. (1958):** Mammary neoplasms in bitch. *J. Comp. Path.* 68:1
- Engle, C.G. and Brodey, R.S. (1969):** A retrospective study of 395 feline neoplasm. *J. Am. Anim. Hosp. Assoc.* 5: 21.
- Fidler, I.J. and Brodey, R.S. (1967):** A necropsy study of canine mammary neoplasms. *J. Am. Anim. Hosp. Assoc.* 151: 710
- Fowler, E.H. (1974):** Biologic behavior of canine mammary neoplasms based on histogenetic classification. *Vet. Path.* 3: 197.
- Goddard, P.J. (1995):** *Veterinary ultrasonography*. CAB International Wallingford, UK.
- Hardy, R.M. and Senior, D.F. (1980):** Canine pyometra. In, Kirk; *Current veterinary therapy VII*. W.B. Saunders Co. Philadelphia, 1216-1219.
- Howell, J.M.C. (1970):** A 6 year survey of tumors of dogs and cats removed surgically in private practice. *J. Small Anim. Pract.* 11: 793.
- Klein, M.K. Cockerell, G.I. and Withrow, S.J. (1982):** Caprine primary renal neoplasms: A retrospective review of 54 cases. *J. Am. Anim. Hosp. Assoc.* 24: 443-452.
- Kydd, D.M. and Burine (1986):** Vaginal neoplasia in bitch. A review of forty clinical cases. *J. Small Animal Practice.* 27: 255.
- MacEwen, E.G. (1982):** Estrogen receptors in canine mammary gland tumors. *Cancer Res.* 42: 2255-2259.
- Macy, D.W. and MacEwen, E.G. (1989):** Mast cells tumors. In, *Clinical veterinary pathology*. J.B. Lippincott, Philadelphia. 156-166.
- Marretta, M.S., Matthiesen, D.T. and Nichol, R. (1989):** Pyometra and its complications. *Problems in veterinary medicine*. Vol. I (1) 50-61.
- McEntee, K. and Nielsen, S.W. (1976):** Tumors of female genital tract. *Bull. WHO* 53: 217.
- Misdorp, W. (1971):** Canine malignant mammary tumors. I: Sarcomas. *Vet. Path.* 8: 99.

- Misdorp, W. and Hart A.A.M.(1979):** Canine mammary carcinoma. I: Prognosis. *J. Small Anim. Pract.* 20: 385.
- Mulligan, R.M. (1975):** Mammary cancer in the dog. A study of 120 cases. *Am. J. Vet. Res.* 36: 1391.
- Moulton, J.E. (1986):** Tumors in domestic animals. University of California Press, Berkeley. 16-74.
- Ogburn, P.N. (1993):** Cardiovascular system. In, Slatter, A text book of small animal surgery. 2nd. Ed. W.B. Saunders Co. Philadelphia. 2016-2111.
- Schmidt, R.E. and Langham, R.F. (1967):** A survey of feline neoplasms. *JAVMA.* 151:1325.
- Spaulding, K.A. (1993):** Sonographic evaluation of peritoneal effusion in small animals. *Veterinary radiology and ultrasound.* 34: 427-431.
- Stantond, A.A. and Pulley, L.T. (1978):** Tumors of the skin and soft tissues. In, Moulton, Tumors in domestic animals. University of California Press, Berkeley. 16-74.
- Stone, E.A. (1985):** The uterus. In, Slatter, Text book of small animal surgery. W.B. Saunders Co. Philadelphia. 1661-1672.
- Strombeck, D.R. and Guilford, W.G. (1990):** Small animal gastroenterology. 2nd. Ed. Wolfe Publishing Limited.
- Thacher, C. and Bradley (1983):** Vulvar and vaginal tumors in the dog. A retrospective study. *JAVMA.* 183: 690.
- Theilen, G.H. and Madewell, B.R. (1979):** Veterinar cancer medicine. Leo and Febiger. Philadelphia.
- Thomson, R.G. (1984):** General veterinary pathology. 2nd. ed. W.B.Saunders Co. Philadelphia, London, Toronto and Tokyo.
- Thornburg, L.P. and Breitschwert, E.B. (1976):** Canine haemangioma of the scrotum with fatal bleeding. A case report. *J. Am. Anim. Hosp. Assoc.* 12: 797.
- Warner, M.R. (1976):** Age incidence and distribution of mammary dysplasia in young beagle bitches. *JNAH Cancer Inst.* 57:57.
- Whitehead, J.E. (1967):** Survey of feline neoplasms. *Vet. Med. Sm. Anim. Clin.* 62: 357-358.
- Yeager, A.E. and Mohammed, H. (1992):** Accuracy of ultrasonography in the detection of severe hepatic lipidosis in cats. *Am. J. Vet. Res.* 53 (4) 532.




Fig. 1
Sagittal (A) and transverse (B) linear scan of the uterus of cat showing thick, hyperechoic irregular wall and wide lumen of the uterine horns. The lumen is filled with hypoechoic fluid mixed with hyperechoic debris. The liver (C) showed diffuse hyperechoic nodular foci and thickened wall gall bladder.

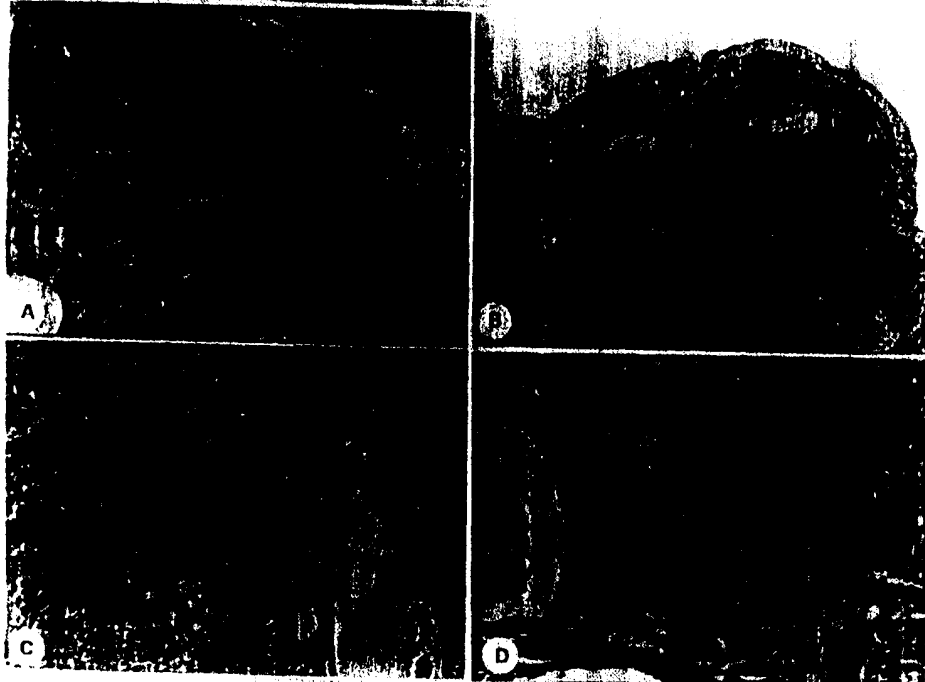


Fig. 2 A. Photographic representation showing thin-walled, sausage-shaped large uterine horns of a cat with pyometra. B. Uterus showing hyperplastic endometrium. Note the masses of neutrophils collected near the surface and in the uterine glands. H&E, X 300. C. Liver showing periportal lipidosis. Note the retained bile inside the hepatocytes. H&E, X 100. D. Liver showing portal area with bile duct hyperplasia. H&E, X 100.

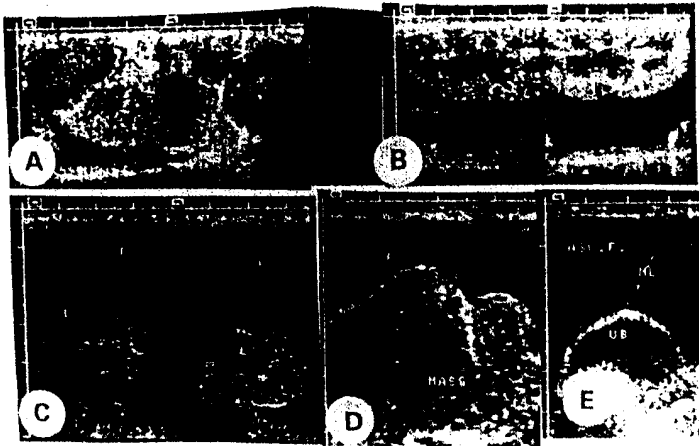


Fig. 3: Ultrasonograph of enlarged left kidney with irregular contour and multiple hypochoic foci in its parenchyma (A). Right kidney of normal size and echogenic pattern (B). Enlarged liver with mixed echogenicity, rounded borders and clear interlobar fissures (C). Severely enlarged mesenteric lymph nodes with internal hypochoic foci (D). Urinary bladder with well demarcated lumen (E) and lot of peritoneal effusion in all graphs.

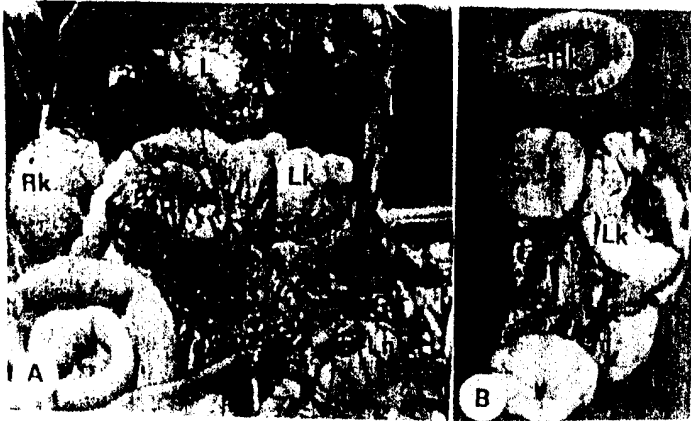


Fig. 4: A-Photographic representation of necropsied cat with abdominal swelling showing greatly enlarged mesenteric lymph nodes, enlarged and discontourating left kidney (Lk), enlarged yellowish liver (L) and dark peritoneal effusion (Pe).

B-Affected left kidney (Lk) with enlarged lymph nodes showing enlarged, circumscribed whitish cortical growth (Lk) and normal sized kidney (Rk).




Fig. 5: A-Kidney lymphosarcoma of cat showing marked separation of neoplastic cells with fine connective tissue strands. H&E. X: 33.
B-Kidney lymphosarcoma of cat showing sheats of pleomorphic cells with atypical mitosis (Am). Note, the cleaved reniform nuclei (c). H&E. X: 330
C-Kidney lymphosarcoma of cat showing cytoplasmic eosinophilic strands of neoplastic cells connecting them to the connective tissue septa. H&E. X: 330.
D-Mesentric lymph node showing eroded lymphatic vessel with the invaded neoplastic cells. H&E. X: 132.




Fig. 6A&B: Ultrasonographic images of the liver of cats with hepatic lipidosis showing hyperechogenicity and poor visualization of the intrahepatic blood vessels borders. Slight hyperechoic depress sometimes present within the gall bladder.




Fig. 7 Liver of cat showing moderate diffuse lipidosis. H&E. X: 66




Fig. 8 Ultrasonography of
A-mammary gland tumor
Showing mixed cyto-
genicity
B-Uterine hyperplasia
C-hepatic lipidosis




Fig. 9 A- Mammary adenocarcinoma of bitch showing column of infiltrated neoplastic cells embedded in thick fibrous connective tissue H&E X 100.
B- Mammary adenocarcinoma of bitch showing well differentiated acini lined by exuberant epithelium with high mitotic activity H&E X 100.
C- Uterus of bitch showing endometrial hyperplasia forming polypoid structures H&E X 33 D- Liver of bitch showing diffuse vacuolar degeneration with reticulation of the vacuolated hepatocytes. Note, the isolated foci of fatty changes and the retained bile pigments inside

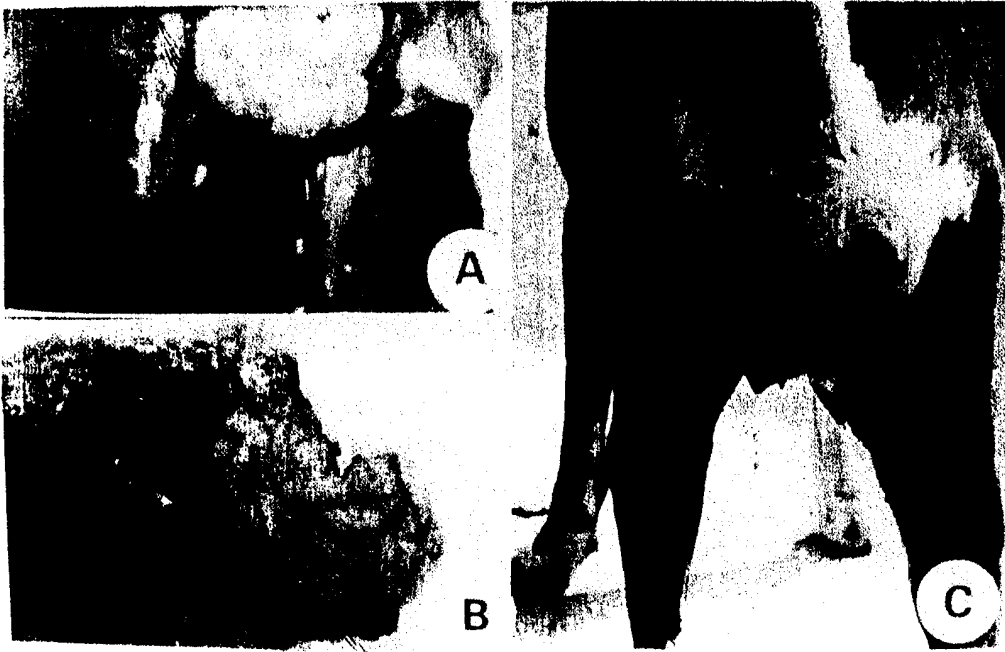


Fig. 10: A- Photograph of Great-Den bitch showing cauliflower vaginal mass popped out from the vulva.
B- The tumor mass after surgical excision.
C- The same bitch 11 months after the surgical excision of the tumor mass without recurrence.



Fig. 11- Vaginal lymphosarcoma of bitch consisting of large ovoid, ovoid or rounded hyperchromatic cells with intercellular reticulin. Note, the eosinophilic cells infiltration. H&E. X: 132.

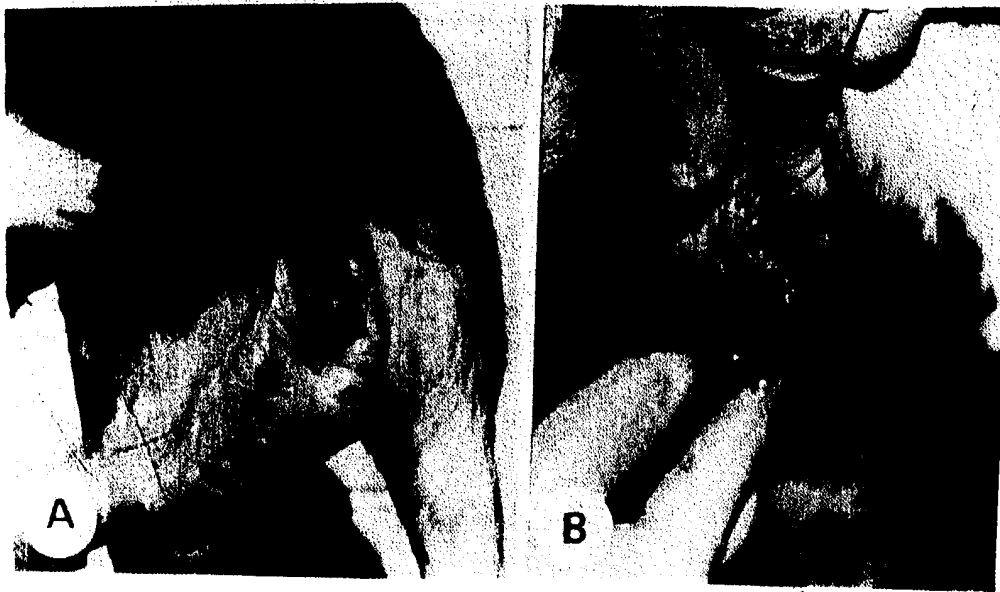


Fig. 12: A- Photograph of black jack bitch showing red cauliflower mass popped from the vulva.
B- Photograph of Great-Den bitch showing smooth pinkish vulvovaginal mass.



Fig. 13: Vaginal histiocytoma of bitch consisting of polyhedral cells with scanty clear cytoplasm and greatly enlarged nuclei. Note, the frequent mitosis. H&E. X: 132.



Fig. 14. A- Photograph of Great-Den dog showing small cutaneous pinkish nodular mass at the thigh and elbow regions. B- Cavernous haemangioma consisting of wide vascular channels filled with blood. H&E X 35.

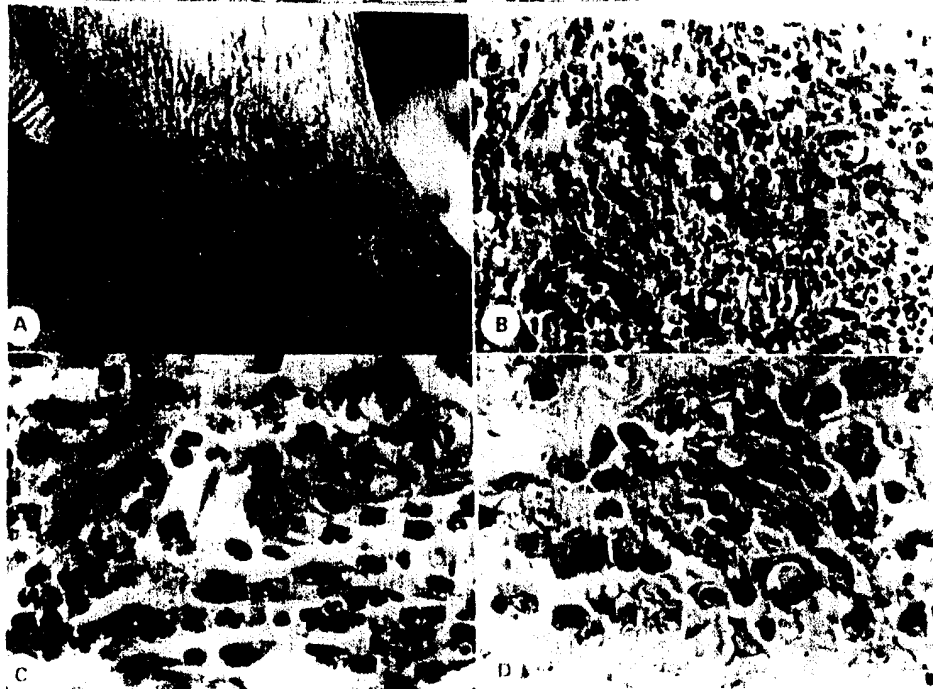


Fig. 15. A- Photograph of Great-Den dog showing cutaneous black elevated nodule on the craniomedial aspect of the thigh region. B- Cutaneous melanoma showing columns of melanocytes invading the dermis and associated with acute inflammatory reaction. H&E X 133. C- Cutaneous melanoma, note the large oval vascular nodule of melanocytes and cellular mitosis. H&E X 330. D- Cutaneous melanoma showing pigmented melanocytes in lamina propria. H&E X 330.

الملخص العربي

التشخيص والتعامل بالموجات فوق صوتية والهستوباثولوجيا لبعض الاصابات الجراحية في الكلاب والقطط

عادل التابعي، *هالة المنياوي ، **صابر أبو زيد، جمال قروف

قسم الجراحة والأشعة والتخدير، كلية الطب البيطري، جامعة المنصورة ، *قسم الباثولوجي، كلية الطب البيطري جامعة القاهرة، ** قسم التشريح والأجنة، كلية الطب البيطري جامعة قناة السويس

أجريت الدراسة بغرض استخدام الموجات فوق صوتية في التشخيص والتقييم العلاجي في بعض الحالات الجراحية في القطط والكلاب وخاصة بعض حالات الأورام الداخلية والخارجية. استخدم في الدراسة خمسين كلبا وثلاثين قطة وردت للعيادة الخارجية بكلية الطب البيطري بجامعة قناة السويس والمنصورة، وفحصت جميعها سريريا.

تم التعامل مع الحالات التي تستدعي الفحص بالموجات فوق الصوتية والتحليل الهستوباثولوجي وعددها سبعة كلاب وثمانية قطط.

هذا وقد تم التعامل جراحيا مع الحالات التي وجد أنها تستوجب الاستئصال الجراحي، وبالمتابعة لم يلاحظ ظهور الأورام المستأصلة مرة أخرى. بينما تم التخلص من الحالات الميئوس من شفائها بالطرق العلمية المتعارف عليها.