

**MORPHOLOGICAL AND ANATOMICAL STUDIES OF  
CERTAIN SYSTEMS IN THE MONTPELLIER SNAKE,  
*Malpolon monspessulanus insignitus*, FAMILY COLUBRIDAE**

(Geoffroy, 1827)

BY

49/8/2

تعتمد كلية الدراسات العليا  
هذه النسخة من الرسالة  
التوقيع التاريخ

**SHIFA'A ABDUL-HAMEED AWWAD**

**SUPERVISOR**

**PROFESSOR AHMAD M. DISI**

**Submitted in Partial Fulfillment of the Requirements for the  
Degree of Master of Science in  
Biological Sciences**

**Faculty of Graduate Studies**

**University of Jordan**

**August 16 1999**

99-  
4/c

THIS THESIS WAS SUCCESSFULLY DEFENDED AND  
APPROVED ON 16<sup>th</sup> AUGUST, 1999

Examination Committee

Signature

Prof. Ahmad M. Disi, Chairman

*Ahmad Disi*

Prof. Of Vertebrate Comparative Anatomy

Prof. Hameed Al-Hajj, Member

*H. A. Al-Hajj*

Prof. Of Embryology

Dr. Mohammed Al-Muhtaseb, Member

*M. M. Al-Muhtaseb*

Asso. Prof. Of Human Anatomy

Dr. Wa'el Khamas, Member

*W. Khamas*

Prof. Of Vet. Anatomy And Histology

Jordan University Of Science And Technology

**DEDICATION****TO****MY WONDERFUL PARENTS, BROTHERS****AND SISTERS,****TO MY CLOSEST FRIENDS****AND FOR YOU; AYMAN**

## ACKNOWLEDGEMENT

I am so grateful to my supervisor, Professor Ahmad Disi who was always taking care of my work, supplying me with the needed help and references, making continuous fruitful discussion and directing me to the proper way. My deep thanks feelings to Professor Hameed Al-Hajj for being one of my teachers during undergraduate and postgraduate study periods, from whom I learnt so much. The special thank for him is offered to be a member of the committee and for spending his time to read this thesis and commenting for better results. Other member of the committee I would like to thank is Dr. Mohammad Al- Muhtaseb. My greetings for him are not only to be a member of the committee but also for his valuable advice he offered during the research period. Also, Professor Wa'el Khamas for his agreement to be a member of the committee and giving his time to comment on this thesis.

My great thanks are for Dr. Zuhair Amr, who was so generous to offer me a great help from the beginning of this research and was always ready to do. Also, I would like to thank Dr. Ahmad Katbeh for allowing me to use his computer and scanner with great welcoming. A special thank is for Dr. Mohammad Al-Khatib for using the genetic laboratory microgram/Faculty of Medicine. I owe Dr. Faisal Kamal a special thank for supplying me with the references I requested from him and to allow me to work in the laboratory of the Department of the Pathology. Also, great thanks is for the technicians in the genetic laboratory: Mr. Zaid, Mr.Mohammad, Mrs. Nehad and Miss Aisha. I'm so grateful to the technicians in the Department of Pathology/Faculty of Medicine: Amal Majdalawi, Haifa'a Hattab and Reem Duwaik for their valuable assistance and teaching me the needed work. My deep thanks is offered to Mr. Ahmad



Abu Aqela and Mrs. Ea'tedal, the Department of Histopathology/University of Jordan Hospital to teach me how to use the cryostat.

Special thank I would like to express to Prof. Garth Underwood for giving me the guidelines in studying the anatomy of skull and head muscles. Also, for Dr. De Haan, who rapidly answered my request to supply me with some references. I owe also, both Dr. Hala Al-Horani and Dr. Salwa Al-Bdour for their continuous asking about me and my work. I want to thank Mr. Mustafa Al-Doumi to facilitate my work in the museum.

My greetings are also presented to my partner in the laboratory; Zulaikha Abu-Neel, who was always with me, sharing beautiful moments as well as suffering ones. Also, to my friends: Shazha Nazzal, Areej Abu-Bakr, Wafa'a Liswi, Lina Al-Kuri, Nisreen Al-Disi, Fatima Dawoud, Majeda Shawabka, Muyassar Abu-Zaid, Wesam Harzallah, Jumana Amawi, Manal Abbas, Wafa'a Hannini, Maha Abu Seido, Marium Abu-Albasal, Ameera Taqi Addin, Suzan Matar, Rasha Al-Taieh, Esra'a Abdussalam, Shereen Musleh, Tala Al-Areed, Lubna Tahtamouni, Fatin Al-Khayat, Saba Shbailat, Sundus Harfeel, Lubna Abdulaziz, Hedaya,

I would like to thank my colleagues; Suha Shwayat for her assistance in the morphological study, Nedal Abu Laban to teach me how to prepare the bony elements and Sa'ed Akkawi for his valuable help in the histological study.

My great thanks feelings that are presented to my parents would not be measurable, because of being so patient during the study period and all time. Without the encouragement they are offering to me I could never pass any work. My deep thanks are offered to my brothers and their families, my sisters and their families and my little sister Neda'a for being always around giving a hand whenever needed. I would like finally to record my great thanks to my fiance Ayman and his family for their continuous support they offered.

## List of contents

	<u>Page</u>
*****	
COMMITTEE DECISION.....	ii
DEDICATION.....	iii
ACKNOWLEDGEMENT.....	iv
LIST OF CONTENTS.....	vi
LIST OF TABLES.....	x
LIST OF FIGURES .....	xi
ABSTRACT (IN ENGLISH).....	xvii
1. INTRODUCTION.....	1
2. LITERATURE REVIEW.....	7
2.1 The Taxonomical Status of <i>Malpolon monspessulanus</i> <i>insignitus</i> .....	8
2.2 The External Morphology.....	9
2.3 The Anatomy of the Skull.....	10
2.4 The Anatomy of the Head Muscles.....	12
2.5 The Anatomy of the Vertebrae.....	14
2.6 The Anatomy of the Reproductive System.....	15

2.6.1 The Female Reproductive System.....	15
2.6.2 The Male Reproductive System.....	16
2.7 The Digestive Tract.....	17
2.7.1 The Anatomy of the Digestive Tract.....	17
2.7.2 The Histology and Histochemistry of the Digestive Tract .....	18
2.8 The Duvernoy's Gland.....	21
3. Materials and Method.....	23
3.1 The External Morphology.....	24
3.2 The Anatomy of the Skull.....	28
3.3 The Anatomy of the Head Muscles.....	28
3.4 The Anatomy of the Vertebrae.....	28
3.5 The Anatomy of the Reproductive System.....	29
3.6 The Digestive Tract.....	29
3.6.1 The Anatomy of the Digestive Tract.....	29
3.6.2 The Histology and Histochemistry of the Digestive Tract .....	29
3.7 The Duvernoy's Gland.....	30
4. The Results.....	40



4.1 The External Morphology.....	41
4.2 The Anatomy of the Skull.....	49
4.3 The Anatomy of the Head Muscles.....	62
4.4 The Anatomy of the Vertebrae.....	73
4.5 The Anatomy of the Reproductive System.....	79
4.5.1 The Female Reproductive System.....	79
4.5.2 The Male Reproductive System.....	82
4.6 The Digestive Tract.....	86
4.6.1 The Anatomy of the Digestive Tract.....	86
4.6.1.1 The Esophagus.....	86
4.6.1.2 The Stomach.....	89
4.6.1.3 The Intestine.....	91
4.6.2 The Histology and Histochemistry of the Digestive Tract .....	92
4.6.2.1 The Esophagus.....	92
4.6.2.2 The Stomach.....	99
4.6.2.3 The Small Intestine.....	109
4.6.2.4 The Large Intestine.....	115
4.6.2.5 The Cloaca.....	118



4.7 The Duvernoy's Gland.....	120
5. Discussion and Conclusion.....	122
5.1 The External Morphology.....	123
5.2 The Anatomy of The Skull.....	123
5.3 The Anatomy Of The Head Muscles.....	128
5.4 The Anatomy Of The Vertebrae.....	131
5.5 The Anatomy of the Reproductive System.....	132
5.5.1 The Female Reproductive System.....	132
5.5.2 The Male Reproductive System.....	133
5.6 The Digestive Tract.....	134
5.6.1 The Esophagus.....	134
5.6.2 The Stomach.....	142
5.6.3 The Small Intestine.....	145
5.6.4 The Large Intestine.....	148
5.6.5 The Cloaca.....	148
5.7 The Duvernoy's Gland.....	149
6. References.....	151
7. Appendix.....	170
8. ABSTRACT (IN ARABIC).....	176

LIST OF TABLES

Page

\*\*\*\*\*

1. Pholidosis of *Malpolon monspessulanus insignitus* .....45

2. Length of the testes and distance from the snout..... 83

3. Proportions of the digestive tract organs.....87

4. Number of teeth carried on each dentiferous bones  
in the montpellier snake and other species  
belonging to different families ..... 127

5. The digestive organs mucosal structure and reaction  
with PAS and AB ..... 137

LIST OF MAPS

1. distribution of the montpellier snake in Jordan.....3

## LIST OF FIGURES

	Page
*****	
1. Counting of the middorsal scales.....	25
2. Measurements of SV, TL and TBL.....	25
3. Types of anal and subcaudal scales.....	25
4. Lateral view of the snake head.....	27
5. Dorsal view of the snake head.....	27
6. Ventral view of the snake head.....	27
7. Ventral view of the montpellier snake.....	42
8. Dorsal view of the montpellier snake.....	43
9. Dorsal view of the montpellier snake head.....	43
10. Lateral view of the montpellier snake head.....	44
11. Ventral view of the montpellier snake head.....	44
12. Dorsal view of the montpellier snake skull.....	50
13. Ventral view of the montpellier snake skull.....	52
14. Lateral view of the montpellier snake skull.....	53
15. Ventral view of the lower jaw of the montpellier snake....	60

16. The outermost layer of the head muscles of the montpellier snake.....	63
17. The intermediate layer of the head muscles of the montpellier snake.....	66
18. The deep layer of the head muscles of the montpellier snake .....	68&69
19. Intermandibular layer of head muscles, ventral view.....	72
20. The first vertebra of the montpellier snake, Atlas.....	74
21. The second vertebra of the montpellier snake, Axis.....	74
22. The third vertebra of the montpellier snake.....	76
23. The trunk vertebra.....	78
24. The cloacal vertebra.....	78
25. The female reproductive system.....	80
26. The male reproductive system.....	81
27. The hemipenes of the montpellier snake.....	84
28. The anatomy of the cloaca.....	85
29. The digestive tract of the montpellier snake.....	90
30. The gastrointestinal junction of the montpellier snake.....	90



31. The layers of the middle part of the esophagus, H&E, X462.....	94
32. The skeletal muscles of the muscularis externa of the first part of the esophagus, H&E, X175 .....	95
33. The mucosa and submucosa of the anterior part of the esophagus, H&E, X350.....	95
34. General view of the last third of the esophagus, H&E, X140 .....	96
35. The mucosa and submucosa of the last third of the esophagus, H&E, X350 .....	96
36. Reaction of the esophageal first part with PAS and AB, X700 .....	97
37. The second part of the esophagus with FG, X280.....	97
38. The layers of the third part of the esophagus with VG, X140 .....	98
39. The mucosal layer of the cardiac portion of the stomach, H&E, X350.....	102
40. The muscularis externa and serosa of the stomach, H&E, X175 .....	102

41. The epithelium of the cardiac region of the  
 Stomach react positively with PAS, X350 ..... 103

42. The gastric mucosa in the fundus,  
 H&E, X231 ..... 103

43. The surface epithelium of the fundic region,  
 H&E, X875 ..... 104

44. The mucous glands of the fundic region,  
 H&E, X875 ..... 104

45. The serous glands of the fundic region,  
 H&E, X875 ..... 105

46. General view of the pyloric region,  
 H&E, X175 ..... 105

47. The mucosal layer of the pylous,  
 H&E, X350 ..... 106

48. The fundic region of the stomach,  
 FG, X600 ..... 106

49. Reaction of the fundic region mucosa of the stomach  
 with PAS, X462 ..... 107

50. Reaction of the fundic region mucosa of the stomach with PAS/AB2.5, X350 .....	107
51. Reaction of the pyloric region mucosa with PAS/AB1, X300 .....	108
52. The muscularis externa of the pyloric region of the stomach, FG, X115.5 .....	108
53. General view of the small intestine layers, H&E, X35.....	111
54. The muscularis externa of the small intestine, H&E, X231 .....	111
55. The serosal layer of the small intestine, H&E, X462 .....	112
56. The villus of the small intestine, MTS, X115.5.....	112
57. Different layers of the small intestine, FG, X115.5 .....	113
58. Submucosa and muscularis externa of the small intestine, VG, X87.5 .....	113

59. The positive reaction of the intestinal epithelial cells with AB2.5, A:X70, B:X350 .....	114
60. The mucosal layer of the large intestine, H&E, X175 .....	116
61. The reaction of the intestinal epithelial cells with AB2.5, X174 .....	116
62. The different layers of the large intestine, MTS, X115.5 .....	117
62. General view of the cloaca, H&E, X56 .....	118
63. The layers of the cloaca with FG, X135 .....	119
65. The location of the Duvernoy's gland of .....	121
66. The percentages of the digestive organs to the snout-vent length in the montpellier snake .....	135



## Abstract

MORPHOLOGICAL AND ANATOMICAL STUDY OF  
 CERTAIN SYSTEMS IN THE MONTPELLIER SNAKE,  
*Malpolon monspessulanus insignitus*, (Geoffroy, 1827).

Family Colubridae

By

Shifa'a Abdul-Hameed Awwad

Supervisor

Professor Ahmad M. Disi

The present investigation deals with the montpellier snake, *Malpolon monspessulanus insignitus* (Colubridae, Geoffroy, 1827). *M. m. insignitus* has a long cylindrical body with a length reaching 179cm. The dorsal side of this taxon has dark gray-olive color which lightens caudally with keeled 19 scales. The ventral side is yellow but interrupted by pink region at the middle site with wide 156-179 wide scales. The head is long triangle-shaped structure and distinct from the neck with large eyes.

The other subject discussed through this study is the anatomy of the skull, head muscles and vertebrae. The skull is triangular in shape and attains the classical colubrid skull pattern by being constructed of solid bones. The most distinct feature of *M.m.insignitus* skull is the narrow width of the frontal sutured bones, which is resulted from having large fossae orbitalis for the well distinguished eyes. The head muscles of the montpellier snake are well attached to its skull bones for better duty performance. The exist muscles of the adductor externus complex are well developed. The two muscles belonging to this complex which are absent in the montpellier snake are the muscle compressor glandulae and the muscle anguli oris. The vertebral column of *M.m.insignitus* shows variation in

vertebral shape and size among the different studied regions ( the first three, the trunk and the cloaca).

The anatomy and histology of the alimentary tract of the montpellier snake have got considerable attention and careful examination throughout this project. The elongated cylindrical body form of the snake has resulted in having elongated-packaging system of the internal viscera. The esophagus occupies the majority of the snout-vent length among the other digestive organs. This investigation reveals that the lining of the different digestive organs is not constant along the digestive tract. Simple layer of epithelial tissue is found in the esophagus and intestinal mucosa, while simple columnar epithelium is illustrated in the stomach. The distribution of the mucopolysaccharides is carried out by using PAS and AB procedures. The acidic mucopolysaccharides are found along the digestive tract but with higher density in the esophageal goblet cells. The submucosal layer is present in the studied digestive organs. The gastric muscularis externa has the highest level of development in comparison to the other parts. The layer of serosa starts to appear not before the last part of the esophagus.

The anatomical study of the female and male reproductive systems is achieved. The anteriorly situated and larger size of the right side organs is noticed in both sexes. Furthermore, a description of the hemipenis is done and compared with the other species of the same genus. The comparison indicates that the morphology of the hemipenis is not enough in the taxonomy of this genus at the species level.

This research deals also with the anatomy of the main venom gland, the Duvernoy's gland, of the montpellier snake. The gland is exposed immediately after skin removal and is not covered by the head muscles.

This study is the first anatomical and histological document that deals with *Malpolon monspessulanus insignitus*. That does not mean that further investigations are recommended for better understanding for this taxon and for the family Colubridae.

**1**

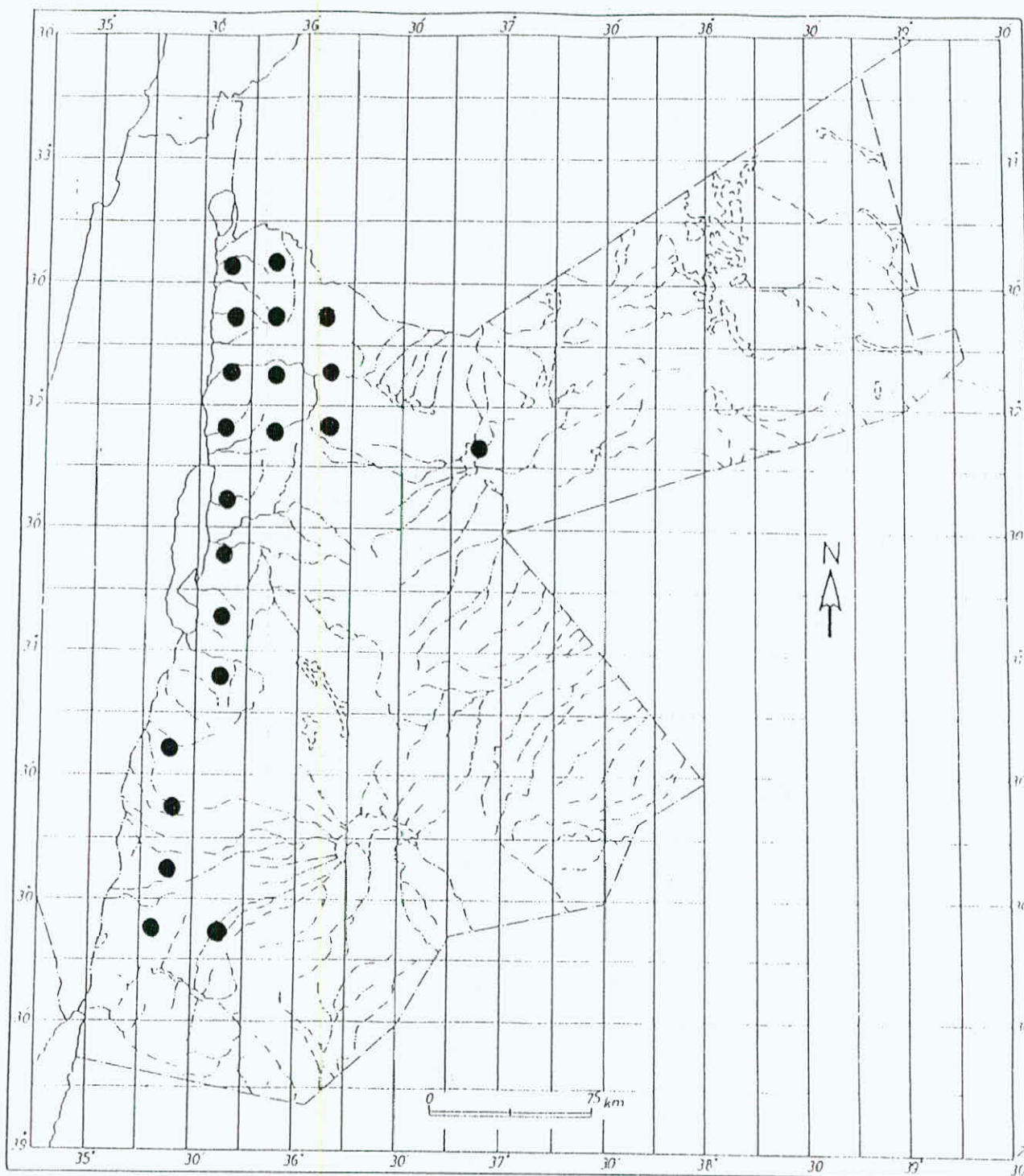
# **INTRODUCTION**



*Malpolon monspessulanus insignitus* (Geoffroy, 1827), the montpellier, snake is a member of the family Colubridae. This genus has a wide distribution in the Mediterranean biotope. It inhabits the region and extends between Yugoslavia eastward to the Caspian sea, the Middle East and North Africa (Gasperetti, 1988). It is the eastern montpellier snake, while the western one is *M.m.monspessulanus* (Woerkom, 1982). The occurrence of *M.m.insignitus* was also reported in the northern part of the Golan, Mountain Hermon (Sivan and Werner, 1992) and in Lebanon up to an altitude of 1700 m. (Hraoui Bloquet, 1982). The distribution of *M.m.insignitus* in Jordan was surveyed by many authors. It was reported in Ma'an governorate (Amr *et al.*, 1994), in Karak, Tafila, Ash-Shawbak and Mutah (El-Oran *et al.*, 1994).( Map 1)

Limited number of studies had dealt with the anatomy of snake skulls, head muscles and vertebrae. Number of studies were done on the anatomy of viprid head( Dullemeijer, 1956, 1958), of *Bitis arientans*( Bolt and Ewer, 1964), of *Eryx jayakari*(Mohammad, 1991) and members of the family Atractaspidae (Underwood and Kochva, 1993). Other anatomists





Map (1): The distribution of *M.m.insignitus* in Jordan.

- Recorded sites

studied the skull of some species of the family Colubridae (Haines 1957, Cundall 1981 and Cundall and Rossman 1984). Further literatures have dealt with the head muscles of snakes from the family Viperidae (Haas, 1952; Kochva, 1962), Boltt and Ewer (1964) studied the functional anatomy of head muscles of *Bitis arietans*. Cundall (1983 and 1986) concentrated his study on the head muscles of snakes belonging to the family Colubridae.

Little attention has been paid to the anatomy of the snake reproductive system, the anatomy of the female genitalia of the Atractaspidae (Underwood and Kochva, 1993). Detailed study was performed on the histology of both male reproductive system (Fox, 1965) and female reproductive system for snakes belong to the family Typhlopidae and family Leptotyphlopidae (Fox, 1956).

The elongated body form of the snakes had attracted the attention of many anatomists to study the arrangement and the physiology of their internal organs. Bergman (1965) dealt with the internal anatomy of the snake *Calamaria multipunctata* and carefully measured the dimensions and the relative position of each organ for the whole snake body. Several authors had studied the anatomy and the internal relief, the gross anatomy, of the digestive

tract of reptiles: the gecko (Chou,1977), the lizards (Bishai,1959) and snakes (Frenkel and Kochva,1970 and Parson and Cameron, 1977). Further investigations dealt with the histology and histochemistry of the alimentary canal: the gecko (Chou 1977; Dehlawy *et al.*, 1987 and Amer *et al* 1988), lizards (Bishai 1959, Zaher *et al* 1987 and Dehlawy *et al* 1988) and snakes (Frenkel and Kochva 1970 and Amer *et al* 1987).

The cephalic glands of the snakes were previously studied. The concentration was focused on the venomous snakes and their venom glands: *Vipera palaestinae* (Nakar *et al.*, 1986, Kochva, 1978 and Kochva and Gans, 1965), *Atractaspis* (Kochva, 1967). The biochemical composition of the venomous gland secretion was well examined (Kochva, 1978). Also, the secretion of the Duvernoy's gland was studied biochemically (Rosenberg *et al*, 1986 and 1992). However, none of the previous studies had dealt specifically with *M.m.insignitus* in details. There were limited studies on the anatomy, histology and histochemistry of the subject of this study, *Malpolon monspessulanus insignitus*. Only Jacobshagen (1920) studied the internal relief of the digestive tract of *M. monspessulanus* but there were no detailed studies about the



anatomy and the histology of this subspecies. Therefore, this study aims to deal with the following aspects of *Malpolon monspessulanus insignitus*:

- The external morphology
- The anatomy of the skull.
- The anatomy of the head muscles.
- The anatomy of the vertebrae.
- The anatomy of male and female reproductive systems.
- The anatomy and histology of the digestive tract.
- The anatomy of the Duvernoy's gland.



**2**

**LITERATURE**

**REVIEW**

## 2.1 The Taxonomical Status of *Malpolon monspessulanus insignitus*

(Romer, 1976)

Kingdom Animalia

Phylum Chordata

Subphylum Vertebrata

Class Reptilia

Subclass Lepidosauria

Order Squamata

Suborder Ophidia

Superfamily Colubroidea

Family Colubridae

Subfamily Colubrinae

Genus *Malpolon*

Species *monspessulanus*

Subspecies *insignitus* (Geoffroy, 1827)

Common name: The montpellier snake

## 2.2 The External Morphology

Reed and Marx (1959) described four specimens of *Malpolon monspessulanus insignitus* from Iraq. They reported 17 scales in the middorsal body, 8-9 supralabials, 10-11 infralabials, 1 preocular, 2-3 postoculars and 2-3 temporals. The anal plate was found to be divided. One male specimen had 174 ventrals and 90 subcaudals with total length =796 mm and the tail resembles 0.24 of the total body length. On the other hand, the three females had 172-174 ventrals and 89 subcaudals, the total length was 883 mm and the tail equals to 0.25 of the total length.

Amr *et al.* (1994) described a specimen of *M.m.insignitus* from Ma'an, south of Jordan. The studied sample had 86 subcaudals and 16 scales in the middorsal part of the body. The snout-vent length was 1110 mm, while the tail was 360 mm in length.

492034

El-Oran *et al.* (1994) studied the snakes of the southern part of Jordan. The nine examined specimens of *M.m.insignitus* had 2 loreal, 159-195 ventral, 89-97 subcaudal and 19 middorsal scales. Also, the adult individuals were brown to gray, while the juveniles had lighter color with dark brown spots on beige background dorsally.



### 2.3 The Anatomy Of The Skull

Limited studies dealt with the anatomy of snake skull, although anatomy as a science had started in the 19<sup>th</sup> century. In 1956, Dullemeijer described the anatomy of the head of the common viper, *Vipera berus*. In his further investigation (1958), he added the anatomy of various species of the family Viperidae for the purpose of comparison. He found that the viperid skull is characterized by having a small triangular shape and short maxillae holding two large hollow fangs anteriorly.

Boltt and Ewer (1964) argued about the theory of fang erection which was created by Marshall (1962) and also supported by Young (1962). This theory suggested that the movement of the lower end of the quadrate bone which then is transmitted to the pterygoid bone and thence to the other bones of the upper jaw, is the source of maxilla rotation and fangs erection. After they have examined the Puff adder *Bitis orientans*, Boltt and Ewer (1964) rejected Marshall's theory and claimed that the fang erection is caused by the movement of pterygoid bone by its own muscle.

Haines (1967) studied the skulls of number of colubrid snakes, trying to find out whether if there are differences among genera and species. He suggested that there is a great uniformity in the skulls of colubrid snakes: having 43 bones with the same position and relation one to another.

Variation also exists: the shape and the size of the skull reflect the size of ingested prey as suggested by Haines.

Cundall (1981) utilized the genera *Opheodrys* and *Entechinus* (Colubridae) as study models. He found that the two skulls displayed the generalized colubrid pattern.

In 1984, Cundall and Rossman considered 97 different measurements of the skull of two genera of the family Colubridae: *Farancia* and *Pseudoeryx* for taxonomical purposes. The two genera have very solidly constructed skulls that retain the basic colubrid pattern. However, major differences in the shape of few bones were found between the two genera: dorsal lamina of the nasal bone, premaxilla, ventral tip of the postorbital, supratemporal and lateral surface of the posterior half of the pterygoid.

The skeletal elements of the boid snake *Eryx jayakari* were studied by Mohammad (1991). He described the external morphology of this species and made description for each bone in the skull. He tried to find out the similarities exist among this species and other boid snakes which have been studied before (*E.j.jaculus*, Boulenger 1893, *E.colubrinus*, Marx

1968; *E.j.jaculus*, Haas and Werner 1969, *E.jayakari* Leviton and Alderich 1984; and Disi 1985).

Underwood(1992) examined the skulls of 31 different species of boid snakes. The results obtained were used to construct a dendogram that clarified the relationship among the genera of that group.

Underwood and Kochva(1993) studied the anatomical aspects of the skulls in the family Atractaspidae:*Homoroselaps* and *Atractaspis*. They considered the skull to be an important tool to study the correct taxonomical status of any genus.

## 2.4 The Anatomy Of The Head Muscles

The feeding mechanism of the snakes always draws a big question mark, since the snake is capable to swallow a large prey that exceeds 2-3folds of the snake's diameter. The study of the anatomy of the head muscles may participate in better understanding the snake feeding mechanism.

Haas (1952) described the head muscles of *Causus* species. He concentrated on the muscle adductor externus complex. His purpose was to



understand the envenomation process which is thought to be achieved by the muscle adductor mandibulae externus superficialis. In addition, he compared the head muscles of *Causus sp.* with other solenoglypha.

Kochva(1958) utilized the viper *Vipera palaestinae* to study its head muscles. His study included the morphology, origin and insertion of each muscle. In addition, he discussed the role of each muscle in fang erection and venom ejection. In 1962, he continued his study to include a group of solenoglypha. He described the head muscles of 42 species and compared among them.

Kochva(1963) proposed a study on the embryos of the viper, *Vipera palaestinae*. He carefully measured the developmental events in the embryos in order to examine the differentiation of the head muscles, venom gland and fangs of this species. He focused on the muscle compressor glandulae which had been suggested to work in venom ejection.

Boltt and Ewer (1964) suggested an explanation of the feeding in the puff adder *Bitis arietans*. They correlated the structure of the skull with its muscles and how could the muscle contraction creat a movement in a bone, consequently causing mouth opening and prey swallowing. The role

of muscles in erection and retraction of fangs during biting were also investigated.

Cundall (1983) studied the swallowing process in four different colubrid genera. Moreover, Cundall (1986) listed the differences that may occur in the head muscles of three different genera of colubrids (*Entechinus*, *Opheodrrys* and *Symphimus*). Interspecific variations in the muscle adductor mandibulae externus superficialis and the muscle pseudotemporalis were found. On the other hand, the muscle pterigoideus has interspecific as well as intraspecific variation. Furthermore, the muscles: protractor quadrati, protractor pterigoidei, retractor pterigoidei and retractor vomeris had variations among genera.

## **2.5 The Anatomy Of The Vertebrae**

Mohammad(1991) studied the vertebral column of the boid snake *Eryx jayakari*. He described and illustrated the vertebrae of different regions. Different shapes and characters of vertebrae from different regions along the vertebral column were found.

Underwood (1992) used the trunk vertebra as a model to classify 31 different species of the family Boidae. Moreover, Underwood and Kochva (1993) studied the trunk vertebrae of different species belonging to the family Atractaspidae to draw a dendogram for this family

## **2.6 The Anatomy Of The Reproductive System**

### **2.6.1 The Female Reproductive System**

Underwood and Kochva (1993) studied the anatomy of the female reproductive system in a group of snake burrowers. They found individual variation in the sinus of *Aparallactus* which suggested that the sinus morphology was related to the reproduction condition of the animal. Also, when they studied the female genitalia of *Psamophis* and *Psammophylax*, which are highly derived snakes with small hemipenes, they suggested that the condition of the female tract may well be secondary.

Fox (1956) utilized two species of the genus *Thamnophis* to study their female reproductive tract anatomically and histologically. The majority of the tract was lined by ciliated epithelial cells. The seminal receptacles which were thought to be the site of sperm storage, were lined by simple layer of nonciliated epithelium. The lining of the receptacles had vaculated cytoplasm which was found to be invaded by the sperms when the receptacles were filled with the sperms. The seminal receptacles were



abundant at the corners of the oviduct folds at the base of the infundibulum. The value of such receptacles was suggested not only to be as a physical refuge but also to provide the sperms with nutrition or chemical arrest activity.

### 2.6.2 The Male Reproductive System

Fox (1965) examined the male genitalia and ducts of species belonging to the family Typhlopidae and Leptotyphlopidae. The testes of the studied genera were illustrated as lobed ones, with lobes separated by means of connective tissue.

Schatti (1987 and 1988) proposed two investigations to find out the phylogenetic characters of the genus *Coluber*. He included the morphology of the hemipenis and the insertion of the muscle retractor penis magnus in the two studies beside the external morphological features.

Shwayat (1998) tried to utilize the hemipeneal morphology in her study to classify four species of the genus *Eirenis* in Jordan. Her results revealed that the studied hemipenes attained high level of similarity. She concluded that the morphology of hemipenis is not a proper tool in *Eirenis* classification. In contrast, Branch (1986) found enough interspecific

variations among the hemipenes of the African Python species, which may enable the herpetologists to use as taxonomical tool in this genus.

## **7 The Digestive Tract**

### **2.7.1 Anatomy Of The Digestive Tract**

Bishai (1959) studied the anatomy of the alimentary tract of the lizard *Varanus grieseus*. The esophagus was described as a funnel-shaped tube in the most anterior part of the body. The stomach was found to have a wider diameter than the esophagus. The intestine began as wide coiled tube, then narrow posteriorly. The caecum was found to be absent in *Varanus*, while the cloaca was short.

Frenkel and Kochva (1970) focused on the visceral anatomy and histology of the viper, *Vipera palaestinae*. They only included illustrations for the results they obtained. Chou (1977) had studied the anatomy of the digestive tract of the gecko *Gehyra mutilata*. He described the packaging and the orientation of each organ in the alimentary canal. The most ventral organs were found to be the liver and the gall bladder. The stomach was found to be situated on the left side just under the liver, while the small intestine bent toward the right side and ended at the middle side of the body where the wide large intestine began.

Zaher and his co-workers (1987) studied the anatomy of the alimentary tract of the lizard *Acanthodactylus ophedreus*. They indicated that it confirmed the reptilian pattern of the alimentary tract.

### 2.7.2 Histology And Histochemistry Of The Digestive Tract

Frenkel and Kochva(1970) had studied the histology of the digestive tract of *Vipera palaestinae* in illustrations, but without giving any description or discussion about it. Dehlawy and Zaher (1985a) studied the histology of the mucosal epithelium of the alimentary canal in the lizard *Acanthodactylus boskianus*. They found out that the esophageal epithelium had mixed two types of epithelial cells; simple columnar ciliated epithelium and goblet cells with the absence of the esophageal glands. The gastric mucosa was formed of simple columnar epithelial cells. Also, the stomach contained both fundic and pyloric glands. The intestinal mucosa was composed of three types of cells: absorptive, endocrine and Paneth cells. The caecum and the colon had mixed cell types, simple columnar and goblet cells, while the rectum lacked any type of cells other than the simple columnar. The previous two authors (1985b) had also performed a similar study on the alimentary tract of the gecko *Pristurus rupestris*. High similarities were found between the two studied organisms, eventhough they belong to different families.



Amer *et al.* (1987) focused on the distribution of the mucopolysaccharides in the alimentary canal of the viper *Echis carinatus*. They pointed out that the acid mucopolysaccharides were well distributed in the esophageal mucosa. However, the neutral mucopolysaccharides were dominated in the gastric mucosa. In addition, the presence of both types of mucopolysaccharides was noticed in the intestinal mucosa.

The histology of the alimentary canal of the lizard *Acanthodactylus ophedreus* was studied by Zaher and his co-workers in 1987. They figured out that the esophageal mucosa has simple columnar epithelium beside the goblet cells but devoided of the esophageal glands. On the other hand, the stomach was found to have two types of glands , the fundic and the pyloric. The intestinal mucosa contained the columnar, goblet, endocrine and paneth cells. The mucosa of the large intestine was composed of columnar and goblet cells.

The distribution of the mucopolysaccharides in the lizard *Acanthodactylus boskianus* was examined by Dehlawy *et al.* (1988a). The acid mucopolysaccharides were mainly distributed in the esophagus and intestine, while the stomach was restricted to contain the neutral mucopolysaccharides.

Amer *et al* (1987) examined the localization pattern of the mucopolysaccharides in the alimentary tract of the gecko *Tarentola annularis* . Few neutral mucopolysaccharides were found, while the acidic mucopolysaccharides were seen in the goblet cells, and highly concentrated toward the gut lumen.

A histochemical localization of mucopolysaccharides was carried out by Dehlawy and his associates (1988b) in the alimentary canal of the lizard *Uromastix philbyi* . The esophageal goblet cells were rich in acid mucopolysaccharides. The intestinal mucosa contained less amount of acidic mucopolysaccharides. The neutral mucopolysaccharides were located in the gastric mucosa. Dehlawy *et al.* (1987) studied the mucopolysaccharides distribution along the alimentary tract of the gecko *Pristurus purestri* . The goblet cells of the esophagus were rich in acidic mucopolysaccharides, while the neutral ones were found in the gastric mucosa. The glycogen was well distributed among the intestinal mucosa.

## 2.8 Duvernoy's Gland

Kochva(1965) conducted a study that dealt with the developmental events of the venom gland in the opisthoglypha *Telescopus fallax* and the aglypha *Thamnophis sirtalis* (Colubridae). He suggested that the origin of the venom gland was the common primordium.

Kochva and Gans(1970) studied the main venom gland of various species belonging to the following families: Viperidae, Elapidae and Colubridae. They focused on the phylogeny of Duvernoy's gland, venom gland in Viperidae and Elapidae and their apparatuses. Venom synthesis and secretion were also included in their study. The Duvernoy's gland of the colubrids; *Natrix*, *Spalerosophis* and *Malpolon monspessulanus* had been illustrated in their investigation.

Kochva and Wollberg(1970) proposed a study to examine the taxonomic status of the genus *Elaps*. This genus was previously removed from the family Elapidae and included in the family Colubridae. However, the comparative study of the venom gland of this taxon with those of the colubrids, suggested that it must be retained in the family Elapidae.

Rosenberg *et al.*(1986) reviewed the literatures that dealt with the colubrid's Duvernoy's gland concerning the structural, functional and



phylogenetic points of view. They described the gland and its connection with the rear maxillary teeth. The mild sequences caused by the bite of the colubrids may have resulted from the morphology of the delivery system or lack of potent toxins as they suggested. These mild sequences included the severe impair in the motor activity, respiratory and locomotory which were caused by the sub-lethal dose of the secretion injected in mice. The analysis of the secretion revealed the presence of proteases and esterases, one of the latter: phospholipase A2 which was detected in the secretion of *Malpolon*.

Taka'cs(1986) described the structure of Duvernoy's gland of *Mapolon monspessulanus*. He also discussed the venom apparatus as a whole and the discharge mechanism. Also, the venom apparatus of *Vipera ammodytes* was studied for comparison purposes between the two genera phylogenetically.

Rosenberg *et al.*(1992) studied the effect of one protein isolated from the secretion of *Malpolon monspessulanus* Duvernoy's gland. The toxic protein (CM-b) was found to induce haemorrhage in the lung of mice after profuse bleeding from the nostrils was noticed.

**3**

**MATERIALS**

**AND**

**METHODS**

This study is basically dependent on the available fresh and preserved specimens of *Malpolon monspessulanus insignitus* kept in the museum of Jordan University (JUM) Department of Biological Sciences, Amman/Jordan and Jordan Natural History Museum at Yarmouk University (YUM),. Two males were used for the histological study. Forty one preserved specimens were surveyed for the morphological and anatomical studies (3 females, 32 males and 6 juvenile).

### 3.1 The External Morphology

The following characteristics were taken into consideration in the external morphological examination:

- The middorsal scales are counted at the middle of the body (MDS) (Fig. 1).
- The ventral scales are counted from the first ventral scale down to the one before the anal plate (VS) (Fig. 6).
- The subcaudal scales are counted from the first scale posterior to the claoaca on the ventral side to the tail tip (SCS) (Fig. 3).
- Snout-vent length is measured from the snout to the tip of the vent (SV) (Fig. 2).



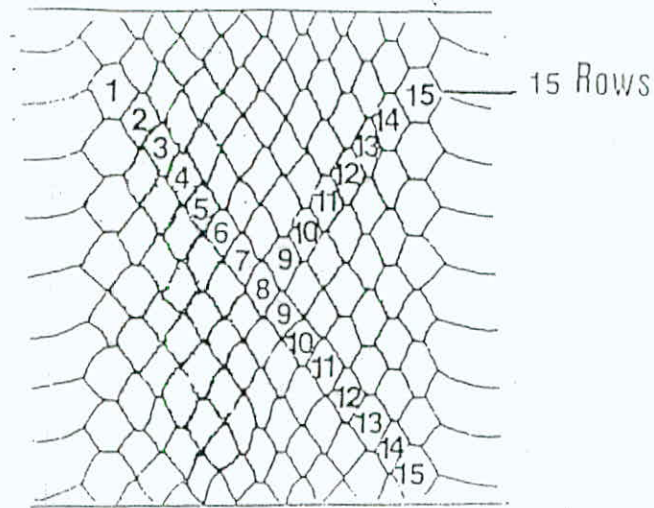


Fig. (1): Counting of the middorsal scales




Fig. (2): Measurements of SV, TL and TBL.

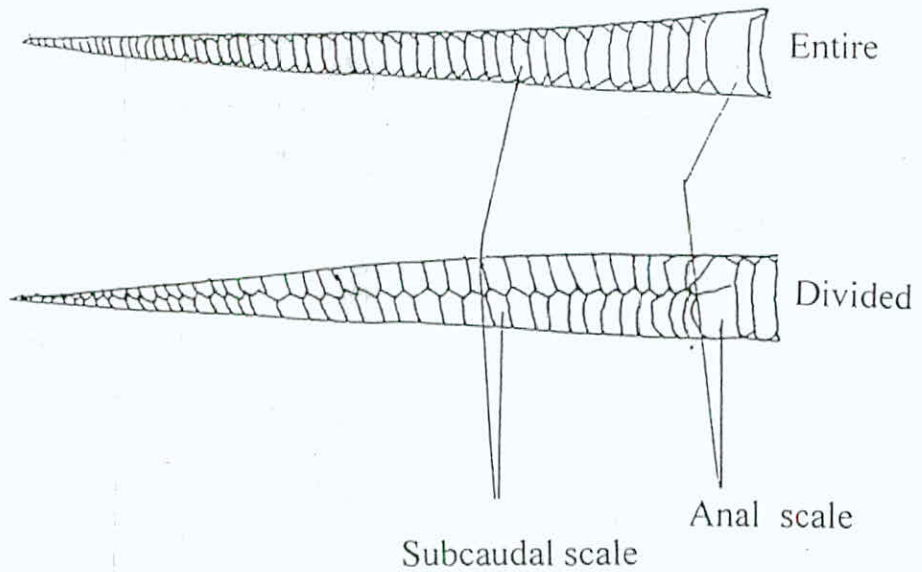


Fig. (3): Types of anal and subcaudal scales

- The tail length is the distance between the vent and the tip of the tail (TL) (Fig. 2).
- The total body length is the sum of SV and TL. (Fig. 2).
- The length of the head is measured from the snout back to the angle of the head, while the width of the head is the distance between the two angles of the head. The height of the head is measured as the distance between the dorsal surface of the head to the ventral one of it. (Figs. 4&5)
- The upper labial and the lower labial scales are the ones that surround the mouth from the upper side and the ventral side respectively. (Fig. 4).
- The scales between the nasal scale and the preocular are known as the loreals. (Fig. 4)
- The scale which is anterior to the eye is the preocular, while the one above the eye is the supraocular and the ones behind the eye are the postoculars. (Figs. 4&5).
- The scales beyond the postocular are called the anterior temporal and the oblique row after them are the posterior temporal. (Fig. 4).

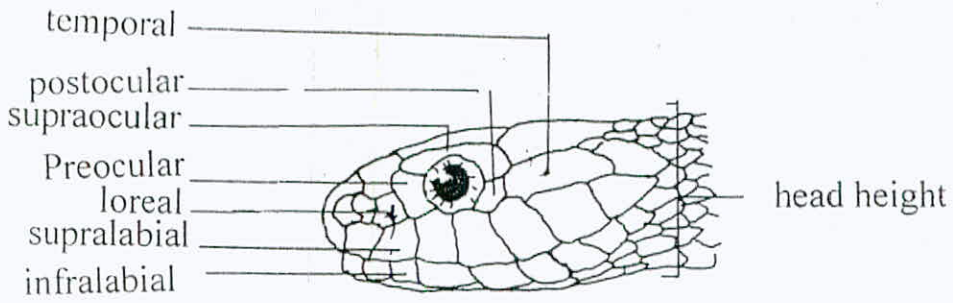


Fig. (4): Lateral view of the snake head.

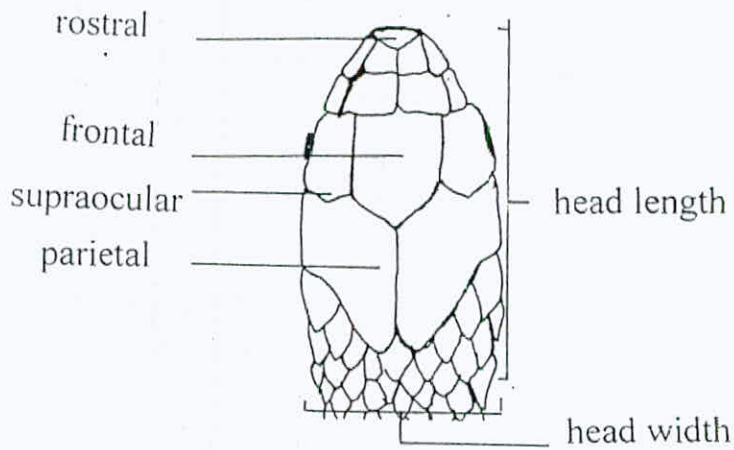


Fig. (5): Dorsal view of the snake head.

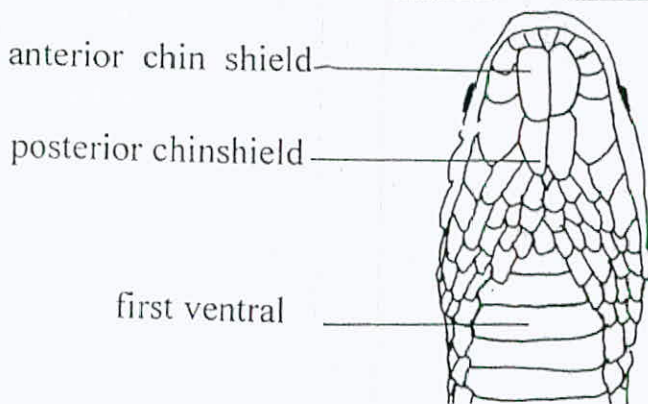


Fig. (6): Ventral view of the snake head.



### **3.2 The Anatomy Of The Skull**

Three heads from one fresh specimen and two preserved specimens were cut and the fleshy materials were removed gently by forceps. The skulls with the remnants of muscles were then boiled in borax solution (Abu Laban, 1999) for 1-3 hours. To whiten the cleaned skull, it was then soaked in 1% H<sub>2</sub>O<sub>2</sub> solution for 5-10 minutes. Also, drawings for the studied bones were made.

### **3.3 The Anatomy Of The Head Muscles**

The skin of the studied heads was peeled out and the underneath head muscles were examined. The superficial layer of the muscles was studied and drawn first, then the intermediate one and the deep layer was also examined and all were illustrated. Finally a study for the intermandibular layer of the head muscles was also done.

### **3.4 The Anatomy Of The Vertebrae**

Vertebrae from different regions of the snake vertebral column were selected to be studied; the first three vertebrae, the middle trunk region vertebrae and the cloacal vertebrae. The picked vertebrae were first cleaned from the skin and muscle surrounding it. The vertebral elements were boiled in borax solution for 1-3 hours then soaked in 1% H<sub>2</sub>O<sub>2</sub> solution for whitening (Abu Laban, 1999).

### **3.5 The Anatomy Of The Reproductive System**

The male reproductive system and the female reproductive system were studied from the preserved specimens of the montpelleir snake. The length of the right and the left testes was measured from the anterior tip of the testis to the posterior tip of each. The two systems were photographed using colored film ASA 100. The hemipenes were found readily everted.

### **3.6 The Digestive Tract**

#### **3.6.1 The Anatomy Of The Digestive Tract**

The ventral side of the available preserved specimens of *M.m.insignitus* was opened. The digestive organs were recognized and the length of each was measured from the anterior tip of the organ to the posterior one. A median incision was made along the alimentary canal to examine and describe the internal relief of the organs.

#### **3.6.2 The Histology And Histochemistry Of The Digestive Tract**

Two male specimens of *M.m.insignitus* were utilized for the histological section of this study. Each digestive organ was divided to three regions; the anterior, the middle and the posterior, from each region of the organ, small piece (5x5mm) was taken and fixed in 10% formalin and

Zenker solutions. Then the tissues were processed by automated processor in the Department of Pathology/ Faculty of Medicine in The University of Jordan.

### **3.7 Duvernoy's Gland**

The preserved specimens of the montpellier snake were used to study Duvernoy's gland anatomically. They were prepared by skinning the head and exposing out the gland. The location, morphology, texture and connection with the rear grooved fangs were examined.



The automated processor is programmed according to the following procedure:

<b>A. Fixation</b>	
Formalin I	1 Hour
Formalin II	1.5 Hour
<b>B. Dehydration</b>	
70% Ethanol	1 Hour
95% Ethanol I	1 Hour
95% Ethanol II	1 Hour
100% Ethanol I	1 Hour
100% Ethanol II	1 Hour
<b>C. Clearing</b>	
Xylene I	2 Hours
Xylene II	2 Hours
<b>D. Infiltration</b>	
Paraffin wax I	1.5 Hour
Paraffin wax II	1.5 Hour

When the processing is over the following steps were applied:

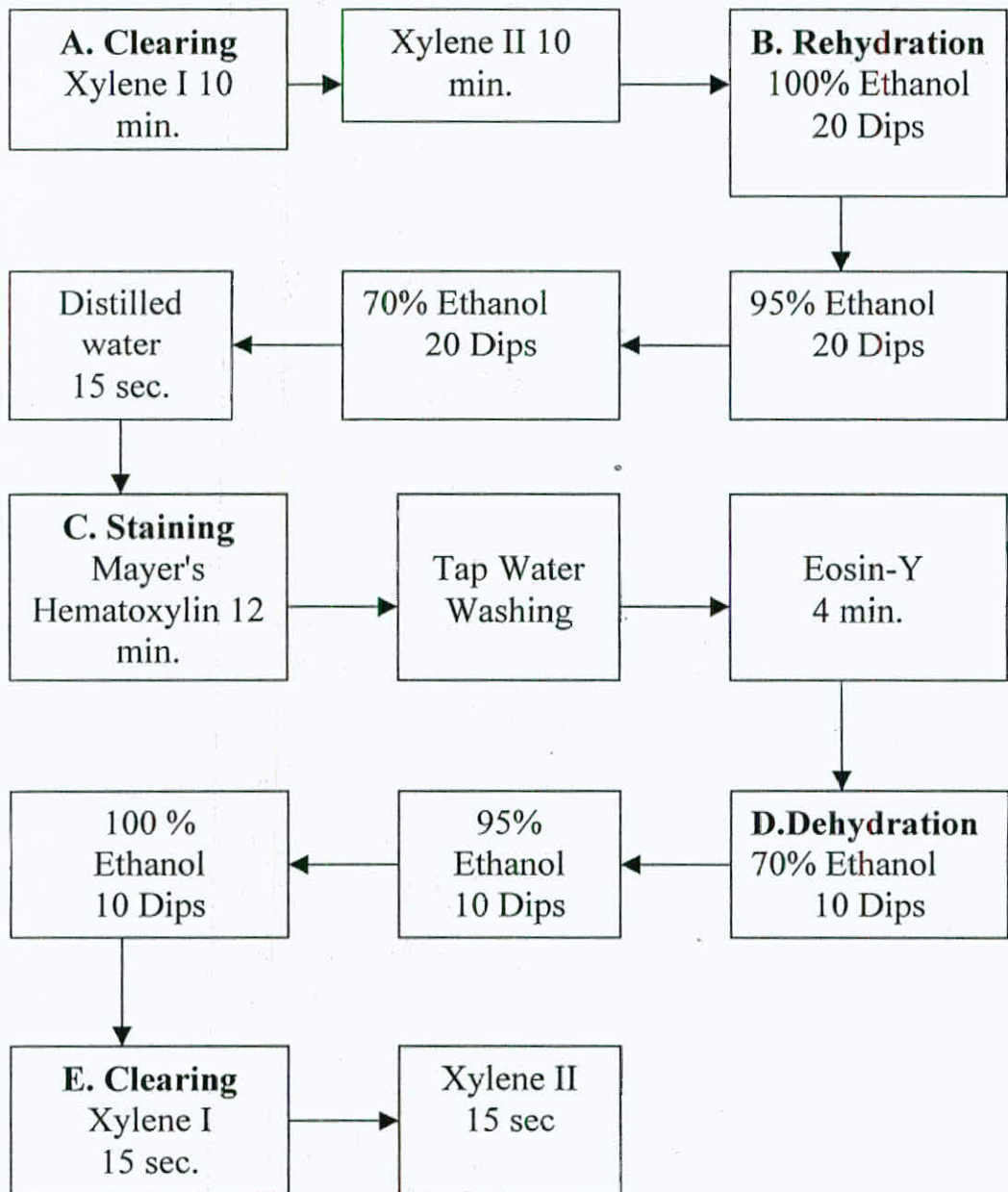
### **E. Embedding and Sectioning**

The small pieces of the examined tissues were embedded, each one in a metal block using paraffin wax. The wax blocks then were trimmed at and sectioned at 5 $\mu$ m thickness. The sections were mounted on microscopic slides using egg albumin.

## F. Staining

The slides were applied to the following staining procedures:

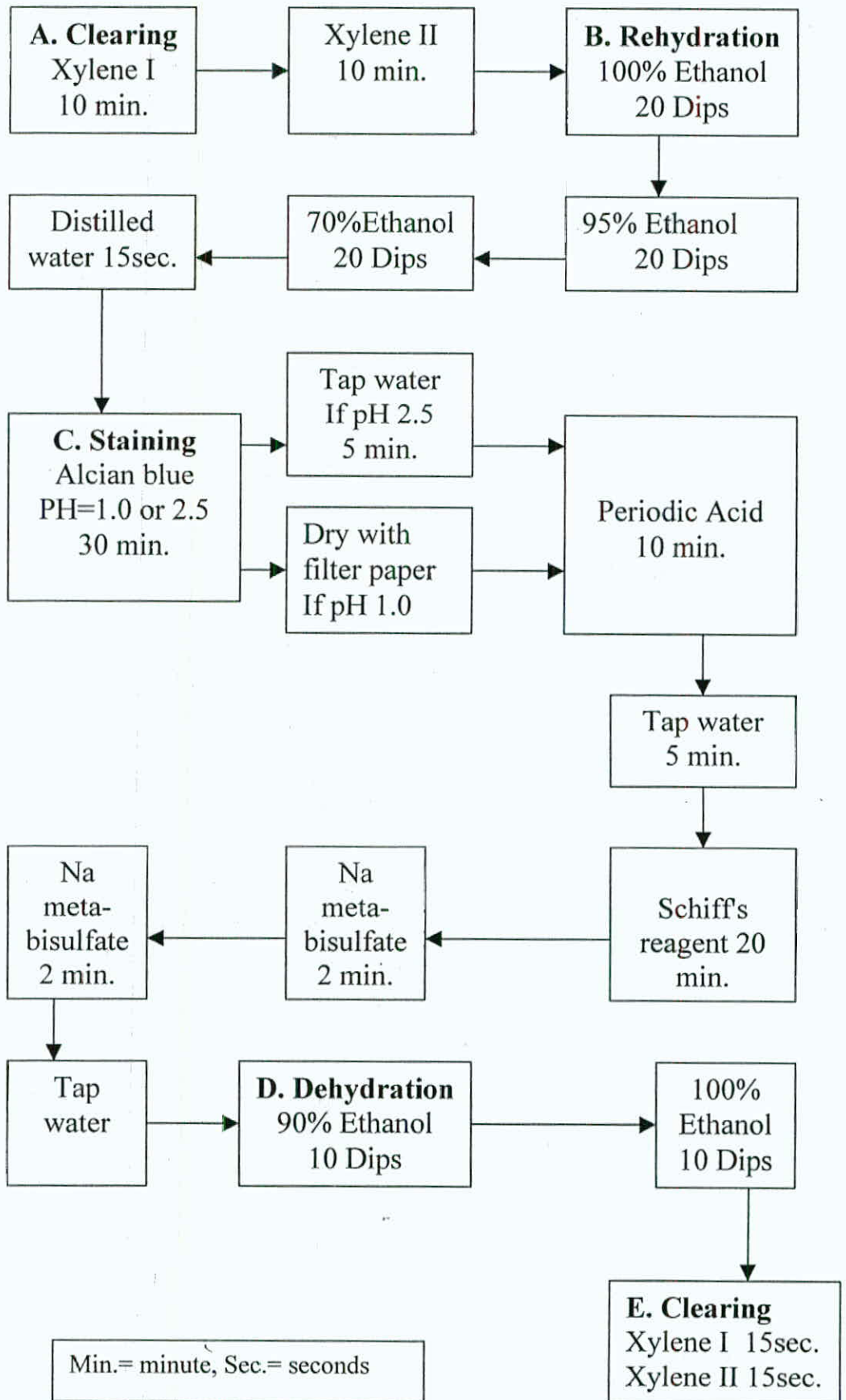
- HAEMATOXYLIN AND EOSIN (H&E)



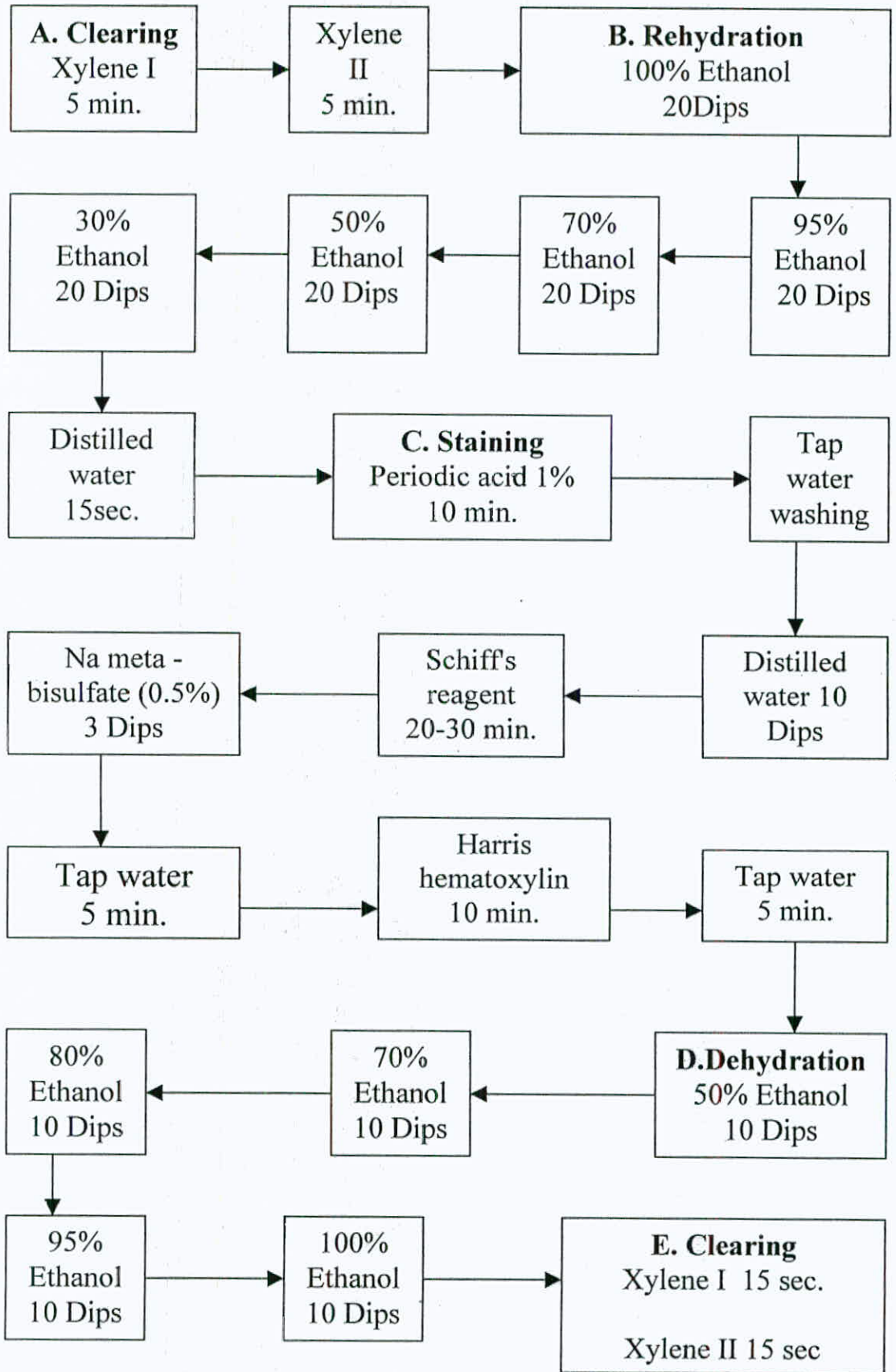
Min. = minute, Sec. = seconds



• ALCIAN BLUE - PERIODIC ACID SCHIFF ( AB/PAS )

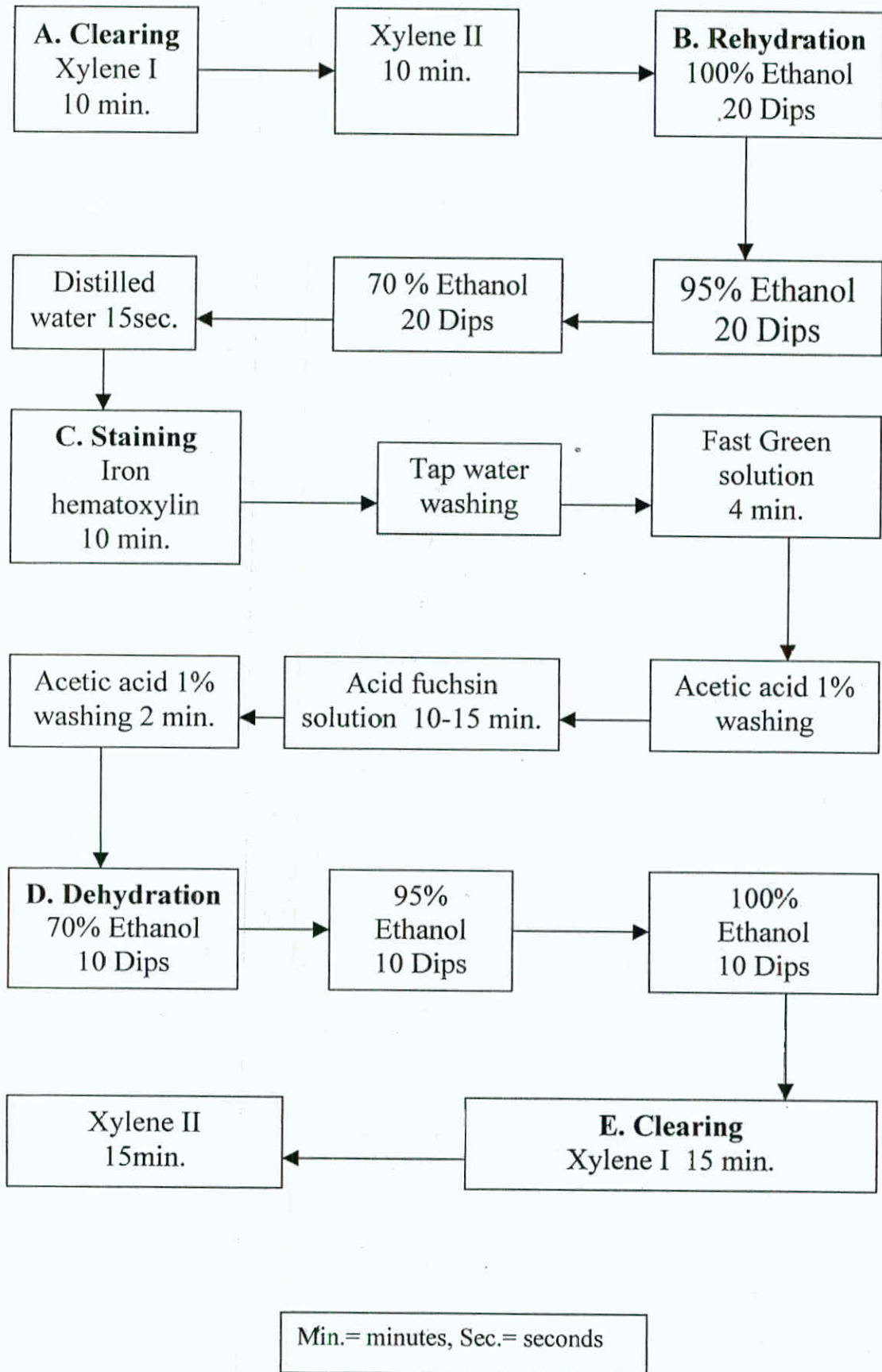


• PERIODIC ACID SCIFF'S METHOD ( PAS )



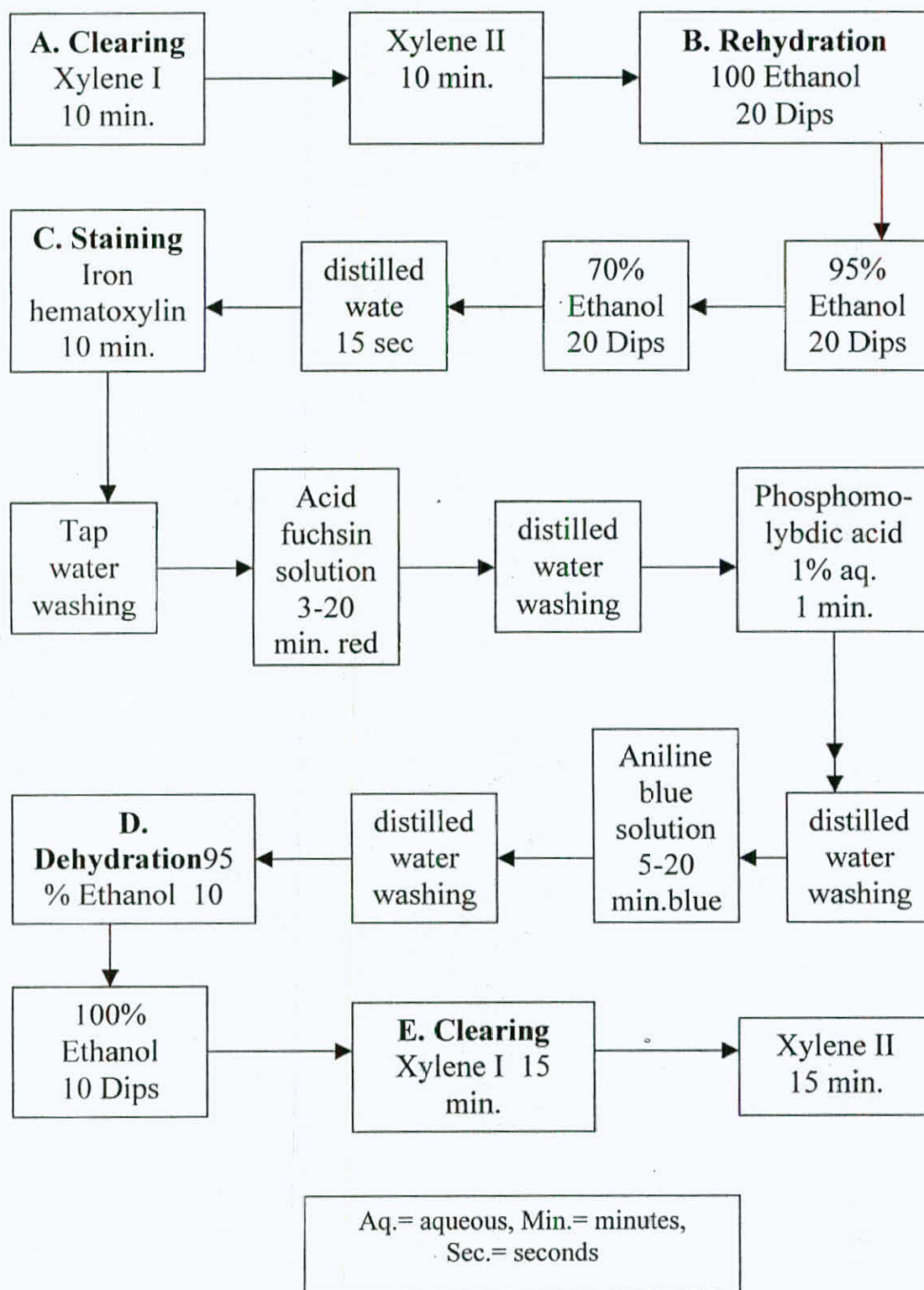
Min.= minute, Sec.= seconds

• FAST GREEN METHOD (FG)

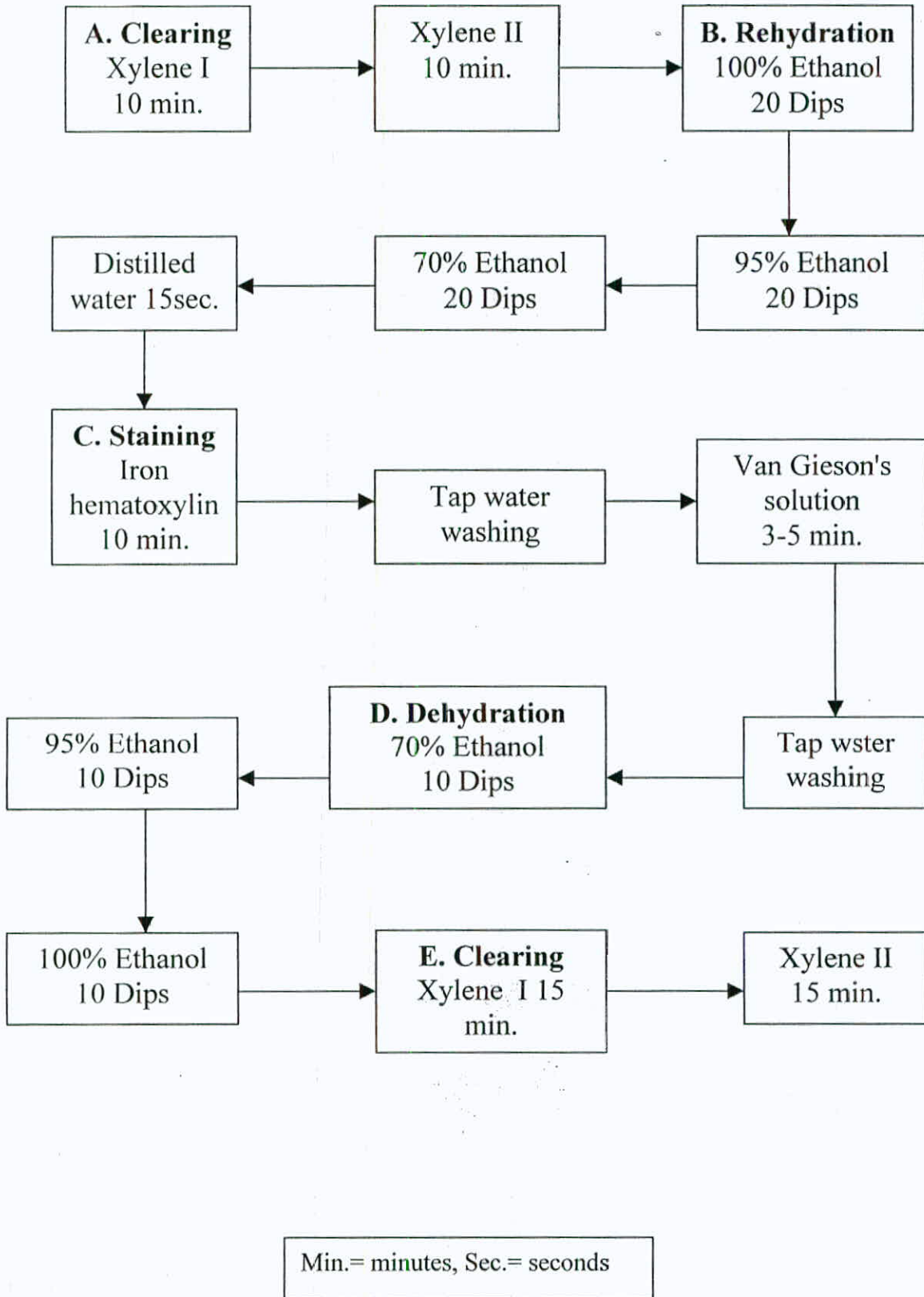




• MALLORY'S TRIPLE STAIN (MT)



• VAN GIESON METHOD (VG)



## G. Mounting

After the staining steps were completed, the slides were covered by cover slips. The mounting medium used was the D.P.X.. The slides then were kept at room temperature to dry. Examination under light microscope was applied and light micrographs were taken by Olympus Vanox-T AH2, using colored films (ASA=100) [in the Genetic Laboratory of the Faculty of Medicine/The University of Jordan].



**4**

**RESULTS**

#### 4.1 The External Morphology

The body of *Malpolon monspessulanus insigtus* is cylindrical and elongated. The dorsal side of which has dark gray, olive color, while the majority of the ventral side is yellowish, but its middle site is pink (Fig. 7). On the ventral side, a dark band extends from the first ventral scale to the 13<sup>th</sup> one. The dark color of the dorsal side starts to lighten from the middle of the body to the tail tip (Fig. 8). No bands are observed on the dorsal body side.

The dorsal scales are elongated and keeled and counts 19 at its middle. The ventral scales are wide and ranges between 156-182 in the adulthood. The anal plate is divided as well as the subcaudal scales which are 75-94. The total body length of the studied specimens reaches 179 cm at its maximum limit (Table 1).

The head of the montpellier snake is an elongated triangle, slightly distinct from the neck (Fig. 9). The eyes are very large with rounded pupils (Fig. 10). The snout is enlarged and rounded. The upper labial scales are 8/8, the 4<sup>th</sup> and 5<sup>th</sup> enter the eye, while the lower labial scales are 11/11, the first four or five enter the anterior chin shield (Fig. 11). It has 2 loreal scales, 1 preocular scale, 1 supraocular scale, 2 postocular scales, 2 anterior and 3 posterior temporal scales (Fig. 10).



Fig. (7): Ventral view of the montpellier snake.





Fig.(8): Dorsal view of the montpellier snake.



Fig (9): Dorsal view of the montpellier snake head.





Fig. (10): Lateral view of the montpellier snake head.



Fig. (11): Ventral side of the montpellier snake head.

TABLE (1): PHOLIDOSIS OF *Malopolon monspessulanus insignitus*

No. of Sp.	Locality	Date of Collection	Sex	VS	MDS	SCS	SVc m	TL cm	TBL Cm	SV/ TBL	TL/ TBL	Head (l,w,h)mm
279 JUM	N.A.	N.A.	J	174	19	93	26	7.5	33.5	0.78	0.22	18.4, 6, 5.5
1186 JUM	Dayr abu Said	1982	♂	172	19	94	80	28	108	0.74	0.26	41, 20, 15
821 JUM	Ar Ramtha	10.12.81	J	134	19	75	40	9.5	49.4	0.8	0.2	22.8, 8.4, 6.9
1361 JUM	Ma'an	.1.1983	♂	156	19	84	58	20	78	0.74	0.26	N.A
937 JUM	Umm Quttain	19.5.82	♂	179	19	N.A	113	N.A.	N.A.	N.A.	N.A.	44.2, 22.4, 16.7
486 JUM	U.J.	1980	♂	174	19	N.A	96	N.A	N.A.	N.A.	N.A.	85.8, 26.2, 13.9
1292 JUM	Dayr abu Said	N.A.	♂	174	19	N.A	78	N.A	N.A.	N.A.	N.A.	36, 19.4, 15
470 JUM	As Salt	5.80	♂	171	19	85	86	28	114	0.75	0.25	28.7, 18.1, 15.5
1875 JUM	Dhulail	5.5.87	♀	176	19	93	101	N.A.	N.A.	N.A.	N.A.	41.1, 20.2, 12.3



675 JUM	Dayr al Kahf	6.81	♂	N.A	19	85	93	28	121	0.77	0.23	N.A.
N.A.	N.A.	N.A.	♂	169	19	N.A	110	N.A	N.A.	N.A.	N.A.	44.8,21.5,17
1413 JUM	Ash Shawmari	6.83	♂	178	19	84	128	32	160	0.8	0.20	46, 30, 25
542 JUM	N.A.	N.A.	♀	N.A	19	N.A	N.A	N.A	N.A.	N.A.	N.A.	43.8, 21.5,17
1139 JUM	N.A.	N.A.	♂	172	19	90	88	27	115	0.77	0.23	40, 18.5,11.2
667 JUM	Yajouz	18.5.81	♂	169	19	77	109	31	140	0.78	0.22	46.1,25.6,17.7
1702 JUM	El Hallabat	4.86	♂	175	19	N.A	135	N.A	N.A.	N.A.	N.A.	52,27.5,16.7
1876 JUM	Air port	4.88	♂	174	19	91	119	40	159	0.75	0.25	49, 25, 15.6
1384 JUM	U.J.	5.83	♂	172	19	89	86	33	119	0.72	0.28	43, 19.4, 13
470 JUM	As Salt	5.80	♂	172	19	N.A	104	30	134	0.78	0.22	47.9, 29.7,11.1
916 JUM	Al'al	12.6.82	♂	171	19	N.A	114	N.A	N.A.	N.A.	N.A.	50.1,22.9,19.8
680 JUM	Kufrinja	18.12.78	♂	171	19	N.A	125	N.A	N.A.	N.A.	N.A.	50.2,22.5,17.3
290 JUM	N.A.	N.A.	♂	178	19	90	134	37	171	0.78	0.22	55.8, 30, 18

N.A.	N.A.	N.A.	♂	178	19	84	111	31	142	0.78	0.22	47.4, 27, 15.4
156 JUM	Al Jubayhah	22.5.78	J	N.A	19	N.A	N.A	N.A	N.A.	N.A.	N.A.	13.9,15.8,12.2
1828 JUM	Qunitra	29.8.87	♂	N.A	19	N.A	85	N.A	N.A.	N.A.	N.A.	32, 12.4, 10.7
1907 JUM	Yajouz	2.7.88	♂	174	19	87	62	21	83	0.75	0.25	30, 14, 9.4
2578 JUM	Yajouz	28.4.90	♂	171	19	93	133	39	172	0.77	0.23	50.5, 27, 19.9
1752 JUM	Ghabagheb	25.5.87	J	169	19	99	52	15	67	0.78	0.22	22.1, 19.7, 9
1893 JUM	Yajouz	2.7.88	J	182	19	84	41	11	52	0.79	0.21	22.5, 10.5, 8
826 JUM	U.J.	23.11.81	♂	169	19	89	81	27	108	0.75	0.25	36, 17, 19
1700 JUM	Ashounah ash Shamaliyah	.4.986	♂	174	19	87	85	26	111	0.77	0.23	37.3, 18.3,12.4
1341 JUM	Hasban	.5.1983	J	179	19	N.A	30	8.6	83.5	0.78	0.22	19.2, 8.9, 6
2560 JUM	Baq'ah	4.98	♂	175	19	92	N.A	36	N.A.	N.A.	N.A.	N.A
876 JUM	Amman	.5.1982	♂	N.A	19	N.A	88	N.A	N.A.	N.A.	N.A.	41, 27, 14.7

2577 JUM	Al-Azraq	1984	♂	173	19	87	121	37	158	0.77	0.23	50.6,31.6,16.9
1414 JUM	Al'al Irbid	.1.1983	♂	174	19	86	138	41	179	0.77	0.23	54.5,32.4,14.7
1931 JUM	Adasieh Na'ur	.6.1990	♀	170	19	92	103	30	133	0.77	0.23	40.1,19, 15.5
1141 YUM	Irbid	N.A.	♂	166	19	80	96.5	30.5	127	0.76	0.24	42.8, 20.4,15.5
266 YUM	Irbid	2.6.82	♂	173	19	94	105	33	138	0.76	0.24	N.A
228 YUM	Tohama	4.5.82	♂	N.A	19	92	N.A	23	N.A.	N.A.	N.A.	N.A
487 YUM	Irbid	13.3.83	♂	176	19	89	70	18	88	0.8	0.20	N.A

h: height; J: juvenile; JUM: Jordan University Museum; l: length; MDS: middorsal scales; N.A.: not available data; SCS: subcaudal scales; SV: snout-vent length; TBL: total body length; TL: tail length; U.J.: University of Jordan; VS: ventral scales; w: width; YUM: Jordan Natural History Museum



## 4.2 The Anatomy Of The Skull

The skull of *Malpolon monspessulanus insignitus* consists of solid bones. It has a triangular shape with length exceeding its width by nearly two folds. It is divided into the following regions : nasal region , orbital region , braincase , upper and lower jaws.

The Nasal Region: the most anterior single bone is the premaxilla. It appears as a small triangle-shaped structure in anterodorsal view. It has four extensions: two at the lateral sides, one extends posteriorly the last one is directing upward and articulating with the ventral side of the nasal bone. The two lateral processes are thickened and terminate before they reach the maxilla bones. The posterior extension is forked and is articulated with the vomer bone (Fig. 12).

The vomer bone is a triangular element located at the ventral side of the skull. Anteroventrally the vomer articulates with the premaxilla and posterodorsally with the nasal bones (Fig. 13).

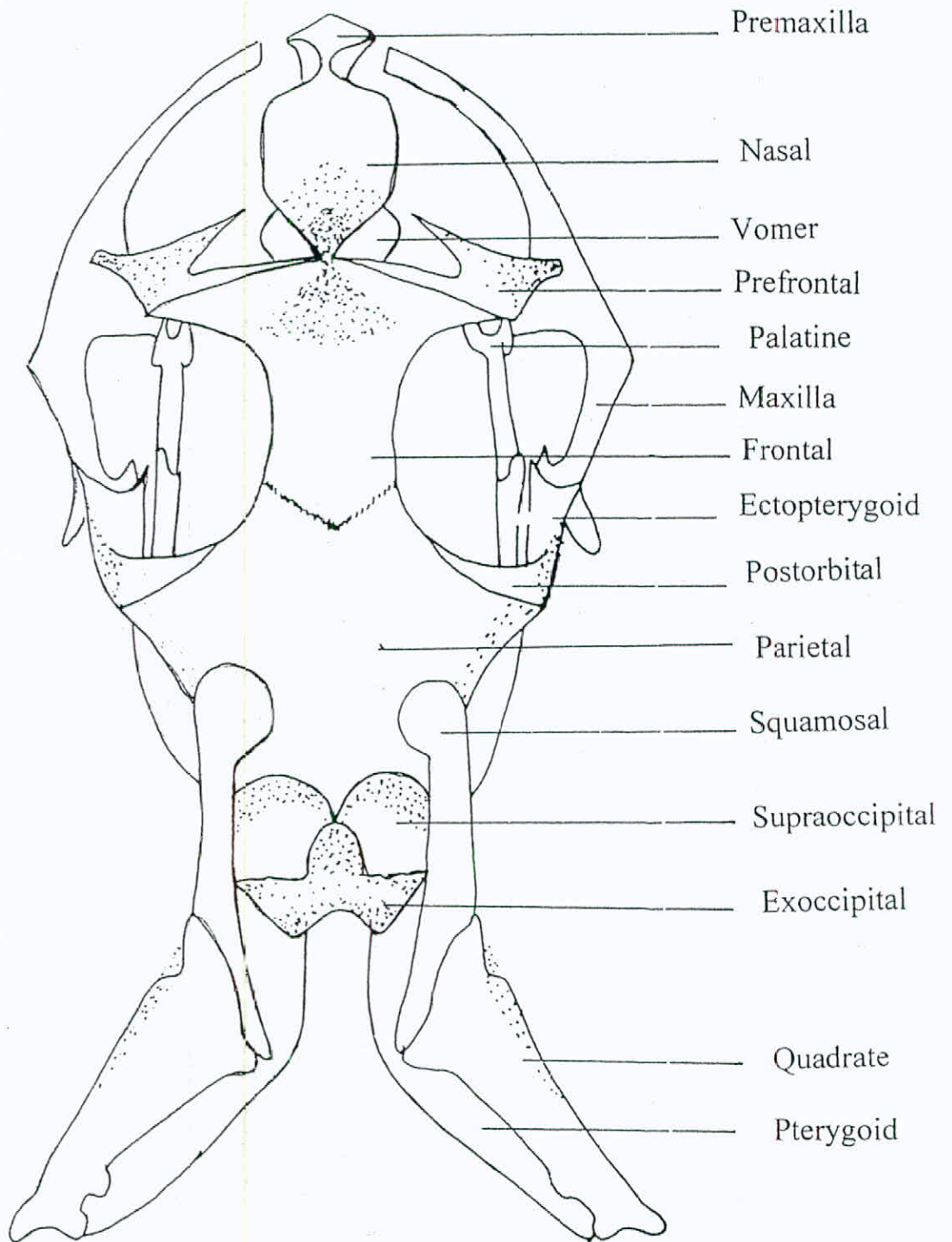


Fig. (12): Dorsal view of the montpellier snake skull (X5).

The nasal bone is a hexagonal-shaped element. Anteroventrally, the nasal articulates with the premaxilla and ventrally with the vomer (Fig. 13).

The Orbital Region: it lies posterior to the nasal region and consists of pair of the following bones: prefrontals, frontals and postorbitals. The prefrotal bone has a short suture with the maxilla by its descending process along the anterior border of the fossa orbitalis. The dorsal process of the prefrontal is sutured with the frontal element posteriorly. Another dorsal process of the prefrontal directs anteromedially and ends before it reaches the nasal bone (Figs. 12&14).

The median roof of the skull is formed by the medially sutured two frontal bones, the single frontal bone has a small waist because the large eyes occupy the majority of orbit region. The frontal bone resembles the dorsal limit of the fossa orbitalis. Ventrally, the frontal bone has a sagittal ridge, that meets the crest ascending from the parasphenoid bone keeping a large triangular space in between them, which divides the orbital region into two halves. Anteromedially, the frontal bone articulates with the nasal one, while anterolaterally it is sutured



nasal one, while anterolaterally it is sutured with the prefrontal.

The frontal is sutured with the parietal posteromedially (Fig. 12).

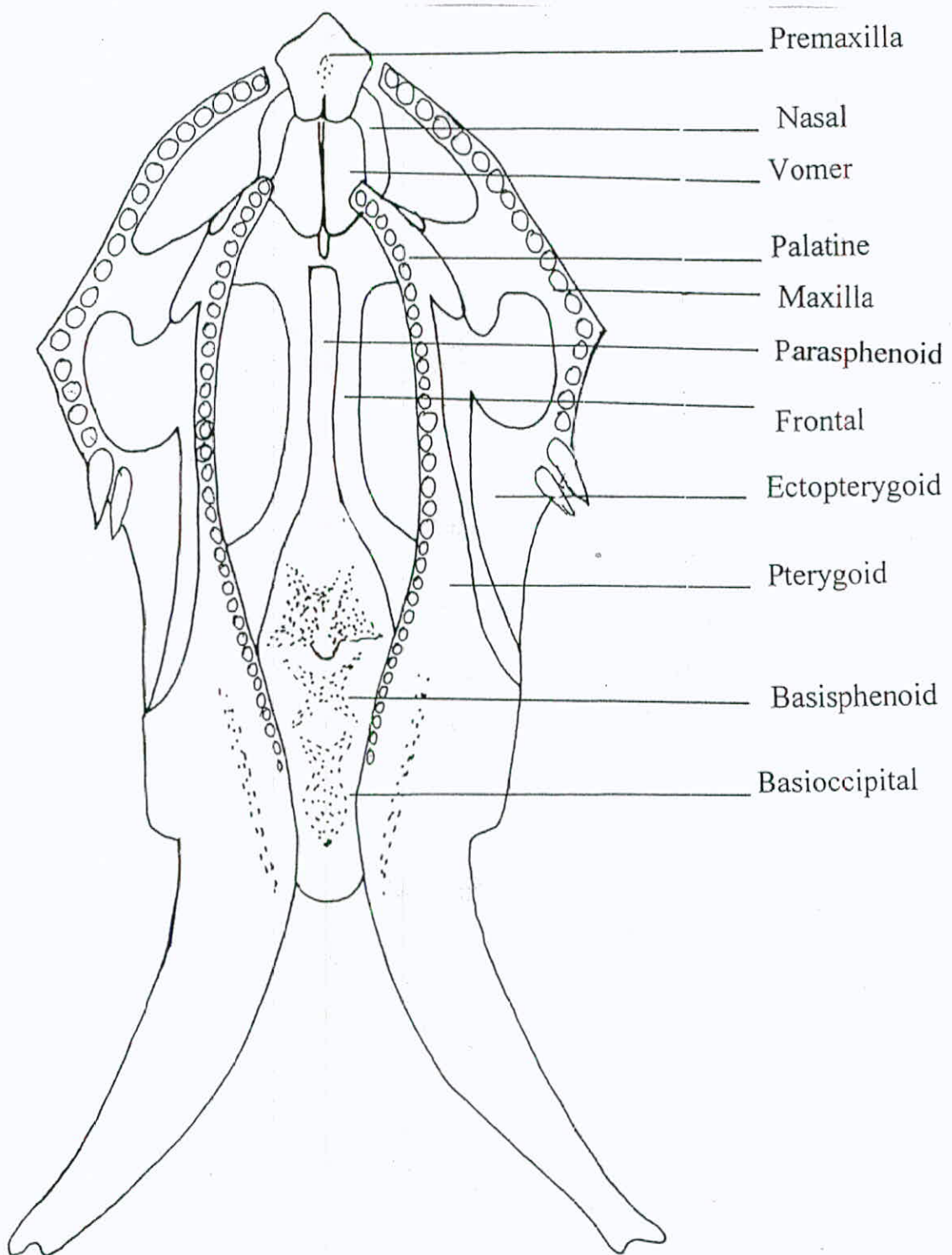


Fig. (13): Ventral view of the montpellier snake skull (X5).




Fig. (14): lateral view of the montpellier snake skull (X5)

Ventrally, and posteromedially the orbit is open, but posterolaterally it is limited by the postorbital bone. The latter bone is a small rod-shaped element, that bends ventrally. It is sutured with the parietal bone dorsally but it is free ventrally which results in opening the ventral side of the orbital region (Fig. 14).

The braincase consists of well sutured group of bones in order to provide the needed protection for the sensitive cranial tissue. The most anterior bone of the braincase is the parietal, which is consisted of plated V-shaped bone; a dorsal horizontal plate and a vertical one. The dorsal plate articulates with the supraoccipital bone posteriorly, the frontal anteriorly, the postorbital anterolaterally and the squamosal dorsolaterally. The vertical plate is a ventrally directed parasagittal bone, sutured with the prootic bone posteriorly (Fig. 12).

The supraoccipital bone is in an extensive suturing with the posteromedial margin of the parietal bone, where the parietal is extending over the supraoccipital bone posteriorly. Anteroventrally, there is a suture on either sides with each prootic. The posteroventral end of the supraoccipital is sutured



with the exoccipital, resulted in elevating the former bone. The suture between prootic-supraoccipital-exoccipital is Y-shaped (Fig. 12).

The exoccipital bone is the most caudal bone, it is bent ventrolaterally. Dorsolaterally, the exoccipital is fused with the supraoccipital and dorsomedially the two halves of the exoccipital are fused (Fig. 12).

The most posterior bone of the floor of braincase is the basioccipital which by its smooth posteroventral end resembles the site of occipital condyle attachment. The anterior end of the basioccipital sutures with the basisphenoid bone and dorsolaterally with the exoccipital bone. The basisphenoid bone has two lateral depressions and a small crest medially. It is posteriorly sutured with basioccipital, with prootic dorsolaterally and with parasphenoid bone anteriorly (Fig. 13).

Anterior to the basisphenoid, the parasphenoid bone lies. It is a triangle bone with a very narrow and tall stalk, holding a crest directing anterodorsally until suturing with the ventral crest of the frontal bone. The parasphenoid has a free lateral side, but has an

articulated posterior end with the basisphenoid bone making a transverse ridge and sutures anteriorly with the frontal bone (Fig. 13).

Laterally, the prootic bone lies between the basisphenoid and the parietal bones. This bone has a suture with the parietal anterodorsally, with the basisphenoid ventrally, with the supraoccipital dorsomedially and with the exoccipital posteriorly. Opisthotic is the posteroventral side of the exoccipital bone.

The upper jaw consists of the following bones: the maxilla, the squamosal and the quadrate. The maxilla bone lies at the outer most lateral side of the skull. It is bent anteriorly, has a number of processes: the one at the bending point is directed medially, curved downward reaching another process from the palatine to make the articulation site between the two bones (Fig. 13). Another process on the dorsolateral side of the maxilla directs upward, looks like a knob. On the most posterior point of the maxilla and before it ends, there are two small opposite processes. Medium-sized teeth (16-18) are found on the ventral side of the maxilla bone beside the two large grooved fangs which are found on the most posterior point of the maxilla (Fig. 13). The

articulation of the maxilla is achieved with three bones: the prefrontal dorsally, the palatine laterally and the ectopterygoid posteriorly (Fig. 14).

The lateral roof of the braincase is covered by the squamosal bone. This bone is a flat element, has one pointed caudal end and blunt rounded anterior end. It lies on the dorsolateral surface of the braincase and adheres strongly to it, starting at the posterolateral side of the parietal and extending caudally. The ventral side of the last third of the squamosal bone is free from attachment with any bony element (Fig. 14). The dorsocaudal surface of the squamosal bone articulates with the quadrate bone in a broad oblique line (Fig. 12).

The quadrate bone is the most posterolateral bone of the skull, it has a straight long axis. The lateral surface of the lower part is twisted by nearly  $45^\circ$  angle. The upper part of this bone is broad, extending anterolaterally to have a wide surface of articulation with the squamosal anteriorly (Fig. 12). The quadrate bone has two small blunt extensions with medial cavity, articulates with the lower jaw behind the braincase. The two



elements of quadrate bone seem to be as standing ones in posterior view.

The roof of the oral cavity is composed of the following group of bones: the ectopterygoid bone, the pterygoid bone and the palatine bone. The ectopterygoid is a flat bone with uneven width, broadened rostrally, but much pointed caudally. The anterior part has two extensions and a cavity for the articulation with the maxilla (Fig. 14). The posterior one is in articulation with the pterygoidbone side by side, to have a wide broad articulation surface (Fig. 13).

The pterygoid bone is the most posterior and largest bone in this group. It is long, broad and divided into two parts: anterior and posterior. The posterior part of the pterygoid is toothless, formed of two perpendicular surfaces: lateral and ventral which is specialized for muscle attachment. The posterior part points posteriorly and ends posteromedially. The anterior part of the pterygoid bone holds 17-19 small teeth on its narrow ventral side (Fig. 13). The pterygoid bone articulates laterally at its mid point with the ectopterygoid bone and anteriorly with the palatine one (Fig. 14).

The palatine is a short rod-shaped bone with two transverse processes, and two caudals. The small transverse process extends laterally to reach the maxillary process making the palatomaxillary articulation point. Free comma-like transverse process extends mediolaterally. The two small caudal extensions with the cavity in between make the articulation with the pterygoid (Fig. 13). It bears 14-15 small-sized teeth.

The lower jaw consists of several bones. The compound bone is the largest among them, it is composed of four fused bones: surangular, prearticular, articular and angular. The lingual surface of the compound bone has a crest posteriorly, with a deep cavity between the lingual surface crest and the labial surface (fossa mandibularis) (Fig. 14). The splenial bone is small, very thin flat triangle element lies between the compound and the dentary bones at the lingual surface, it is devoid of teeth. The most anterior lower jaw bone is the dentary where 21-24 teeth are held, the largest is anteriorly situated, while the smaller are posteriorly located (Fig. 14). The dentary bone is pointed anteriorly and is connected with the dentary bone of the other side by a ligamentous connective tissue keeping a distance between them (Fig. 15). The dentary bone has a triangular shape, the

is with two pointed extensions: upper taller and lower shorter, both articulate with the anterior pointed extension of the hollow

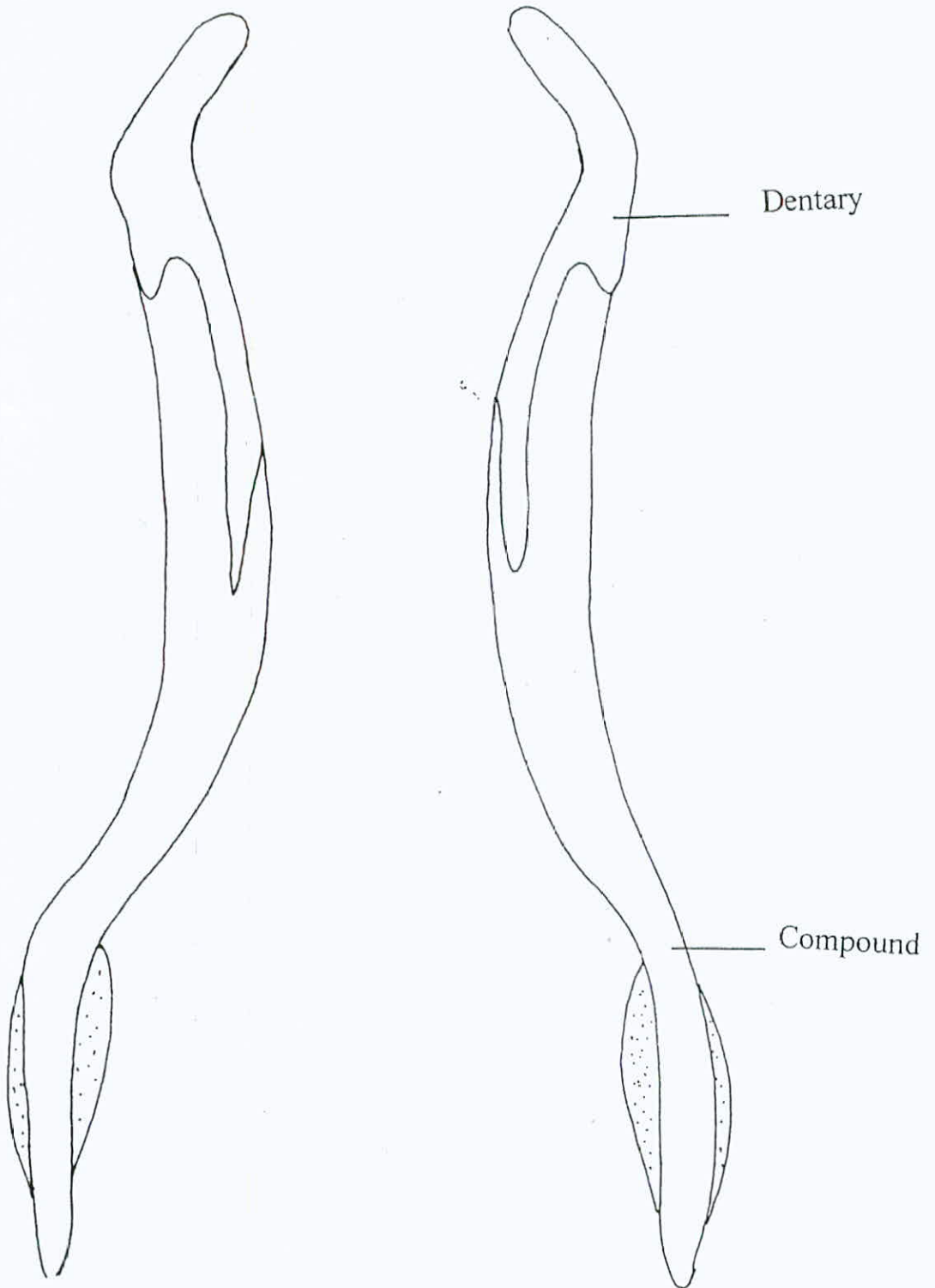


Fig. (15): Ventral view of the lower jaw of the montpellier snake skull (X5).



posterior end is with two pointed extensions: upper taller and lower shorter, both articulate with the anterior pointed extension of the hollow compound bone keeping a cavity in between for the smaller splenial bone at the lingual surface of the lower jaw.

The lower jaw as a whole has an arch shape; two elevated anterior and posterior ends with a depression medially. The posterior end of the lower jaw articulates with the posterior end of the quadrate bone making the quadratomandibular articulation . Behind this articulation there is a process where the muscle quadrati inserts.

### 4.3 The Anatomy Of The Head Muscles

- The superficial layer of head musculature (exposed immediately after skin removal) (Fig. 16).

#### 1. Muscle Adductor Mandibulae Externus Superficialis (MAMES)

It is a large distinct muscle originates from the dorsal side of postorbital bone and from the angle formed between this bone and the parietal. Then the muscle descends obliquely downward and outward, curves around mouth angle, passes beneath the Duvernoy's gland and reappears again on the ventrolateral side of the lower jaw forming U-shaped loop inserting at the lateral side of the compound bone.

#### 2-Muscle Adductor Mandiulae Externus Profundus (MAMEP)

It arises from the anterolateral face of the quadrate bone, lies behind the muscle adductor mandibulae externus medialis, adheres to and linked with it by a connective tissue. It begins dorsally and in front of quadrate bone and inserts on the mandible anteroventrally behind MAMES. The ligament of venom gland passes over the profundus muscle to reach the articulation

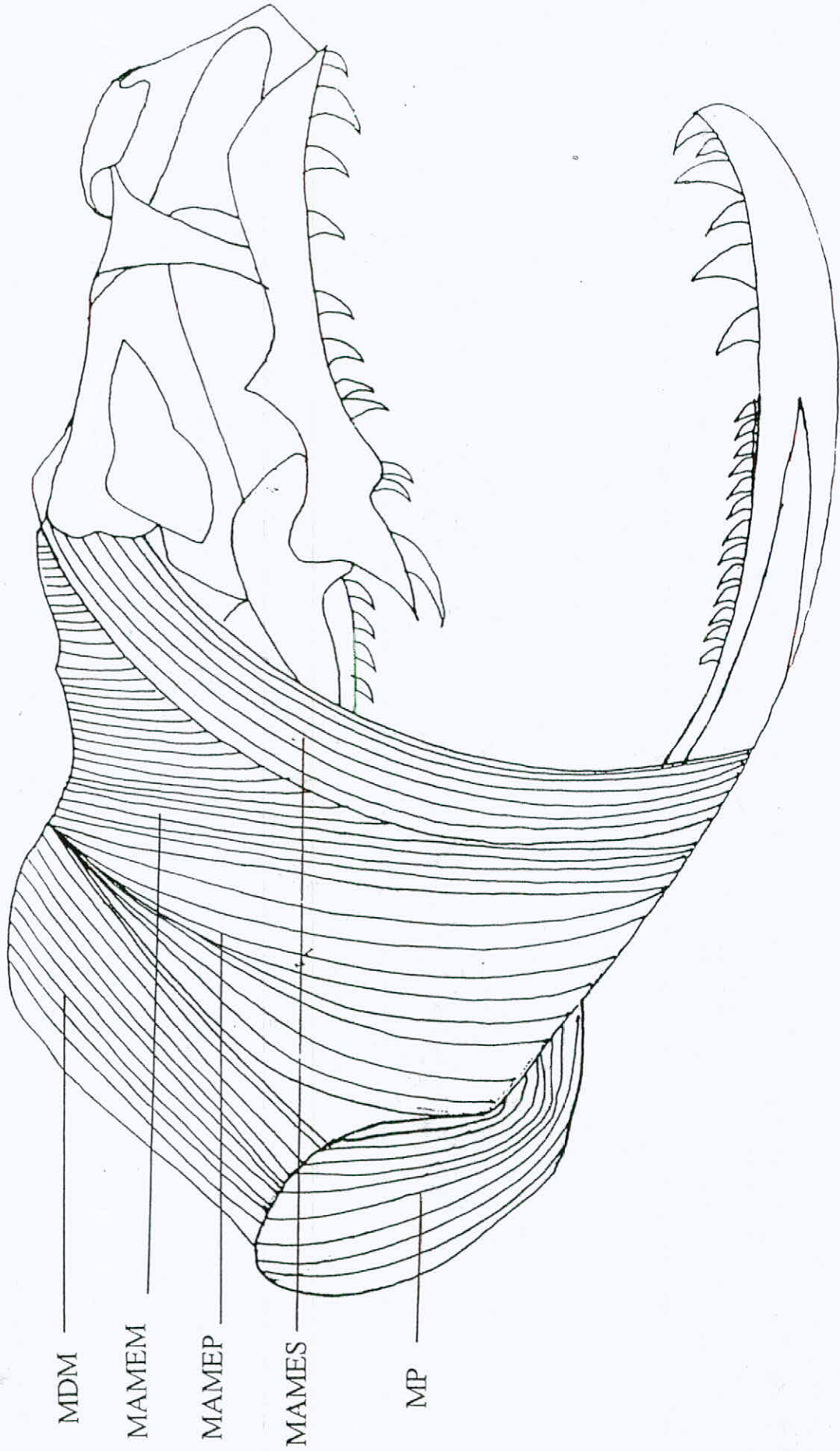


Fig. (16): the outermost layer of the head muscles of the montpellier snake (X5)  
**MAMEM:** muscle adductor mandibulae externus medialis; **MAMEP:** muscle adductor mandibulae externus profundus;  
**MAMES:** muscle adductor mandibulae externus superficialis; **MDM:** muscle depressor mandibulae



quadratomandibular but not through it leaving it as one piece.

### 3-Muscle Adductor Mandibulae Externus Medialis (MAMEM)

This muscle originates from the squamosal bone. It descends straightly and passes over the mouth corner to insert in the lingual side of the mandible.

### 4-Muscle Depressor Mandibulae (MDM)

It is closely attached along the posterior surface of the quadrate bone and inserts on the retroarticular process of the compound bone. This muscle is the only superficial muscle which has a rectangular-shaped fibers structure.

### 5-Muscle Retractor Quadrati (MRQ)

It originates as a broad sheet-shaped structure from the neck region at the level of the 6<sup>th</sup> vertebra. It crosses the MDM obliquely then narrows to reach its insertion at the quadratomandibular joint. Near its attachment on the neck, it overlaps with the muscle sphinctor colli, which covers the lateral and the ventral surfaces of the neck.

- The intermediate layer of head muscles (after the removal of the superficial layer) (Fig, 17).

#### 1-Muscle Pseudotemporalis (MP)

A small, thin and very narrow muscle, originates from the anterolateral surface of the parietal bone. It runs nearly parallel with MAMES but much deeper. It crosses MAMEM and the muscle pterygoideus. Ventrally, this muscle inserts on the lingual surface of the mandible, behind the insertion of MAMEM.

#### 2-Muscle Pterygoideus (MP)

It is a strong muscle, originates on the ventral side of the angle of the mandible, then it runs downward and inward disappearing from the surface, continuing on the upper lip beneath the Duvernoy's gland. Finally, it inserts on the ventral surface of the pterygoid bone.

#### 3-Muscle Adductor Mandibulae Posterior (MAMP)

A straight narrow sheet of muscle fibers. It lies beneath the MAMEP, originates dorsally from the quadrate bone and inserts on the fossa mandibularis.

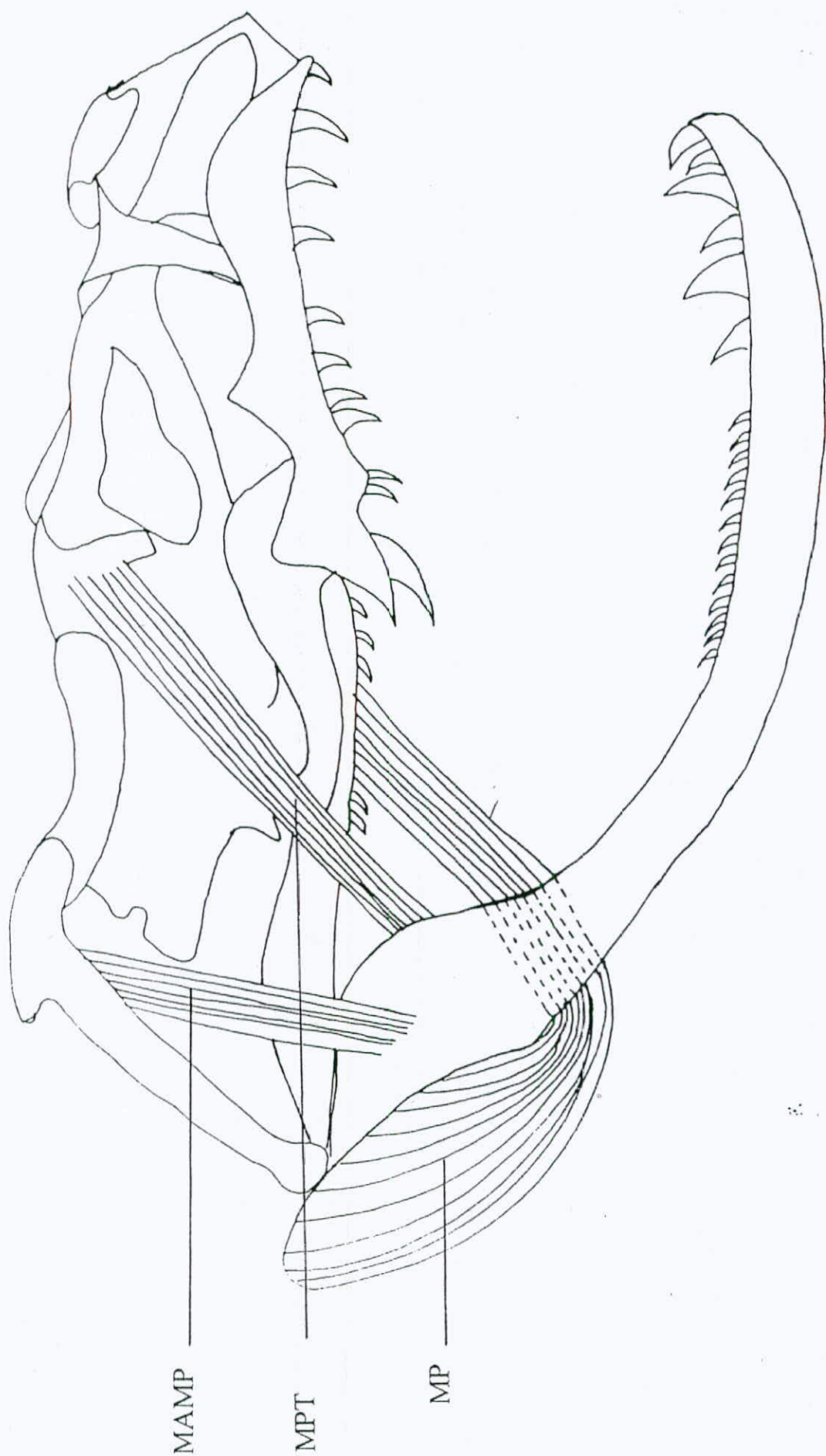


Fig. (17): the intermediate layer of the head muscles of the montpellier snake (X5)  
 MAMP: muscle adductor mandibulae posterior; MP: muscle pterygoideus; MPT: muscle pseudotemporalis



- The deep layer of head muscles (Fig. 18).

#### 1-Muscle Levator Pterygoidie (MLP)

This muscle originates postorbitally. Its posterior fibers insert on the pterygoid bone, while the anterior ones insert on the ectopterygoid bone.

#### 2-Muscle Protractor Pterygoidie (MPP)

The origin of this muscle lies on the anterior end of the basisphenoid bone, posterior to the transverse ridge, while the insertion is located on the dorsal surface of the pterygoid bone. The muscle has an everted narrow V-shaped structure.

#### 3-Muscle Retractor Pterygoidie (MRP)

Originates at the most posterior part of parasphenoid bone, just anterior to the transverse ridge. Its two arms extend anterolaterally to insert in the dorsal surface of palatine bone. The muscle fibers have a V-shaped appearance.

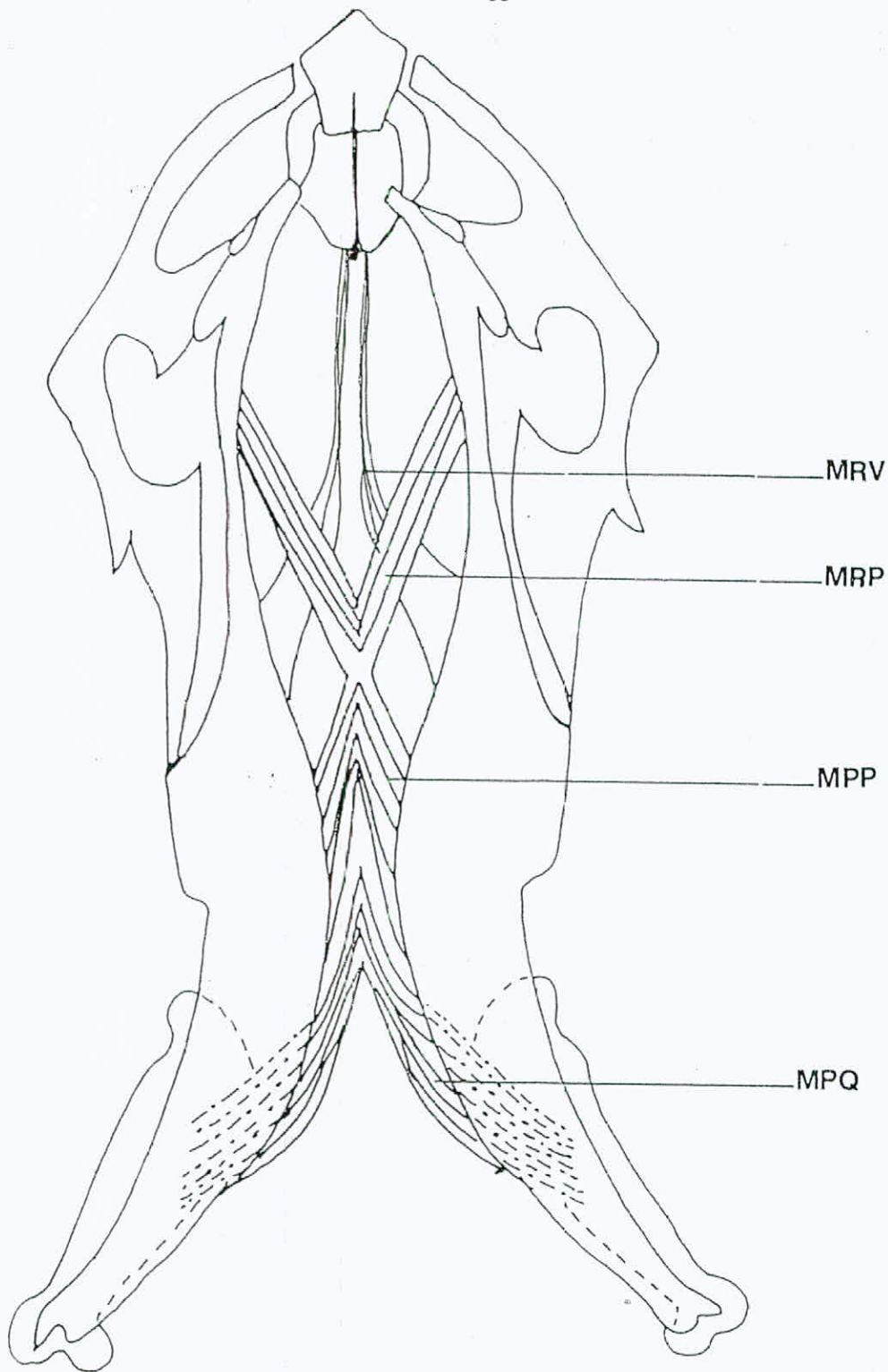
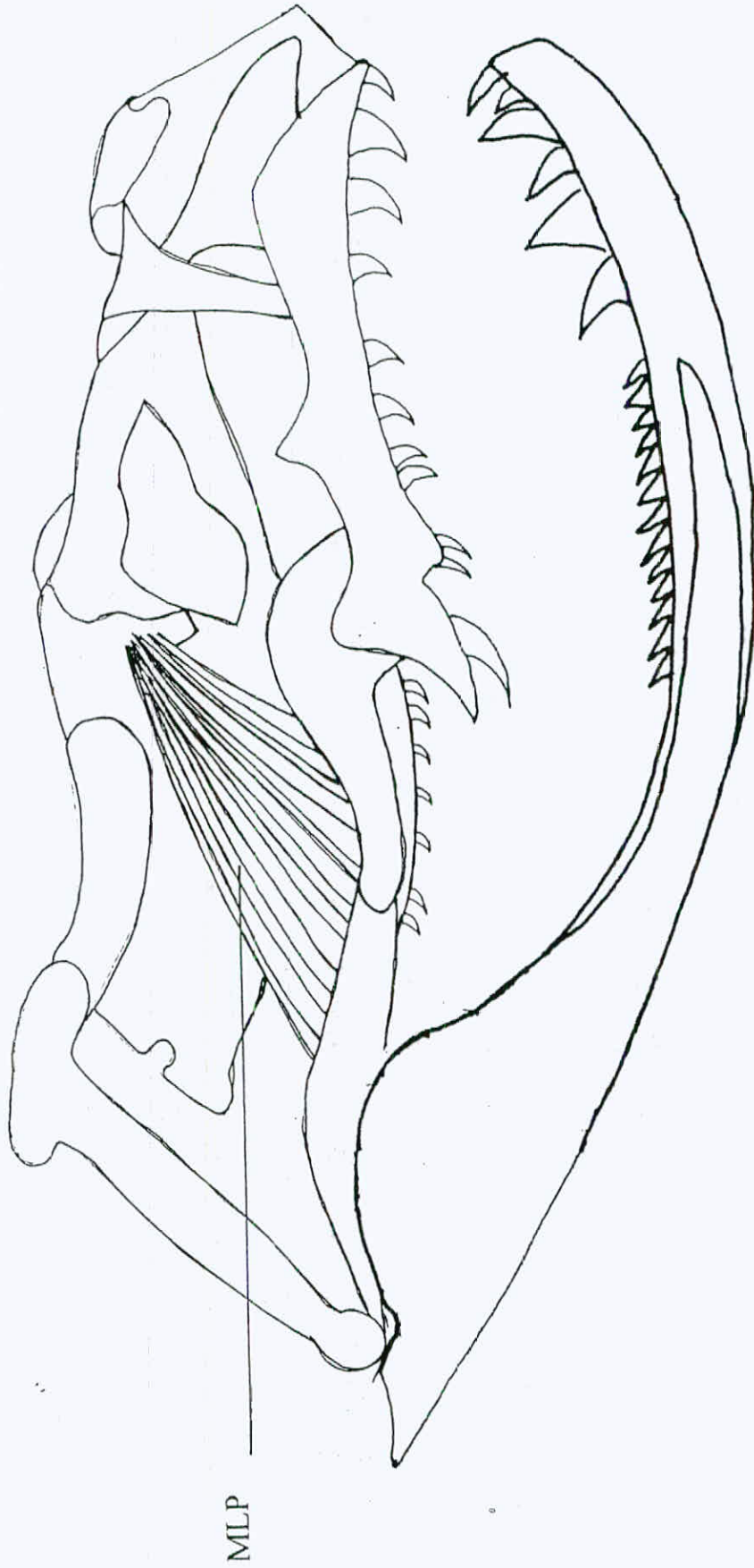

Fig. (18): The deep layer of head muscles of the montpellier snake, ventral view. **MPP: muscle protractor pterygoide; MPQ: muscle protractor quadrati; MRP: muscle retractor pterygoide; MRV: muscle retractor vomeris.**



Cont. Fig. (18): the deep layer of the head muscle of the montpellier snake (X5) . MLP: muscle levator pterygoïdie



#### 4-Muscle Protractor Quadrati (MPQ)

It is a thin sheet of muscle fibers that originate at the ventral surface of the basioccipital bone. The muscle fibers are divided into two halves, each half extends posterolaterally until it reaches the ventral side of the quadrate bone where it inserts.

#### 5-Muscle Retractor Vomiris (MRV)

This is a very thin muscle which originates from the sphenoid bone, passes anteromedially with narrowing. It reaches its insertion point on the posterodorsal edge of the vomer as a thread like element.

- The intermandibular muscles(the muscles of the lower jaw)  
(Fig. 19)

#### 1-Muscle Intermandibularis Anterior (MIMA)

This muscle originates at the most anterolateral surface of the dentary bone. The two halves of this muscle extend from each side posteromedially for a short distance to form V-shaped structure. They reach the midventral raphe, where the insertion of this muscle lies.

## 2-Muscle Intermandibularis Posterior (MIMP)

A larger muscle than MIMA, originates posteriorly from the middle of the lateral surface of the compound bone. It extends anteromedially to insert at the midventral raphe.

## 3-Muscle Neuro-Costo-Mandibularis (MNCM)

This muscle is composed of two parts: the dorsal part originates from the vertebral column, while the other one from the ribs. The two parts unite ventrally, then this muscle is forked in a way that each division reaches the ventral surface of the compound bone.

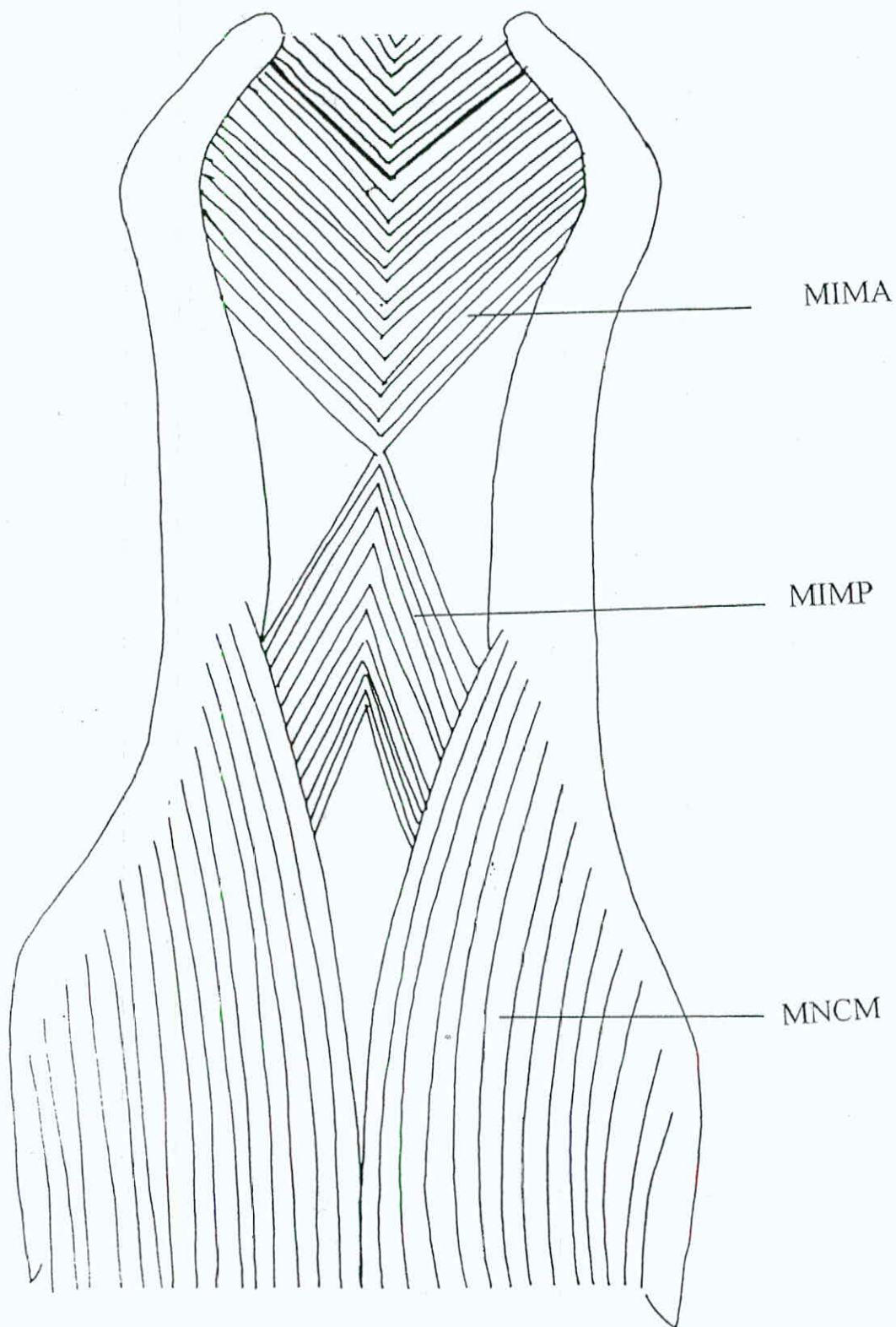


Fig. (19): Intermandibular layer of head muscles, ventral view.

**MIMA:** muscle intermandibularis anterior, **MIMP:** muscle Intermandibularis posterior, **MNCM:** muscle neuro-costo-mandibularis.



#### 4.4 The Anatomy Of The Vertebrae

The vertebrae of *Malpolon monspessulanus insignitus* have different shapes and sizes among different regions (neck, trunk and cloaca) of the vertebral column. The first three vertebrae have different shapes. The first is the atlas which consists of three fused parts (Fig. 20). The two halves of the neural arch and the intercentrum (i1). No prezygapophysis or postzygapophysis is found in atlas. Atlas looks like a ring, it has only a small neural spine located dorsally. Two tiny processes are found at the base of the two halves of the neural arch internally, they are connected by a ligament called the transverse ligament. The articulation between the atlas and the skull is carried out by one occipital condyle which is situated at the ventral side of the basioccipital bone.

The axis, the second vertebra, is larger than the atlas and has a dorsal neural arch and ventral centrum (Fig. 21). Anteriorly, at the inferior side of the axis a large process lies which is called the odontoid process. The odontoid process slides under the transverse ligament of the atlas. The latter divides the neural canal of the atlas into a large dorsal one for the spinal cord, and a smaller ventral one for the odontoid process.

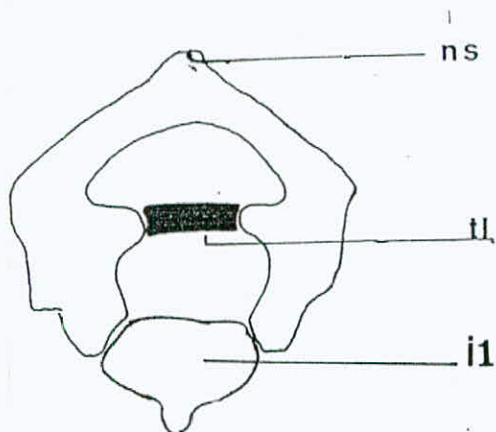


Fig. (20): The first vertebra of the montpellier snake, Atlas, anterior view.




Fig. (21): The second vertebra of the montpellier snake, Axis, lateral view.

**c: centrum, hp: hypapophysis, ic: intercentrum (1,2&3),**

**ns: neural spine, op: odontoid process, tl: transverse ligament**

The dorsal surface of axis holds a spine that extends posteriorly which is called the neural spine. The axis bears two intercentra ventrally (i2 and i3).

The third vertebra has nearly the same general appearance of the trunk vertebrae (Fig. 22). Keeping in mind that the third vertebra is smaller in size than the trunk ones and it has got upper neural spine and lower spine called the hypapophysis. The neural spine of this vertebra extends posteriorly as much as the hypapophysis does at the ventral side. The third vertebra bears the two types of zygapophysial facets: the prezygapophysis which is in articulation with the postzygapophysis of the axis. The other type is the postzygapophysis which articulates with the prezygapophysis of the fourth vertebra. Further articulation is achieved by the zygaposphene and the zygantrum. The former is located at the anterior end of the neural arch, while the latter is at the posterior end. The articulation of the vertebrae with the ribs is carried out by means of two facets positioned ventral to the prezygapophysis. The two facets are the diapophysis which is located dorsally. The parapophysis is the ventral facet (Fig. 22).



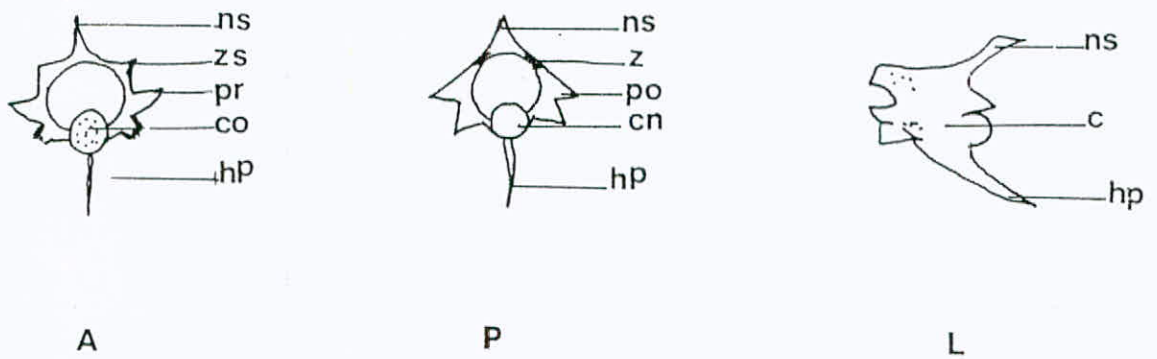


Fig. (22): The third vertebra of the montpellier snake,

A: anterior view; L: lateral view; P: posterior view.

**c: centrum, co: cotyle, cn: condyle, hp: hypapophysis, ns: neural spine, pr: prezygapophysis, po: postzygapophysis, z: zygantrum, zs: zygapophene**

The trunk vertebra has the largest size among the vertebral column (Fig. 23). It has a neural spine with a crest appearance along the dorsal surface of the vertebra without extending posteriorly. The hypapophysis is highly reduced. It has the two types of the zygapophysial facets in addition to the other surfaces of articulation facets.

The cloacal vertebra is characterized by having a pair of haemapophyses located ventrally instead of the hypapophysis found in the former vertebrae. It has got the two types of zygapophyses and also the ventral centrum (Fig. 24).

The centrum of the montpellier snake vertebra is slender procoelous and fused with the neural arch which consists of a roof of two walls (the two descending parts). The centrum bears large anterior cotyle and posterior condyle with a precondyle constriction. The joint between the two successive centra is a synovial joint, ball and socket type.

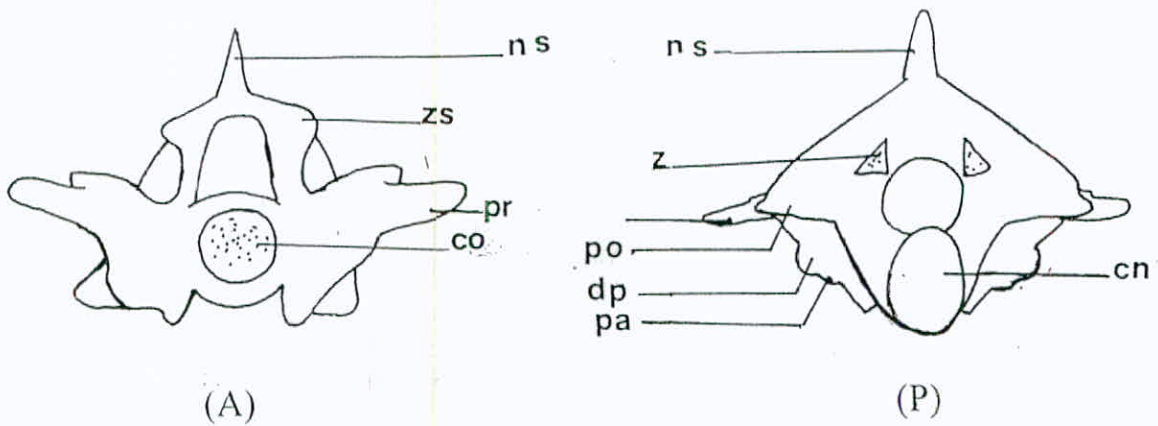


Fig. (23): The trunk vertebrae.

A: anterior view; P: posterior view

co: cotyle, cn: condyle, dp: diapophysis, ns: neural spine, pa: parapophysis, pr: prezygapophysis, po: postzygapophysis, z: zygantrum, zs: zygapophene

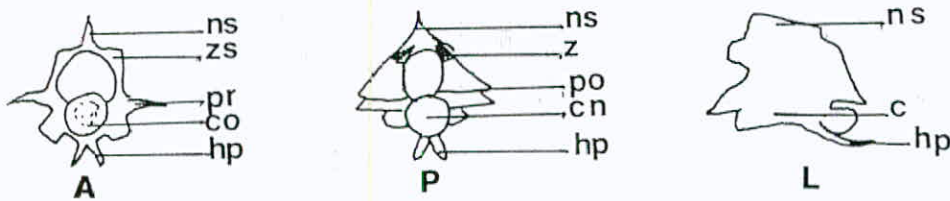


Fig. (24): The cloacal vertebrae.

A: anterior view, L: lateral view; P: posterior view

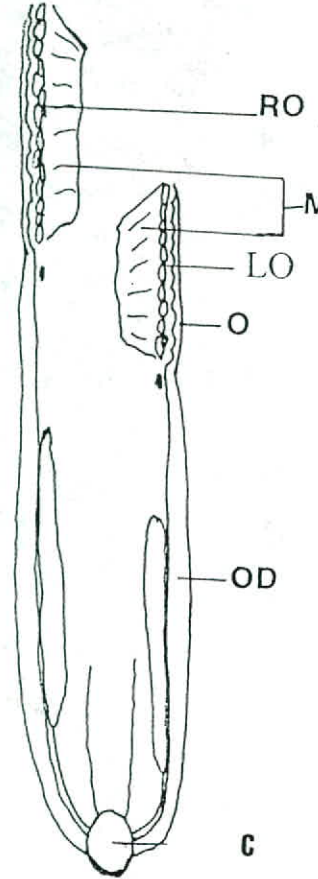
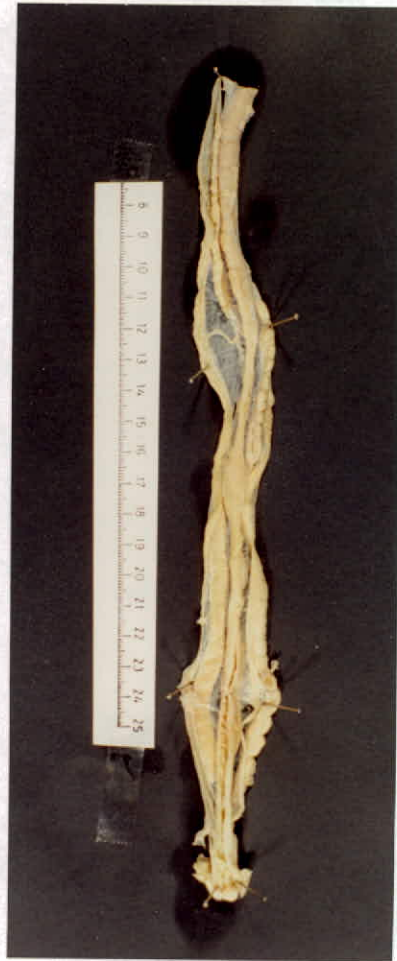c: centrum, co: cotyle, cn: condyle, hp: haemapophyses, ns: neural spine, pr: prezygapophysis, po: postzygapophysis, z: zygantrum, zs: zygapophene



## **4.5 The Anatomy Of The Reproductive System**

### **4.5.1 The Female Reproductive System**

The female reproductive system is composed of two creamy multi-folliculated ovaries (Fig. 25). The right ovary is situated anterior to the left one. The two ovaries are connected to the dorsal body wall by the mesovarium. Posterior to each ovary long straight tube extends caudally which is the oviduct. The anterior opening of the oviduct is obliquely facing the ovary, called the ostium of the infundibulum. This part of the oviduct carries out the duty of receiving the egg after ovulation process is over. Next, the rest of the Fallopian tube lies, which passes the eggs to the uterus posteriorly. The last enlarged part connected to the oviduct is the uterus. The oviduct opens in the cloaca into the middle chamber, the vaginal opening which in turn opens into the proctodeum.



**Fig. (25):** The female reproductive system.

**AD:** adrenal gland; **C:** cloaca; **LO:** left ovary; **MV:**mesovarium;

**O:** ostium; **OD:** oviduct; **RO:** right ovary.

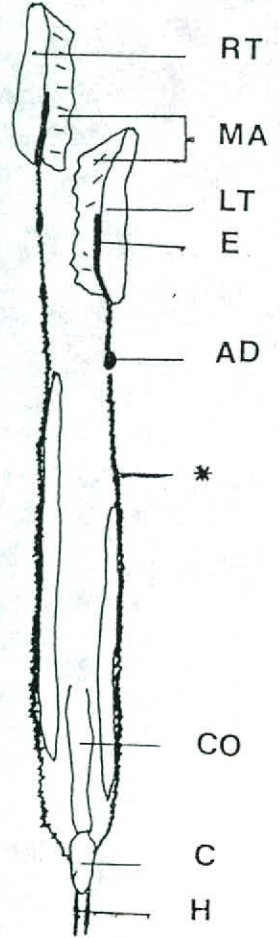
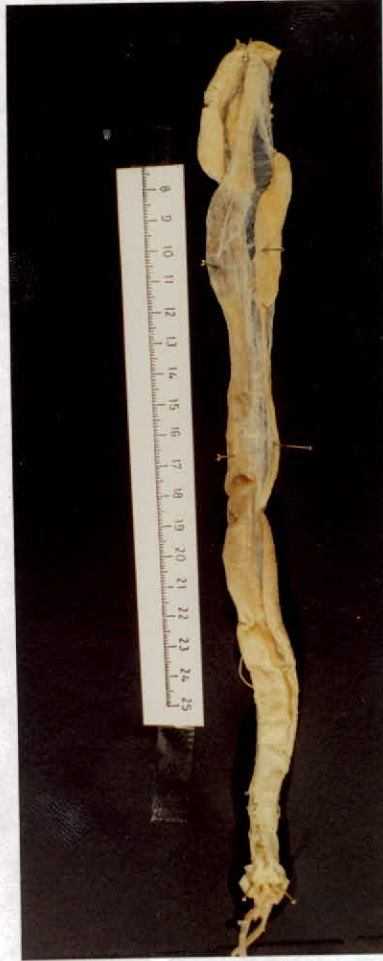

Fig. (26): The male reproductive system.

**AD:** adrenal gland; **C:** cloaca; **CO:** colon; **E:** epididymis;

**H:** hemipenes; **LT:** left testis; **MA:** mesorchium; **RT:** right testis;

**\*:** vas deferens.



#### 4.5.2 The Male Reproductive System

The male genital tract consists of two yellowish bodies, the testes. The right testis is larger (Table 2) than and lies anteriorly to the left testis. The two testes are anchored to the dorsal body wall by the mesorchium (Fig 26). At the dorsomedial side of each testis a well convoluted tubule is noticed which is called the epididymis, which is used for the sperm storage and nourishment, is noticed. From the posterior tip of the each testis the vas deferens extends caudally, it is also highly convoluted. It runs along the lateral side of the kidney to carry the sperm down to the cloaca. Before reaching the cloaca, the ureter unites with the ductus deferense to inter the cloaca in a common opening; the urodeum (Fig. 28). At the base of the cloaca, two openings are found, through which the two hemipenes are everted. The hemipenes lie in the anterior region of the tail where they are found to be in inversion status, one of them only is everted during copulation.

The hemipenis of *M.m.insignitus* is elongated narrow pointed element (Fig. 27). The surface of the hemipenis is smooth, devoids from macro- or micro-ornamintations with single

sulcus. It is sharply pointed at its anterior tip. The two hemipenes are located at the two marginal sides of the cloacal opening.

SPECIMEN #	LENGTH OF TESTIS mm		DISTANCE BETWEEN SNOUT AND ANTERIOR TIP OF TESTIS, cm	
	RIGHT	LEFT	RIGHT	LEFT
1700 JUM	30.7	22.6	67	72
675 JUM	29	25.4	66	71.5
1876 JUM	45	51	88	95
826 JUM	N.A.	23.2	N.A.	52.5
290 JUM	35.2	N.A.	90	N.A.
916 JUM	43.2	52.5	70.5	75
N.A.	24.5	32.4	87	90
1702 JUM	38.1	35.4	103	107
1292 JUM	32	34.4	52	56
N.A.	44.2	40.3	84	89
N.A.	40.1	38.8	105	110
1141 YUM	N.A.	N.A.	75	79

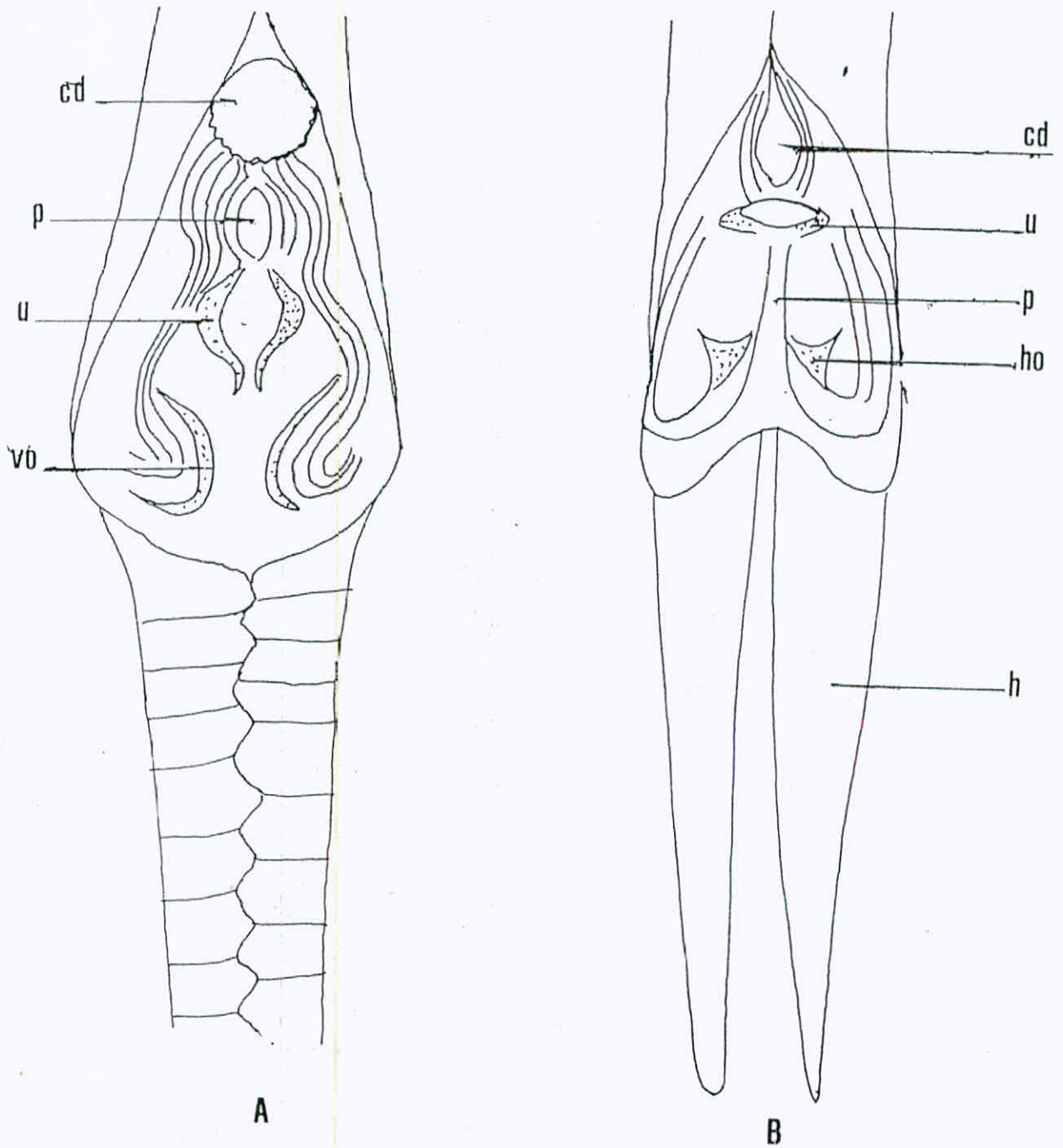
Table (2): length of the testes and distance from the snout  
N.A.: not available data.

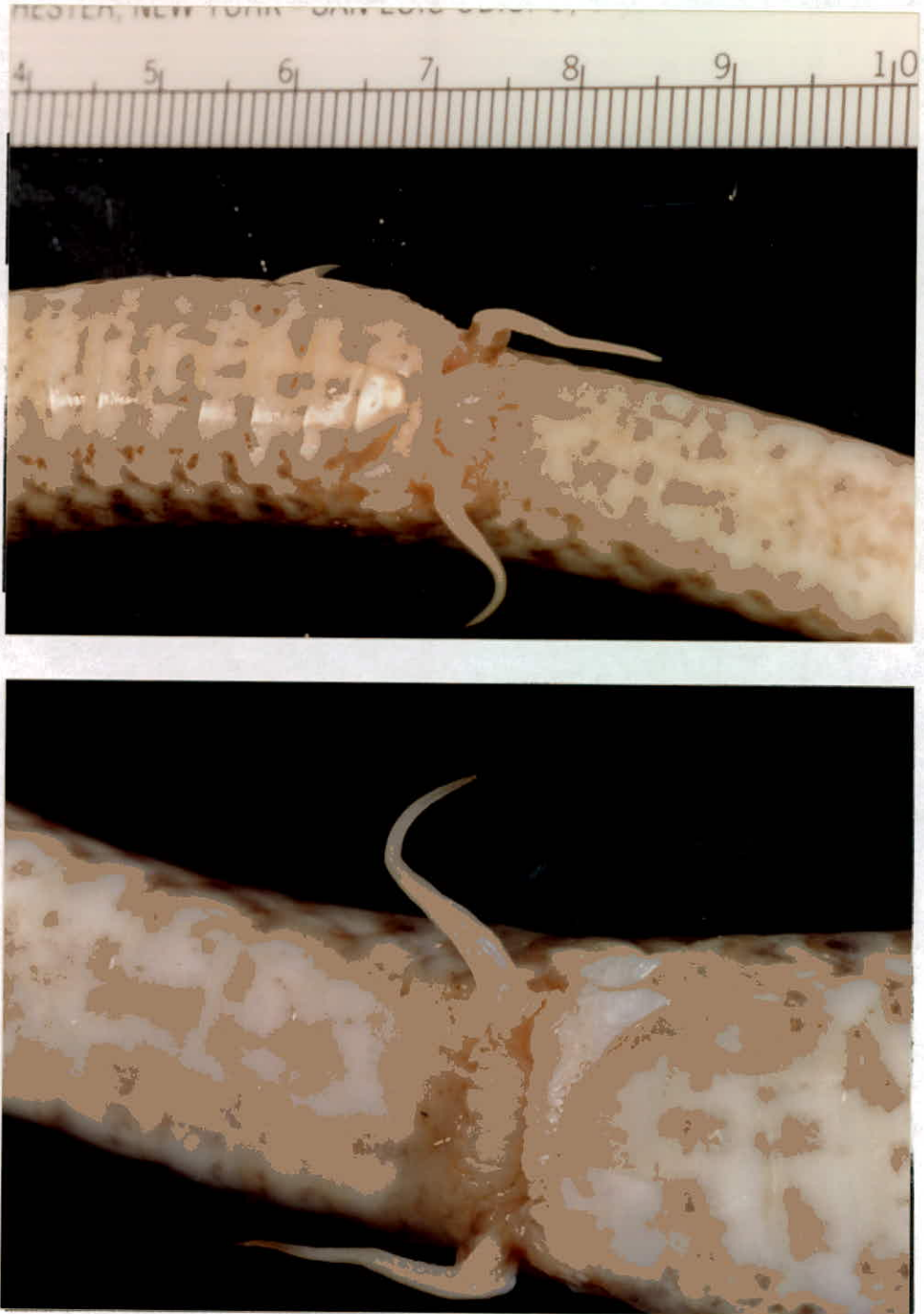

Fig. (27): The hemipenes of the montpellier snake

**Ap:** anal plate; **h:** hemipenis; **scs:** subcaudal scales





(A): female

(B): male

Fig. (28): The anatomy of the cloaca (X4)

cd: coprodaeum; h: inverted hemipenes; ho: hemipenial opening; p: papillae;  
u: urodaeum; vo: vaginal opening.

## 4.6 The Digestive Tract

### 4.6.1 The Anatomy Of The Digestive Tract

#### 4.6.1.1 The Esophagus

The esophagus starts as a very wide tube at the most anterior region of the body cavity. It is the longest part among the alimentary canal, it reaches 50% of the snout-vent length (Table 3). The esophagus keeps its course as a straight structure without any convolution pattern.

The esophagus has a thin wall along the most anterior region, in which the folds are quite tall, widely spaced, unbranched and rough surfaced. The spaces between the folds are filled with smaller longitudinal ridges. As directing posteriorly, the wall becomes thicker and the folds which still quite tall and unbranched become closer and more rough surfaced, but no spaces are found between the folds. The thickest esophageal wall is found near the stomach, and the folds here have more thickness and width. There is no sphincter existing between the esophagus and the stomach (Fig. 29).

TABLE (3): Proportions Of The Digestive Tract  
Organs In *M.m.insignitus*

Specimen #	Sex	SV cm	Eso. cm	Stm. cm	Int. cm	Eso. /SV	Stm. /SV	Int./ SV	% Eso. /SV	% Stm. /SV	% Int. /SV
279 JUM	J	26	10	6	7.5	0.38	0.23	0.29	38	23	29
1186 JUM	♂	80	32	18	26.5	0.40	0.23	0.33	40	23	33
821 JUM	J	40	17.5	7	13.5	0.44	0.18	0.34	44	18	34
1875 JUM	♂	101	48	18	32	0.48	0.18	0.32	48	18	32
675 JUM	♂	93	35	26	32	0.38	0.28	0.34	38	28	34
N.A.	♂	110	44	19	N.A	0.40	0.17	N.A	40	17	N.A.
667 JUM	♂	109	53	25	41	0.49	0.23	0.38	49	23	38
1702 JUM	♂	135	53	33	43	0.39	0.24	0.32	39	24	32
1876 JUM	♂	119	58	25	35	0.49	0.21	0.26	49	21	26
916 JUM	♂	114	46	26	38	0.40	0.23	0.33	40	23	33
680 JUM	♂	125	53	N.A	34	0.42	N.A	0.27	42	N.A.	27
290 JUM	♂	134	50	28	44	0.37	0.21	0.33	37	21	33
N.A.	♂	111	48	19	36	0.43	0.17	0.32	43	17	32
1907 JUM	♂	62	30	14.5	18	0.48	0.23	0.29	48	23	29
2578 JUM	♂	133	66.5	28	45	0.50	0.21	0.34	50	21	34
1752 JUM	J	52	23	8	18	0.44	0.15	0.35	44	15	35
1893 JUM	J	41	18	8	14	0.44	0.20	0.34	44	20	34
1700 JUM	♂	85	40	16	26	0.47	0.19	0.31	47	19	31



2577 JUM	♂	121	50	25	42	0.41	0.21	0.35	41	21	35	
1341 JUM	J	30	13	7	8	0.43	0.23	0.27	43	23	27	
876 JUM	♂	88	39	12.5	30	0.44	0.14	0.34	44	14	34	
1141 YUM	♂	96.5	44	17	31	0.46	0.18	0.32	46	18	32	
1414 JUM	♂	138	60	29	46	0.43	0.21	0.33	43	21	33	
1931 JUM	♀	103	43	27	28	0.42	0.26	0.27	42	26	27	
Mean of percentage values in juvenile individuals										42.6	15.8	31.8
Mean of percentage values in adult individuals										43.4	22.2	32.1

Eso.: esophagus; Int.: intestine; J: juvenile; JUM: Jordan University Museum; N.A.: not available data; Stm: stomach; SV: snout-vent length; YUM: Jordan Natural History Museum

#### 4.6.1.2 The Stomach

It is the middle part of the digestive tract, that begins nearly at the level of the 80<sup>th</sup> ventral scale. It is shorter than the esophagus and appears as a sac like structure, doesn't exceed 28% of the Snout-Vent length. The stomach attains a very thick and strong wall.

The gastric folds run along the whole length of the stomach. The folds are broader, thicker, deeper, more distinct and more widely spaced than those of the esophagus. The wall between the folds has rough spongy appearance. Posteriorly, the spaces between the folds are reduced. At the region between the stomach and the small intestine a finger like projection exists, after which the gastrointestinal junction lies. The curvature of the pyloric region is only made by the bending of the muscular layer of the stomach but not the internal mucosa (Fig. 30).

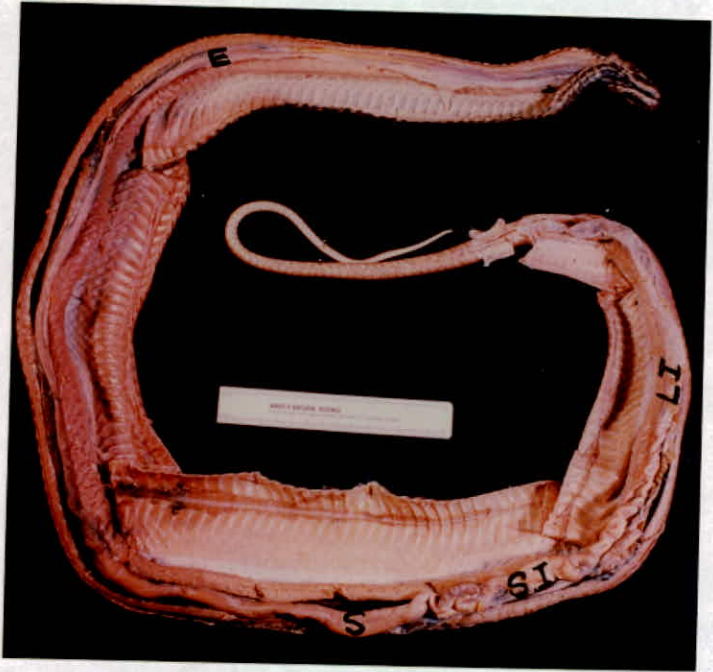


Fig. (29): The digestive tract of the montpellier snake. **E:** esophagus; **S:** stomach; **SI:** small intestine; **LI:** large intestine

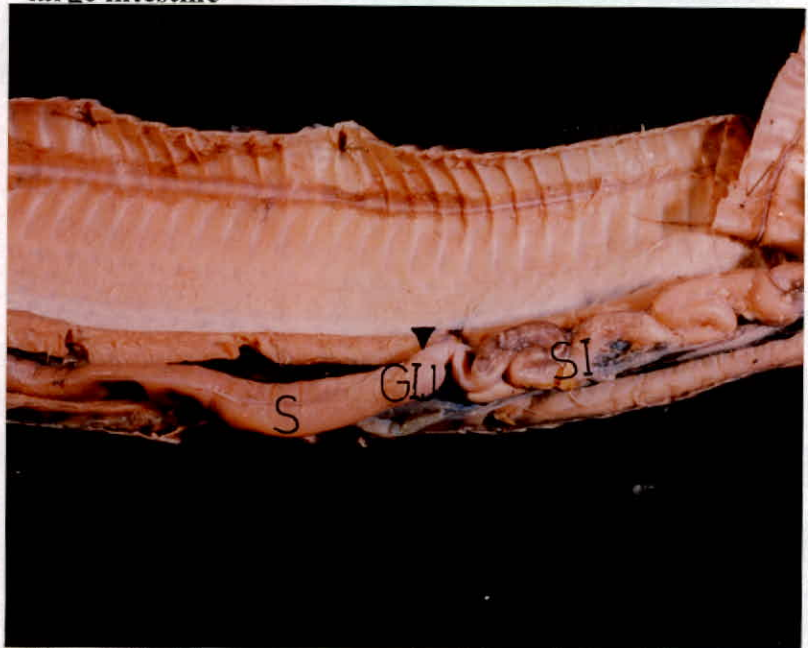

Fig. (30): The gastrointestinal junction of the montpellier snake. **GI:** gastrointestinal junction; **S:**stomach; **SI:** small intestine



#### 4.6.1.3 The Intestine

The small intestine is a highly convoluted narrow tube, surrounded by large number of fat bodies (small creamy organs having a size ranges from 1-30 mm , and present around the small intestine). The large intestine is a straight wide thin tube, (Fig.29). Both the small and the large intestine are longer than the stomach but still shorter than the esophagus, both may reach 26-38% of Snout-Vent length.

The internal relief of the small intestine is characterized by having longitudinal, wavy and unbranched ribbon shaped folds. Posteriorly, the diameter of the small intestine decreases and the folds become higher and consist of zigzag pattern. Also, the wavy texture of the folds is decreased. At the most caudal region of the small intestine, the folds become broader, straighter and closer to each other.

The large intestine has a thin wall with few transverse small folds. The middle region has few longitudinal folds beside the transverse ones with the overlapping exists between the two types. Anteriorly, the folds tend to be deep and quite numerous, while they are finer and broader posteriorly. Generally, the large

intestine is lined by a series of short, low, straight, discontinuous, thin and randomly placed ridges.

## **4.6.2 The Histology And Histochemistry Of The Digestive Tract**

### **4.6.2.1 The Esophagus**

The esophagus is a thin-walled tube. It is lined by a single layer of epithelial tissue. The nature of this layer is mixed, so that it contains goblet cells and ciliated simple columnar epithelial cells, having an oval shaped-structure in the first and second third of the esophagus, (fig.31). The last part of the esophagus devoids of goblet cells and its mucosa is composed only of simple columnar epithelial cells (Figs. 34&35).

The epithelial cells are characterized by having either lateral or basal elongated nuclei in the anterior two thirds of its length (Fig. 33), while the cells in posterior one have basal rounded nuclei (Fig. 35). The esophageal epithelium is positively stained with PAS/AB (Fig. 36).

Another component of the mucosal layer is the muscularis mucosa (Figs. 31&37) which is located beneath the epithelial

tissue. The muscularis mucosa in the first and second parts of the esophagus is composed of 4-5 layers of circular smooth muscle fibers. The muscularis mucosa of the last part of the esophagus is well developed, built up from two layers of smooth muscles, inner thin circular and outer thicker longitudinal (Fig. -38). In between the epithelial layer and the muscularis mucosa of the esophageal posterior part a loose connective tissue layer lies and contains number of blood vessels, which is the lamina propria. The epithelium contains group of diffused lymphatic tissues.

The second layer, is the submucosa that is responsible for supporting. It consists of loose connective tissue which gives enough space for the blood vessels (Figs. 31, 33&38).

The muscularis externa of the esophagus has different structure in different regions. The most anterior part of the esophagus has a muscularis externa that is composed of two layers of skeletal muscles: inner circular and outer longitudinal (Fig. 32). The middle part of the esophagus has a single circular smooth muscle layer (Fig. 31), while the last part of the esophagus has two layers of smooth muscles: inner circular and outer longitudinal (Figs. 34&38).



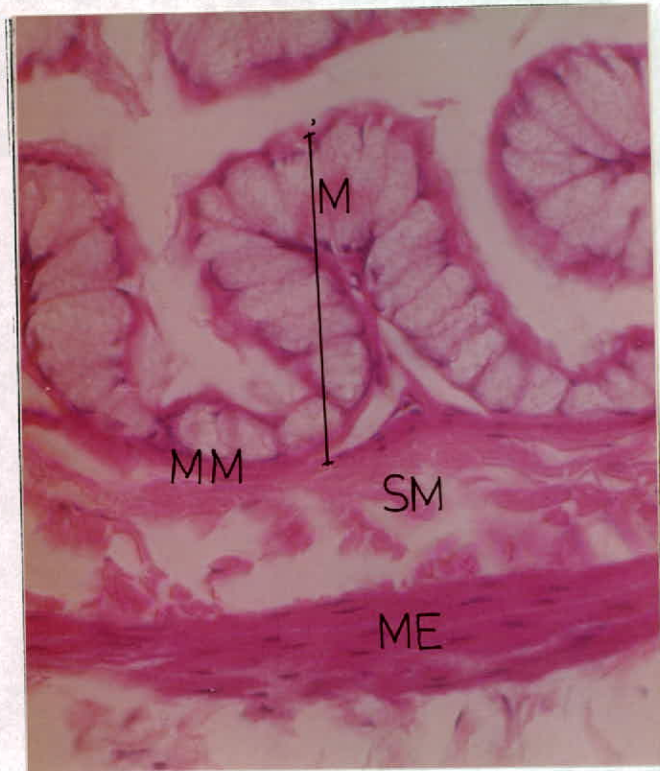


Fig. (31): The layers of the middle part of the esophagus, H&E, X462.

**M: mucosa; MM: muscularis mucosa; SM: submucosa; ME: muscularis externa.**

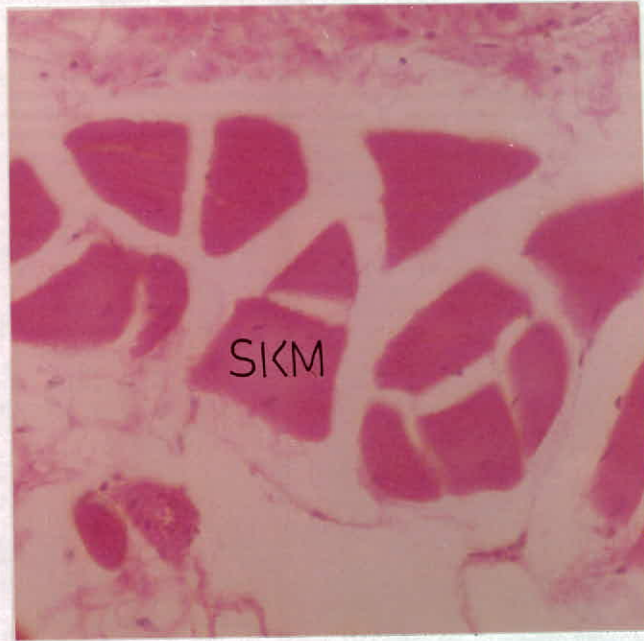

Fig. (32): The skeletal muscles of the muscularis externa in the first part of the esophagus, c.s., H&E, X175. **SKM: skeletal muscles**

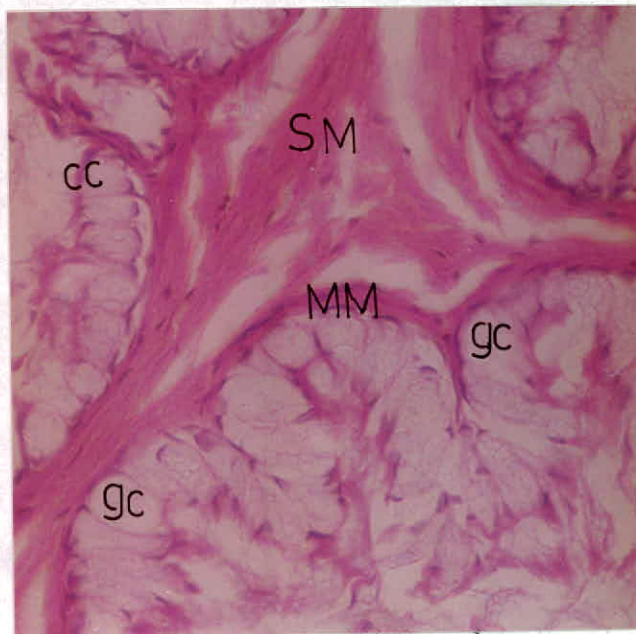


Fig. (33): The mucosa and the submucosa of the anterior parts of the esophagus, H&E, X350. **cc: ciliated cell ; gc: goblet cell; MM: muscularis mucosa; SM: submucosa**

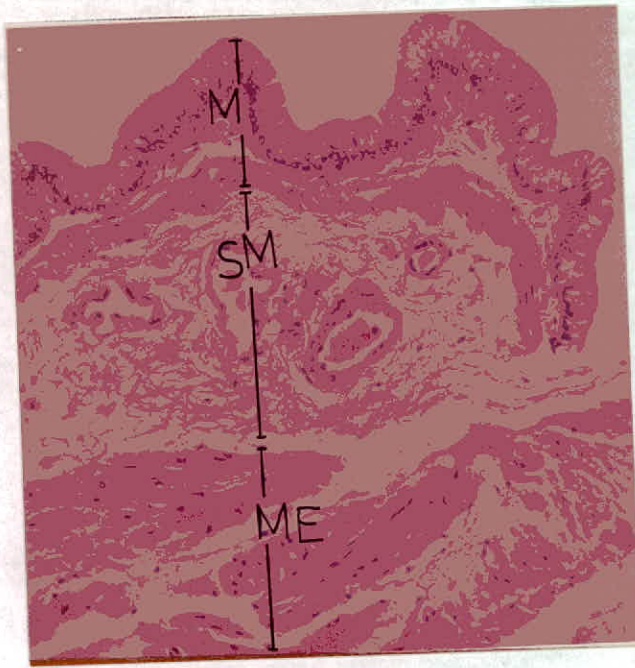


Fig. (34): General view of the last third of the esophagus, H&E, X140.

**M: mucosa; MM: muscularis mucosa; SM: submucosa**

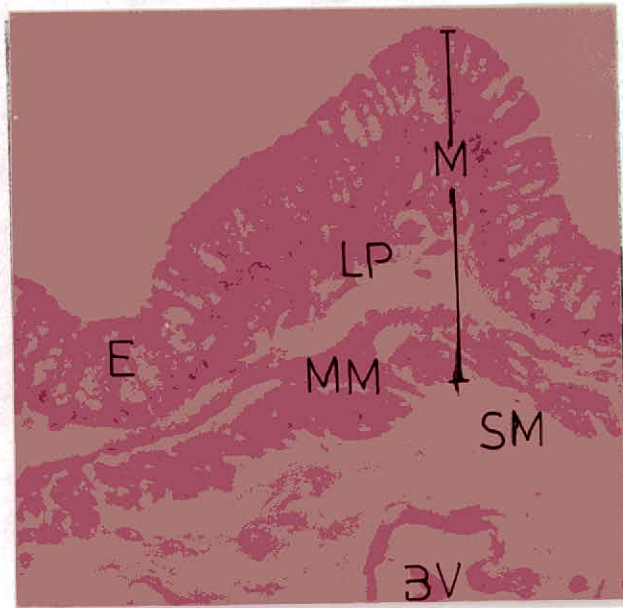


Fig. (35): The mucosa and submucosa of the last third of the esophagus, H&E, X350. BV: blood vessels; E: epithelium; LP: lamina propria; M:

**mucosa; MM: muscularis mucosa; SM: submucosa**



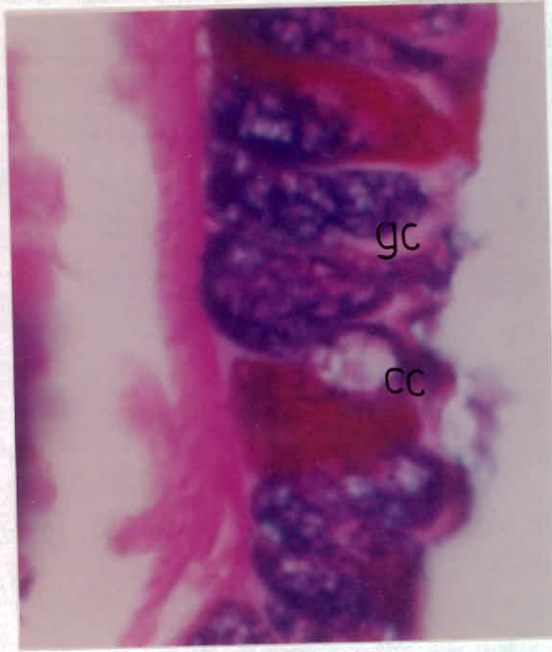


Fig. (36): Reaction of the mucosa of the esophageal first part with PAS/AB, X700. cc: ciliated cell; gc: goblet cell

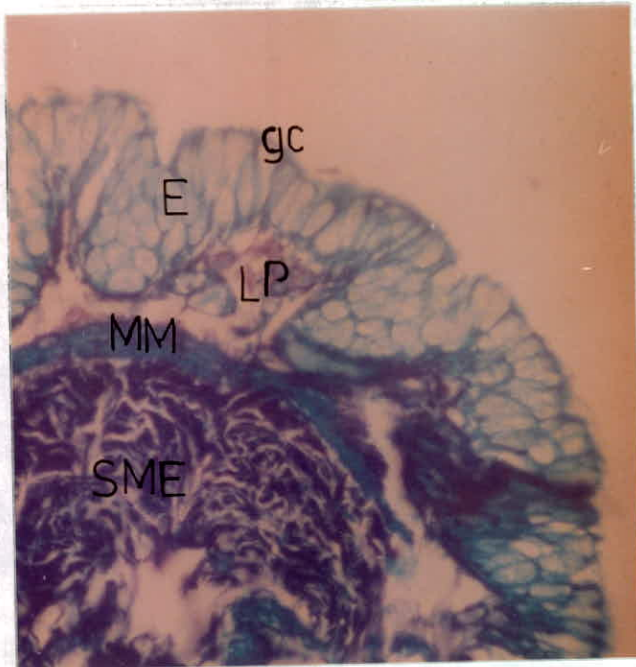


Fig. (37): The second part of the esophagus with FG, X280

**E: epithelium; MM: muscularis mucosa; SM: submucosa.**

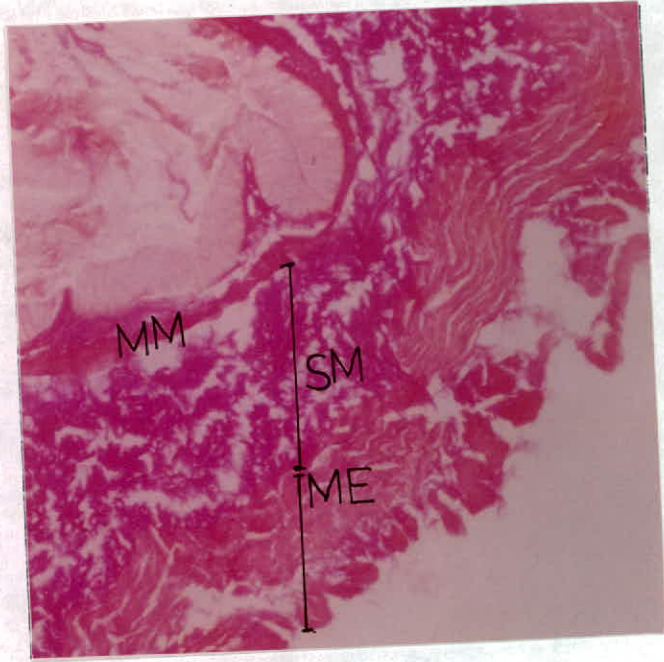


Fig. (38): The layers of the third part in the esophagus with VG, X140 :

**ME: muscularis externa ; MM: muscularis mucosa SM: submucosa.**

#### 4.6.2.2 The Stomach

The stomach, from a histological point of view, is divided into three regions: the cardiac, the fundus and the pylorus. It is the most dilated and strongest part among the digestive organs, where the gastric juice is secreted by the gastric glands. The stomach epithelium is folded deeply forming rugae on the surface and furrows called the gastric pits.

The cardiac portion of the stomach is lined by simple columnar epithelium (Fig. 39), that reacts positively with PAS, Fig. (47). The following portion is the fundic one, which is well distinguished by the high intensity of the gastric glands, which are surrounded by fibers of connective tissue (Fig. 48). The cells lining the free surface of the fundic region are of simple columnar type. The fundic glands, which pour their secretions in the gastric pits, are of two types: the mucous clear glands and the serous dark glands (Fig. 42). When the PAS and PAS/AB1 are applied to the fundic region, the simple columnar surface epithelium and the mucous gland cells, the neck cells, react with PAS positively, while the serous gland cells do not react with PAS (Figs. (49&50)).



In addition, only the surface simple columnar epithelium and the neck cells react positively with AB stains, while the serous glandular cells don't.

The distal part of the stomach is the pylorus, which is lined by simple columnar epithelial cells (Figs. 46&47). The tubular glands of the pylorus are shorter and less branched than those of the fundus. The pyloric glands are composed of the clear mucous secreting cells (Fig. 47). The pyloric glands consist morphologically of similar cuboidal cells contain rounded basally positioned granular dark nuclei. The reaction is positive with PAS and AB stains for the surface lining epithelium and the internal clear glandular cells (Fig. 51).

The muscularis mucosa of the stomach is well developed and consists of inner circular and outer longitudinal layers of smooth muscle fibers. In the cardiac portion it is thin (Fig. 39), while it is thick and highly developed in the fundus and the pylorus (Fig. 42).

The submucosa of the stomach is formed of highly vascularized loose connective tissue. It is of medium thickness among the three portions of the stomach (Fig. 41).

The muscularis externa is very thick in the stomach. It is consisted of two layers of smooth muscle fibers: inner circular and outer longitudinal with a very thin layer of connective tissue is present between the two muscle layers (Fig. 40). This arrangement of the fibers (smooth muscle and connective tissue) was assured by using the FG staining procedures (Fig. 52).

The most outer layer in the stomach is the serosa, which is composed of simple squamous epithelial cells (Fig. 40). This layer resembles the outer border of a gastric section as it is composed of connective tissue lined with single layer of squamous epithelial cells.

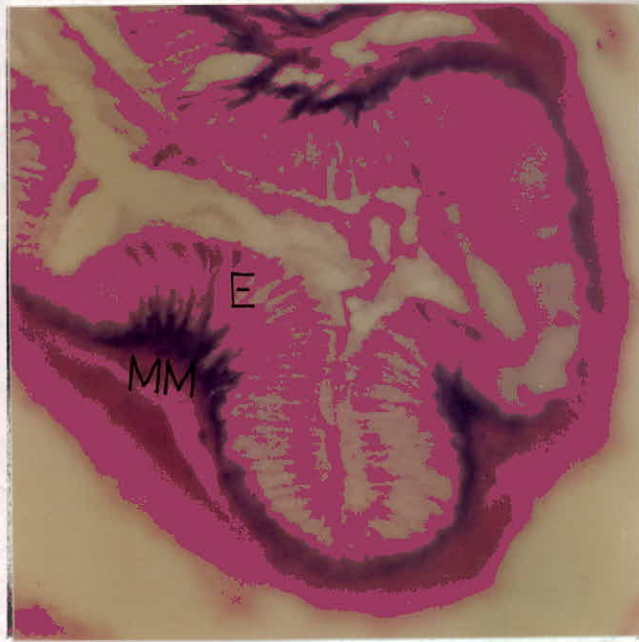


Fig. (39): The mucosal layer of the cardiac portion of the stomach, H&E, X350. **E: epithelium; MM: muscularis mucosa.**

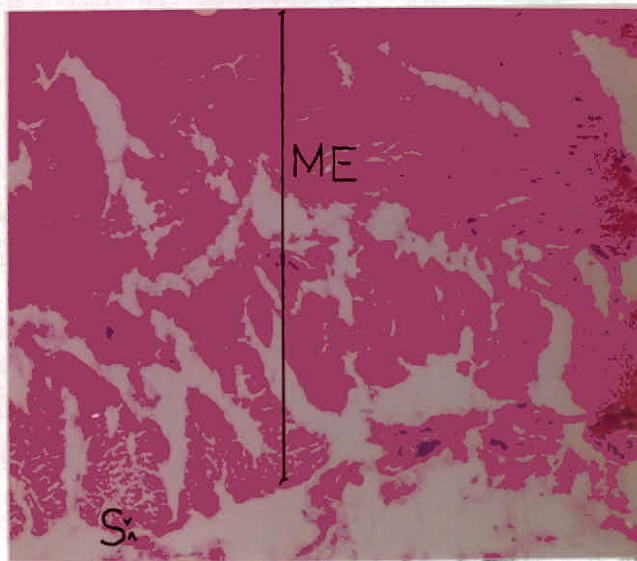


Fig. (40): The muscularis externa and the serosa of the stomach, H&E, X175. **Two layers of the muscularis externa: ME; simple layer of serosa: S.**



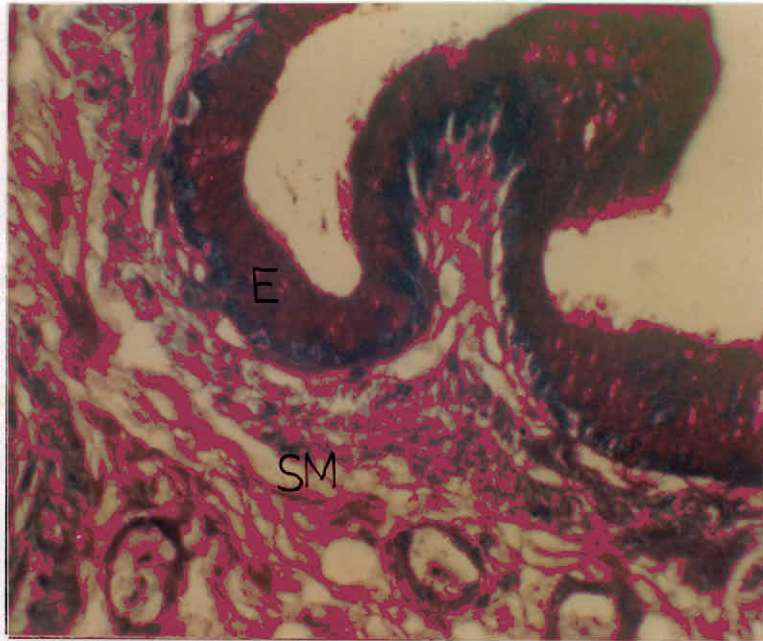


Fig. (41): The epithelium of the cardiac region of the stomach reacts positively with PAS, X350. **E: epithelium; SM: submucosa.**

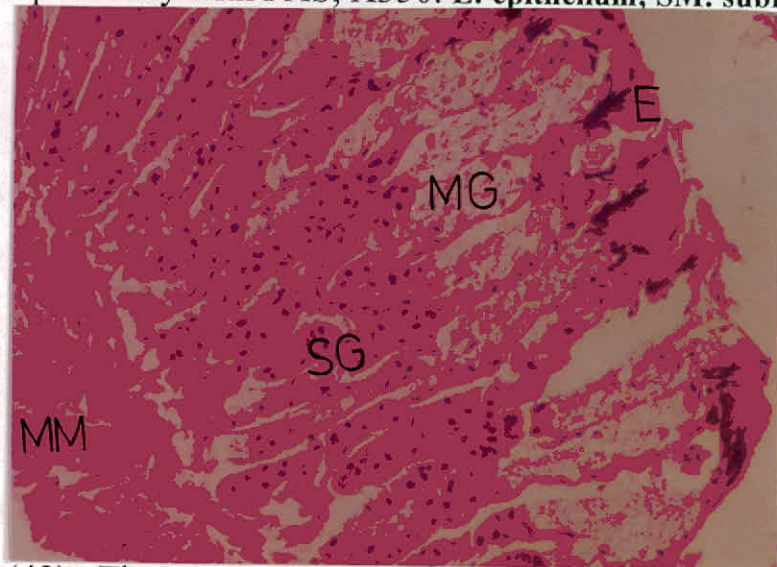


Fig. (42): The gastric mucosa in the fundus consists of: **epithelial layer: E; muscularis mucosa: MM; mucous glands: MG; serous glands: SG, H&E, X231.**

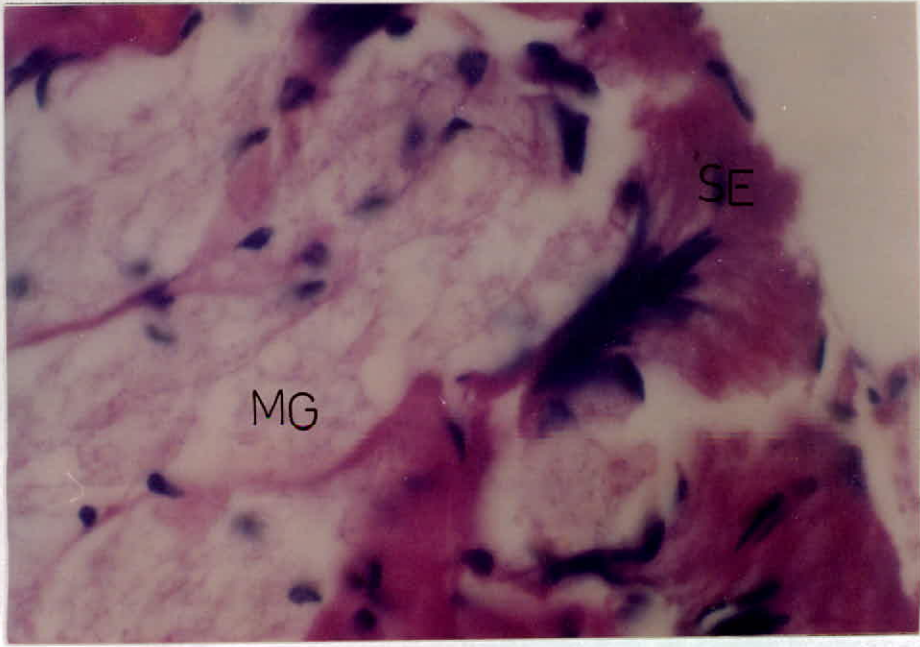


Fig. (43): The surface epithelium of the fundic region in the stomach, H&E, X875. SE: surface epithelium; MG: mucous glands.

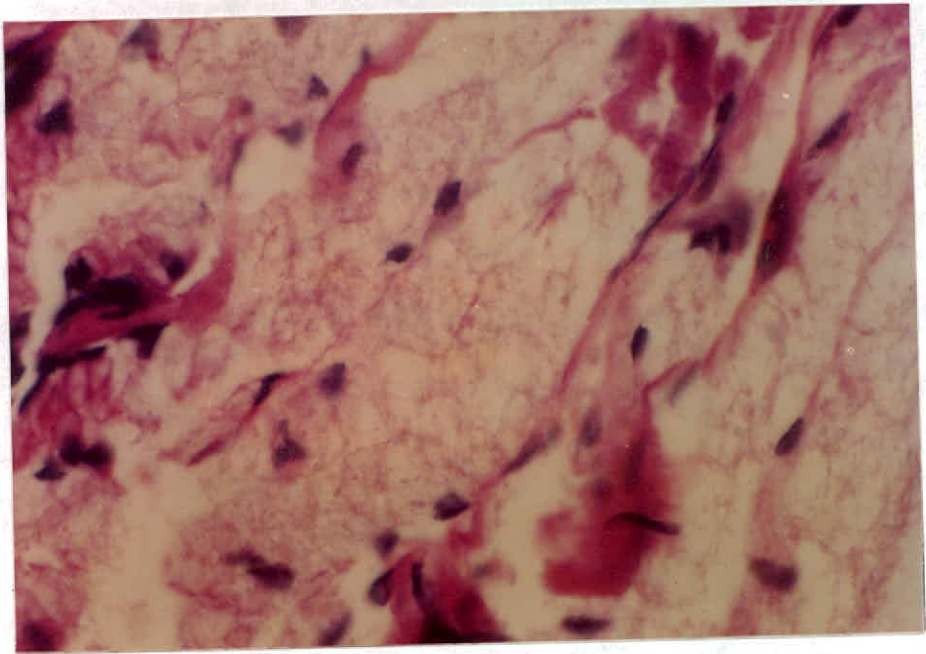


Fig. (44): The mucous glands of the fundic region of the stomach, H&E, X875.



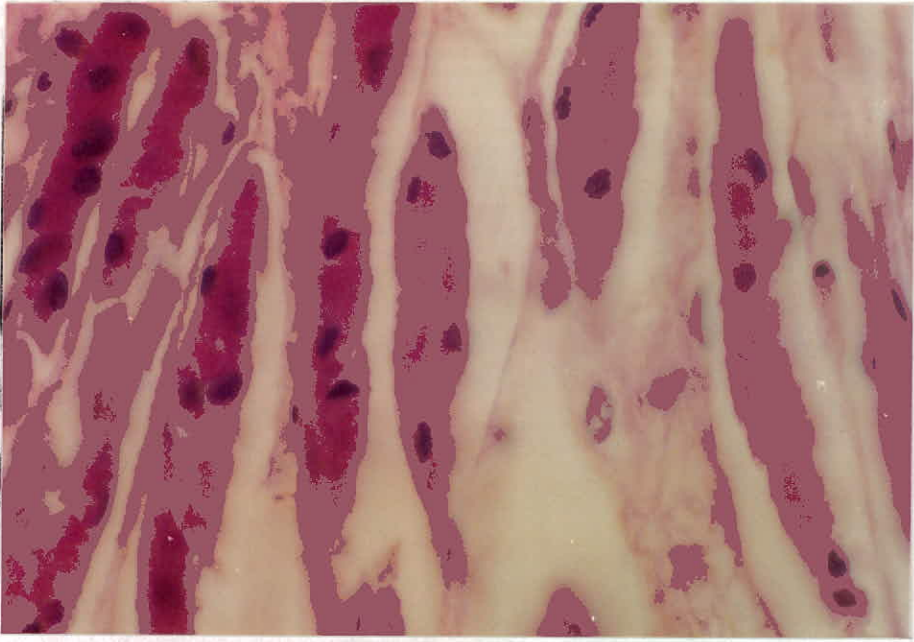


Fig. (45): The serous glands of the fundic region of the stomach, H&E, X875.

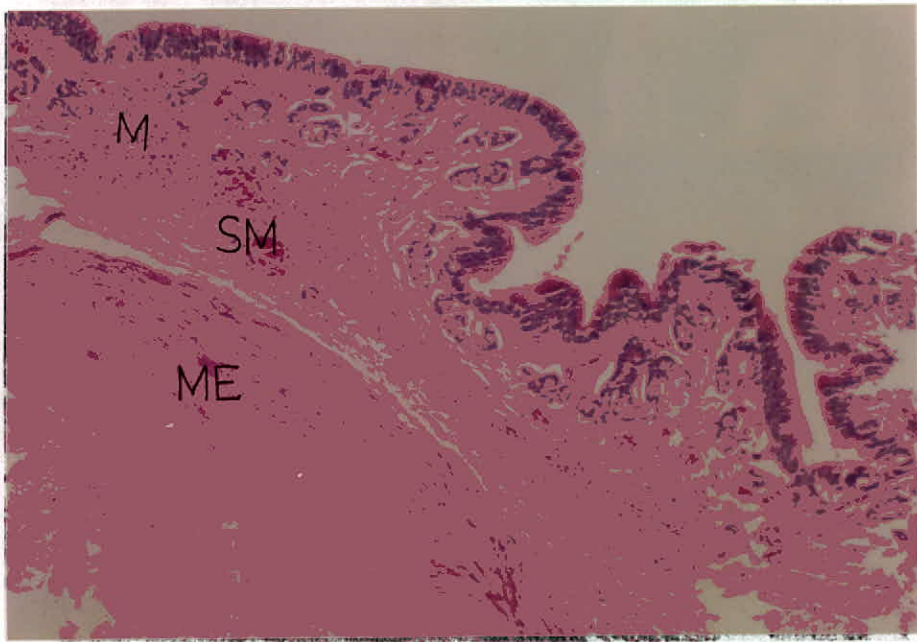


Fig. (46): General view of the pyloric region in the stomach showing the three layers: M; mucosa; ME: muscularis externa; SM: submucosa, H&E, X175.



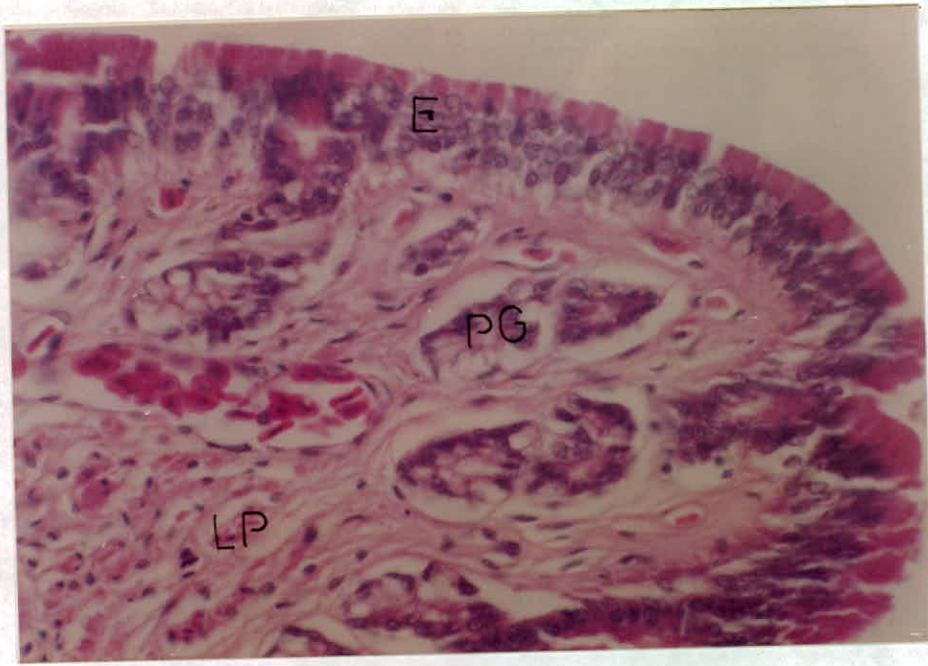


Fig. (47): The mucosal layer of the pylorus in the stomach, H&E, X350. E: epithelium; LP: lamina propria; PG: pyloric glands.

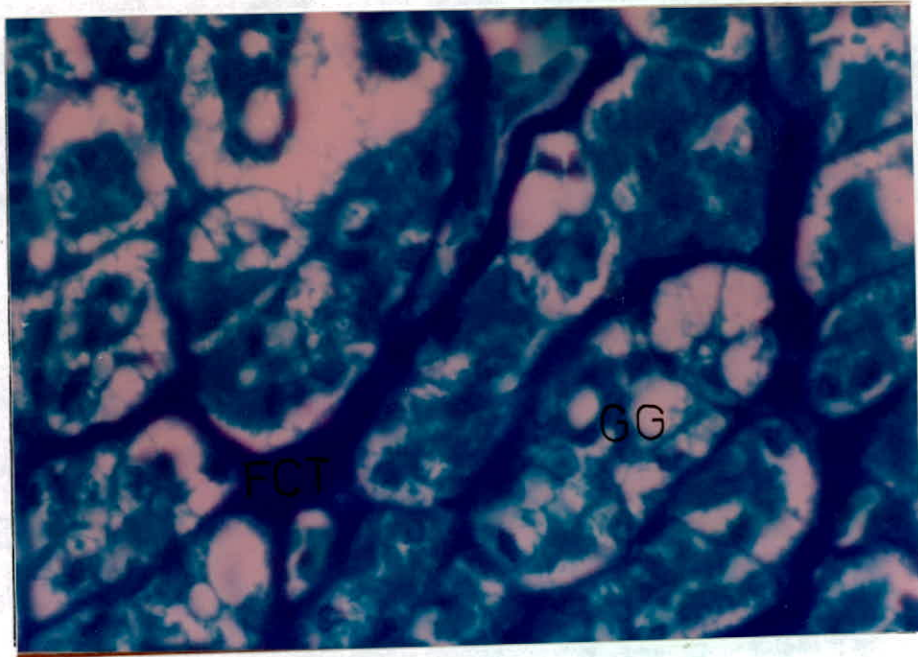


Fig. (48): The fundic region of the stomach, FG, X600, FCT:connective tissue fibers; GG: gastric glands.

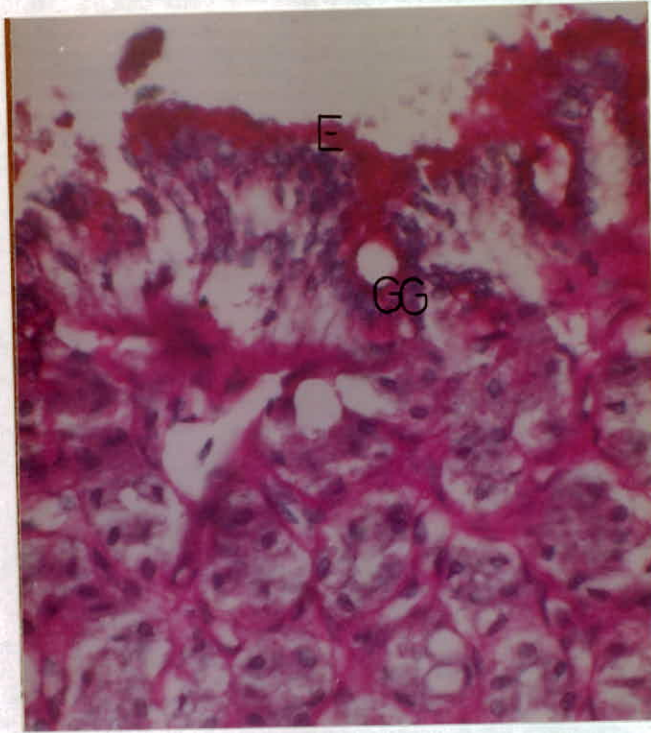


Fig. (49): Reaction of the fundic region mucosa of the stomach with PAS, X462. E: epithelium; GG: gastric glands.

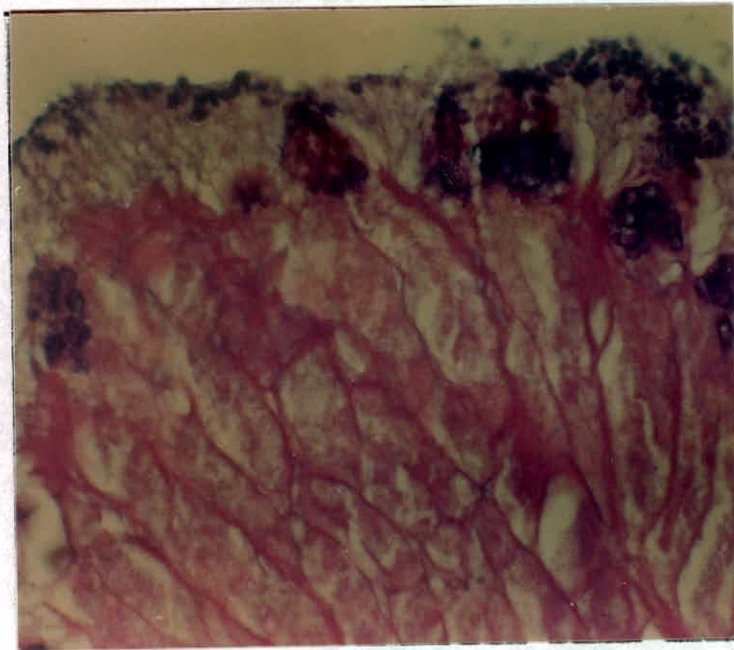


Fig. (50): Reaction of the fundic region mucosa of the stomach with PAS/AB2.5, X350.



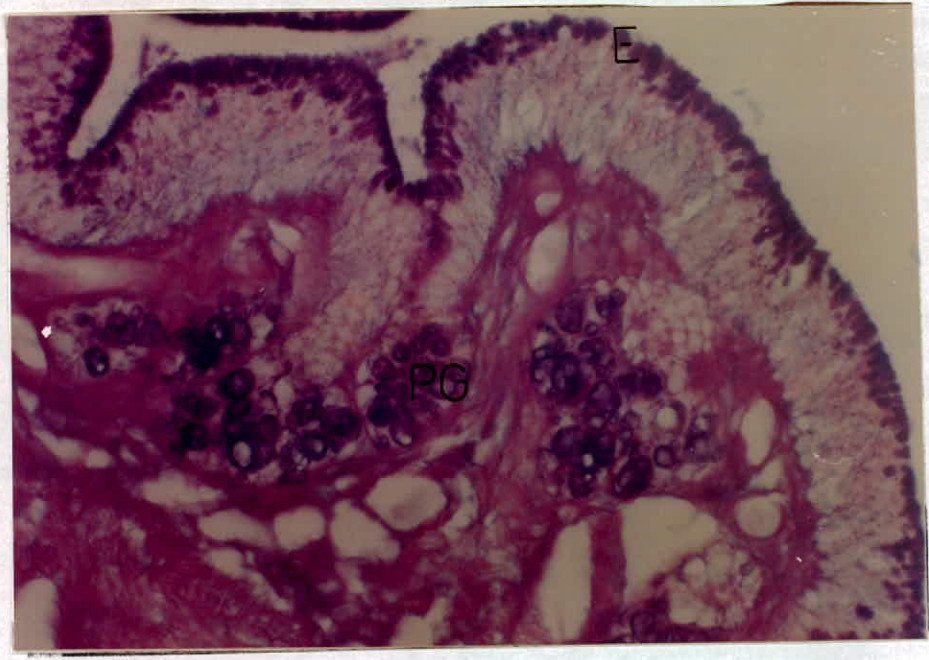


Fig. (51): Reaction of the pyloric region mucosa with PAS/AB1, 40x2.5. E: epithelium; PG: pyloric gland.

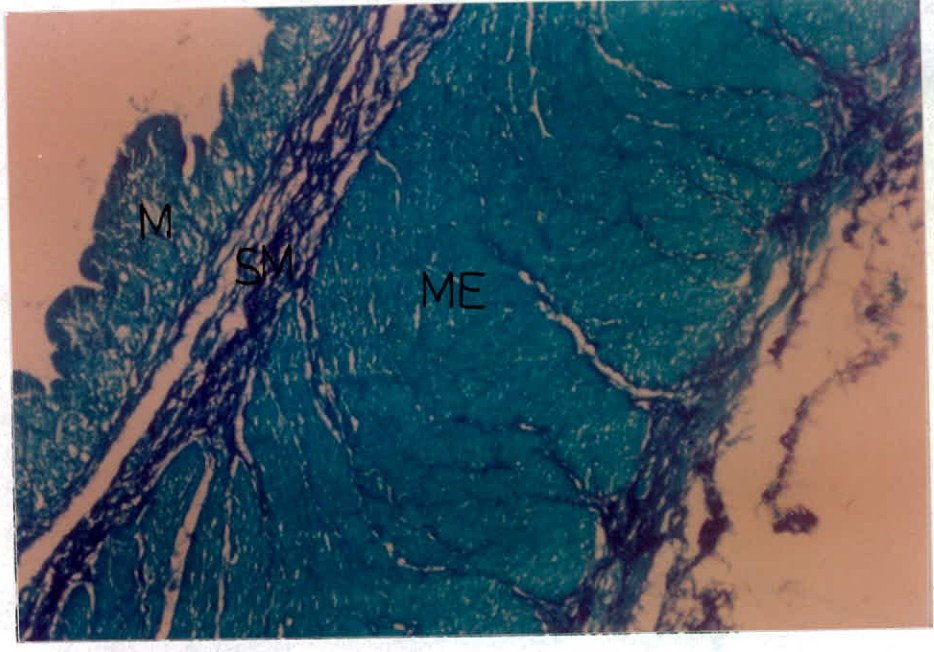


Fig. (52): The muscularis externa of the pyloric region of the stomach, FG, X115.5. M: mucosa; ME: muscularis externa; SM: submucosa.



#### 4.6.2.3 The Small Intestine

The intestinal epithelium is highly folded, each fold is called a villus (Fig. 53). The mucosa of the small intestine is composed of a simple columnar epithelial cells having mainly absorptive function (Fig. 53). Those are known as enterocytes, or marginal cells. Other cell type is also found in the small intestine, which is the goblet cell (Fig. 57), which randomly placed between the enterocytes. The enterocytes neither react with PAS nor with PAS/AB (Fig. 59) stains. However, the goblet cells do react positively with both stains. The positive reaction of the goblet cells with AB indicates the acidic nature of the mucopolysaccharides contained in the intestinal goblet cells. Paneth cells are not found among the intestinal epithelium. This study reveals the absence of any sort of glands in the small intestine. Each villus contains large number of blood vessels and lacteal vessels which are responsible for fatty acids transportation (Fig. 56). The frequency of the lacteal vessels is the highest in the middle part of the small intestine in comparison to the other two parts (Figs. 57-59).

The muscularis mucosa is poorly developed (Fig. 58). The epithelium is followed by the submucosa, which is here composed of loose connective and contains the continuation of the blood vessels exist in the villi (Fig. 56).

The muscularis externa is well developed, it consists of two smooth muscle layers: the inner circular and the outer longitudinal (Fig 54). The two layers of muscles are separated by a thin layer of connective tissue fibers (Fig. 55).

The serosa of the small intestine adheres to the outer longitudinal layer of muscularis externa, composed of a single layer of squamous epithelium (Fig. 55). It is followed by connective tissue which is part of the mesentry.

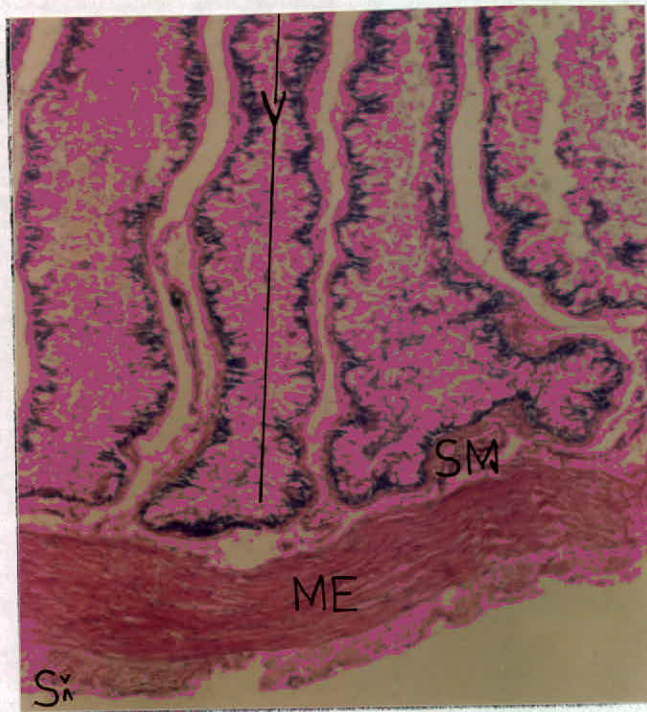


Fig. (53): General view of the small intestine layers, H&E, X35.

**ME: muscularis externa; S: serosa; SM: submucosa; V: villus**

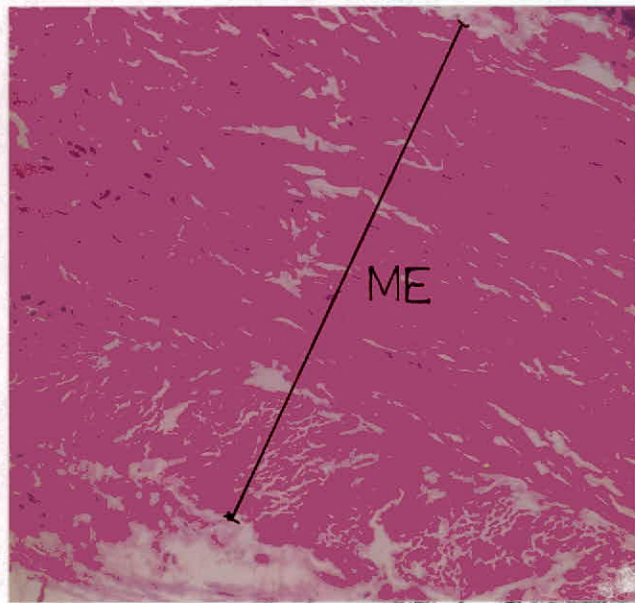


Fig. (54): The muscularis externa of the small intestine, notice the inner circular and the outer longitudinal layers of the smooth muscles, H&E, X231. **ME: muscularis externa.**



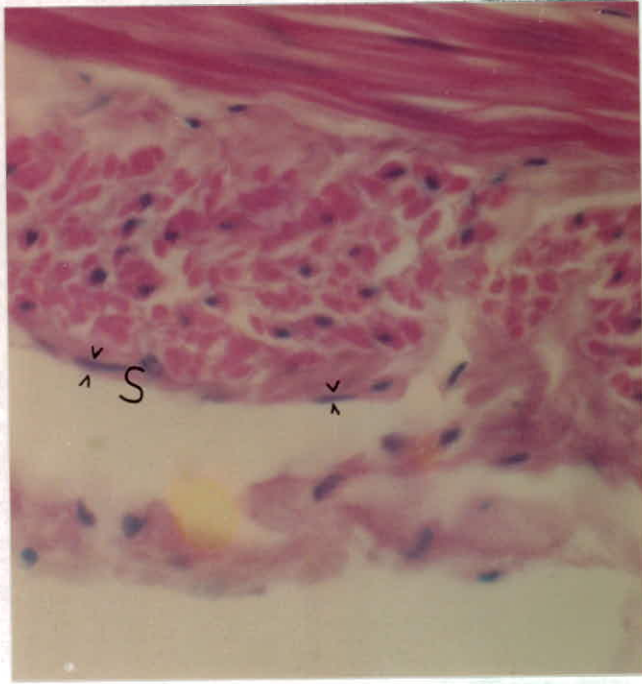


Fig. (55): The serosal layer of the small intestine, H&E, X462.

S: serosa.

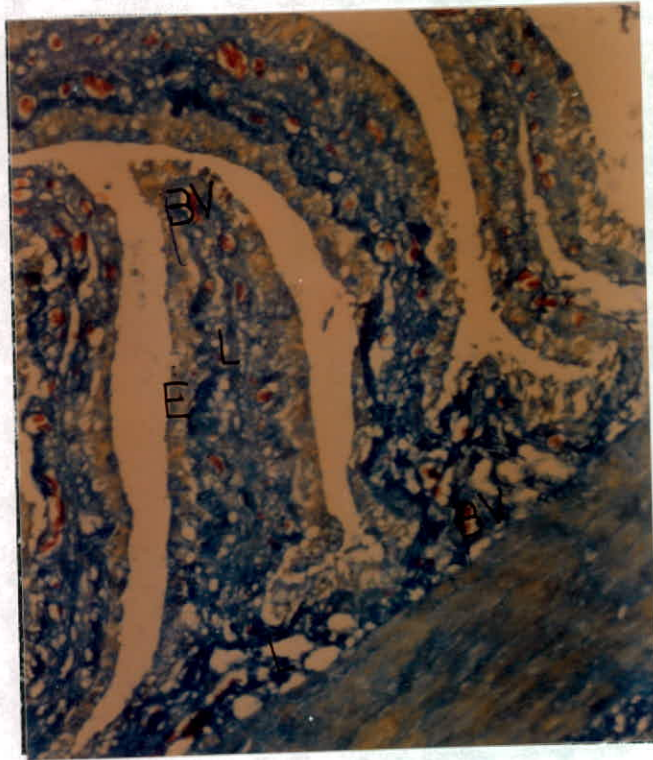


Fig. (56): The villus of the small intestine contains: BV: blood vessels; E: epithelial layer; L: lacteal vessel., MTS, X115.5.

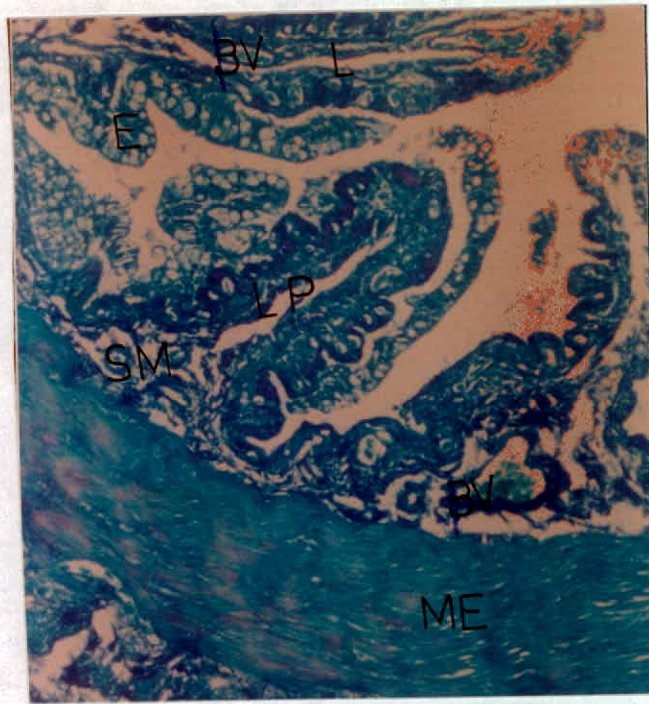


Fig. (57): Different layers of the small intestine, FG, X115.5

BV: blood vessel; E: epithelium; L: lacteal; LP: lamina propria; ME: muscularis externa; SM: submucosa.

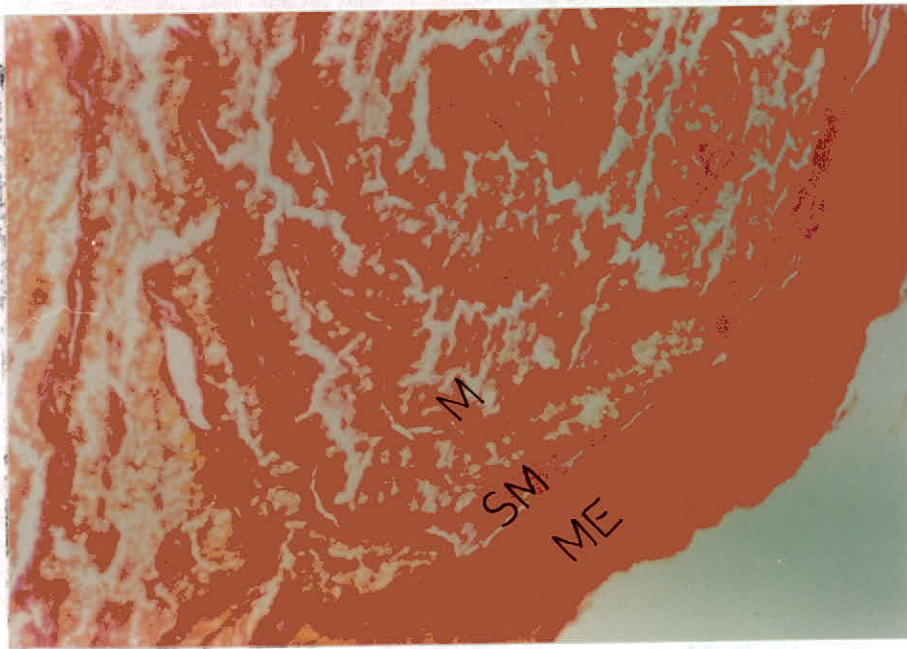
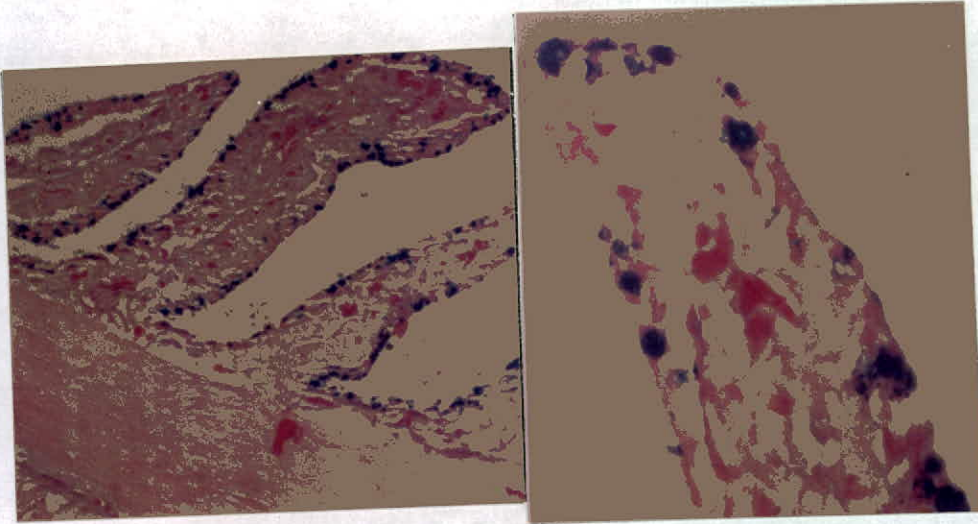


Fig. (58): Submucosa and muscularis externa of the small intestine,

VG, X87.5 ME: muscularis externa; SM: submucosa.





(A): X70

(B): X350

Fig. (59): The positive reaction of the intestinal epithelial cells with AB2.5. e: enterocytes; gc: goblet cells



#### 4.6.2.4 The Large Intestine

The lining of the large intestine is composed of simple columnar epithelial cells and goblet cells (Fig. 60). This composition is preserved along its whole length. The goblet cells are found to react positively with both PAS and AB (Fig. 61), while the columnar cells do not. This suggests the absorptive function of them which is also supported by the lamina propria containing large quantity of blood vessels (Fig. 62). The intestinal mucosa is invaded by a lymphatic tissue.

The submucosa is a network of loose connective tissue (Fig. 62). The muscularis externa is composed of inner circular and outer longitudinal layers of smooth muscle. It is followed by a simple squamous epithelium which represents the intestinal serosa.

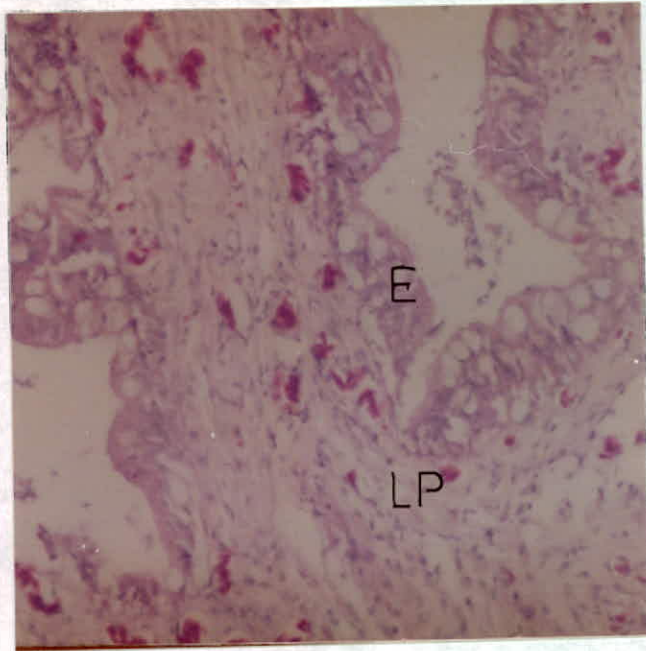


Fig. (60): The mucosal layer of the large intestine, H&E, X175.

**E: epithelium; LP: lamina propria.**

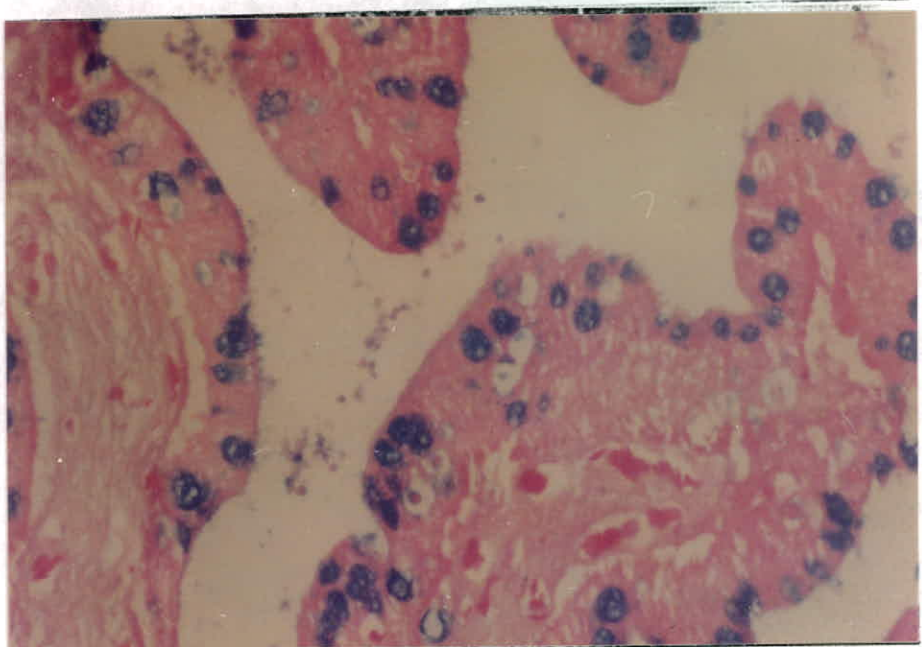


Fig. (61): The reaction of the intestinal epithelial cells with AB2.5 X175. **ce: columnar epithelial cell; gc: goblet cells.**

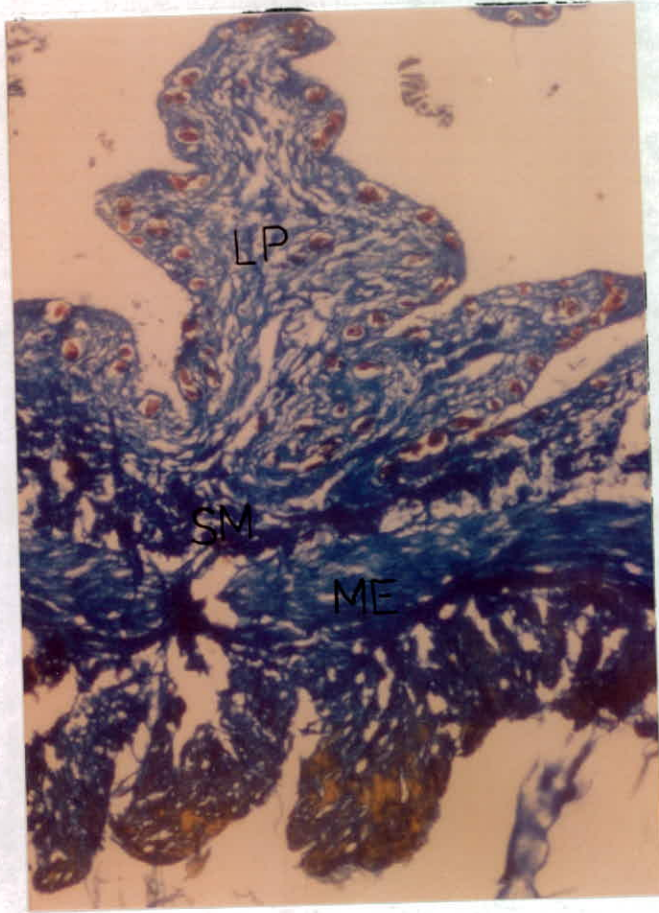


Fig. (62): The different layers of the large intestine, MTS, X115.5. LP: lamina propria; ME: muscularis externa; SM: submucosa.



#### 4.6.2.5 The Cloaca

A stratified squamous epithelium is the lining of the cloaca (Fig. 63). The submucosa of the cloaca is well developed formed of loose connective tissue invaded by large number of veins, arteries and lymphatic aggregations. (Fig. 63). The muscularis externa is composed of longitudinal and circular skeletal muscles (Fig. 64).

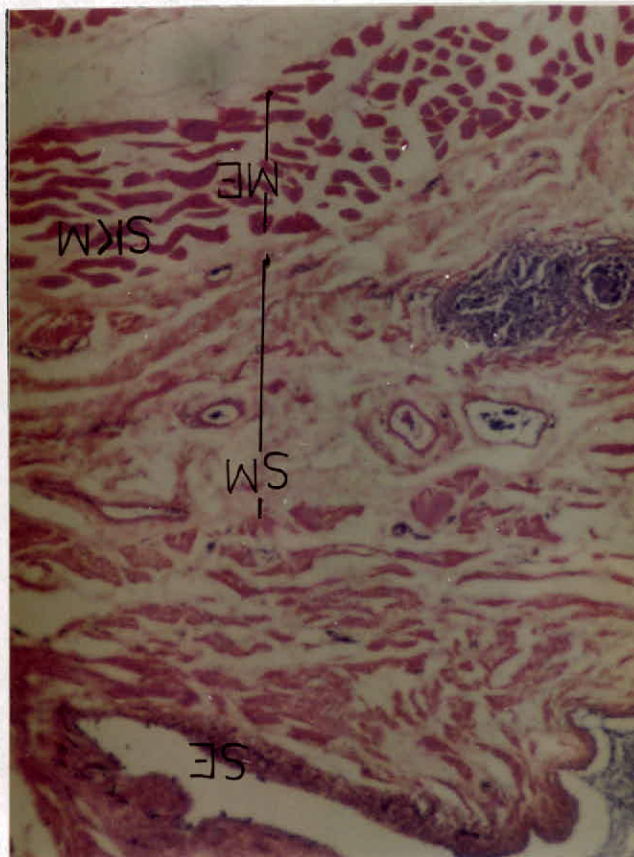


Fig. (63): General view of the cloaca, H&E, X56

**BV: blood vessels; ME: muscularis externa; SE: squamous epithelium; SM: submucosa; SKM: skeletal muscle fibers of the muscularis externa.**

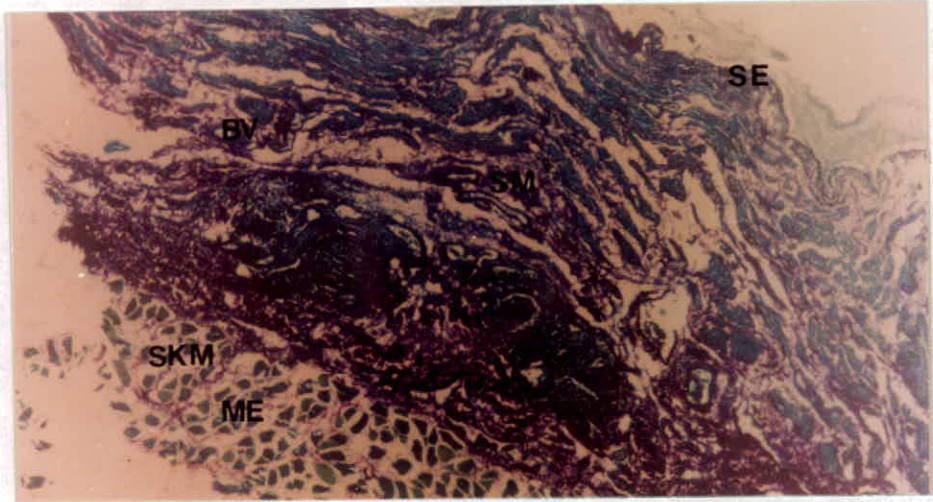


Fig. (64): The layers of the cloaca, FG, X13.5.

**BV: blood vessels; ME: muscularis externa; SE: squamous epithelium; SKM: skeletal muscle fibers of the muscularis externa; SM: submucosa.**

#### 4.7 Duvernoy's Gland

The main venom gland of *M.m.insignitus* lies directly under the skin to which it is connected by loose connective tissue. It extends from the 4<sup>th</sup> supralabial scale to the end of the mouth corner (the 8<sup>th</sup> supralabial ). (Fig. 65). The gland is enveloped by a capsule of connective tissue. It is yellowish oval-shaped structure with toughed texture. The anterior part of the gland lies under the eye, while the rest of it extends posteriorly. The gland is composed of highly branched tubules.

Duvernoy's gland is fixed in its place by two ligaments. The ligamentum quadrato-maxillare (LQM) that connects the capsule of the gland with the quadrato-mandibular articulation. The ligament passes over the muscles MAMEM and MAMEP. The same ligament connects the gland capsule with the postorbital bone and finally with the lateral median part of the maxilla.

Further fixation of the gland is achieved by the ligamentum internum quadrato-glandular (LIQG). It arises from the inner side of the posterior half of the gland, extends upward to reach the insertion of MAMES. From the inner ventral side of the



gland, the duct arises and it extends ventrally to reach the grooved fangs which are positioned at the posterior end of the maxilla.

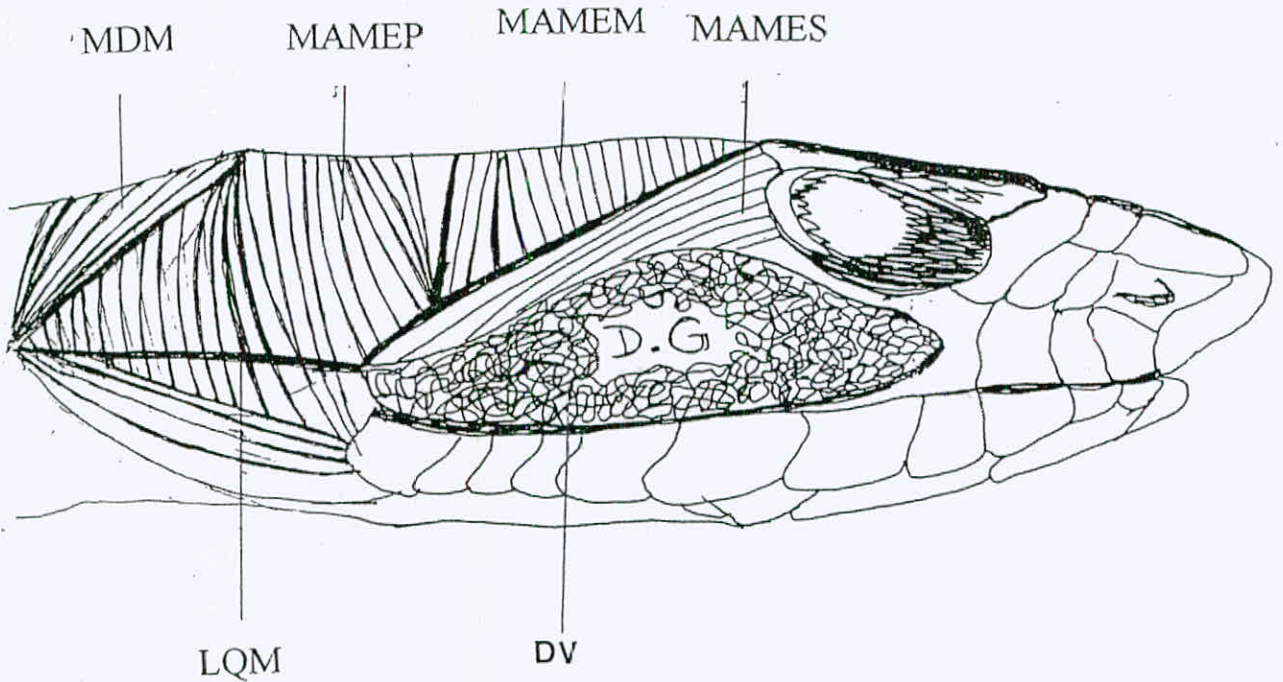


Fig. (65): The location of the Duvernoy's gland.

**D.V:** Duvernoy's gland; **LQM:** ligament quadrato-maxillare; **MAMEM:** muscle adductor mandibulae externus medialis; **MAMEP:** muscle adductor mandibulae externus profundus; **MAMES:** muscle adductor mandibulae externus superficialis; **MDM:** muscle depressor mandibulae.

**5**

**DISCUSSION**

**AND**

**CONCLUSIONS**

### 5.1 The External Morphology

The present study reveals that the adult montpellier snake has brown-gray coloration, while the juvenile individuals have lighter color with dark spots at the neck region. Similar findings were obtained by El-Oran *et al.* (1994) and Schleich *et al.* (1996) for *M.monspessulanus*.

The obtained results of this study demonstrate that the middorsal scale count of *M.m.insignitus* is 19 and the tail occupies about 25% of the whole body length (Table 1). Previous study which was proposed by Woerkom (1982) found that the middorsal scale count of *M.m.monspessulanus* was 19, while it was 17 for *M.m.insignitus*. He also found that the percentage of the tail was 15%, while Reed and Marx (1959) found it to be 25%.

### 5.2 The Anatomy Of The Skull

The skull of *Malpolon monspessulanus insignitus* has a triangular shape, constructed from group of solid bones (Fig. 12). It attains the generalized colubrid skull pattern with long postorbital braincase. These findings coincide with that was found by Cundall (1981) and Cundall and Rossman (1984). Retaining the classical



colubrid skull doesn't mean that the montpellier snake has not got its own special characteristics features. The size of the fossa orbitalis in *M.m.insignitus* skull is very large which causes the narrowing of the frontals width and leaving enough space for the large eyes (Fig. 12).

The large eyes of *M.m.insignitus* may be considered as distinguished feature for this species. However, Cundall (1981) and Cundall and Rossman (1984) found smaller eyes located in smaller fossae orbitalis in a group of colubrids they have studied. The size of the optic fenestrae (as named by Cundall, 1981) displayed interspecific variation. The large eyes of the montpellier snake may suggest a diurnal activity of this species allowing for better hunting of its prey. Because majority of them is located between the bushes and in the vegetated lands.

The fossa orbitalis of *M.m.insignitus* is very large and is surrounded by prefrontal, frontal and postorbital bones with opened lateral side (Fig. 14). The fossae orbitalis of the studied burrowing snakes by Underwood and Kochva (1993) were found to be very small and surrounded by maxilla, prefrontal, frontal and postorbital bones, it may be explained that the burrowing snakes don't need large eyes because of their living in dark habitat (sand). The

arrangement of bones around the fossa orbitalis of the montpellier snake gives further evidence for the need of large eyes which may assist better diurnal activity. This study suggests that the size of the fossa orbitalis may be a valid tool in taxonomy.

The results of this investigation indicate that the premaxilla bone of *M.m.insignitus* has two processes which don't reach the maxilla (Fig. 12). The same situation was found in most henophidians (Underwood and Kochva, 1993).

This study reveals that the articulation of the nasal bone with the frontal is very narrow in the montpellier snake (Fig. 12). Underwood and Kochva (1993) drew the skull of the burrower, *Atractaspis* with a broad suture between the nasal and the frontal, which is thought to be the source of support for the nasal bone during the burrowing process. Also, the nasal bone of the burrowing boid *E.jayakari* was found to be well articulated with the frontal bone (Mohammad,1991). The nasal bone of *M.m.insignitus* is not in need to be supported that much, because it doesn't possess the burrowing activity reported in the burrower. This thought was earlier suggested by Haines (1967), when he found that many skull features are

adaptive ones for the burrowing habit and the fusion of the nasal bone was one of those features.

The dentiferous bones of *M.m.insignitus* hold large number of teeth. The maxilla, pterygoid, palatine and dentary bones, each bears 16-18, 17-19, 14-15 and 21-24 respectively (Fig. 14). Other colubrid snakes were found to possess also large number of teeth as reported by Cundall (1981) and Cundall and Rossman (1984). This finding is in contrary with Haines findings (1967), when he wondered about the reason that causes the colubrid snakes to have small number of teeth. On the other hand, the viprid snakes were found to have reduced number of teeth (maxilla=0, pterygoid=5-8, palatine=1-2 and dentary=3-6) (Dullemeijer, 1958) (Table 4). Moreover, the boid snakes were found to have small number of teeth (maxilla=8, pterygoi=8, palatine=4 and dentary=13) (Mohammed, 1991). Also, the atractaspids possessed teeth only on the dentary bone (=2), in addition to the fangs on the maxilla which are carried anteriorly (Underwood and Kochva, 1993).

The results obtained from this study suggest that the number of teeth may be related to the mechanism of predation. The viprids and atractaspids are poisonous snakes with anteriorly located fangs.



Whenever they bite, the prey will die very soon and it would be easy for the snake to ingest the prey and swallow it. However, *M.m.insignitus* has rear grooved fangs like some colubrids, which also may lack fangs and need to hold the prey during swallowing. The teeth may help the snake to fix the prey during predation and swallowing.

Table (4): number of teeth carried on each dentiferous bone in the montpellier snake and other species belonging to different families.

Species or family	Number of teeth on:				Position of fangs	Reference
	maxilla	pterygoid	palatine	dentary		
<i>M.m. Insignitus</i>	16-18	17-19	14-15	21-24	posterior	The present Study, 1999
Viprids	0	5-8	1-2	3-6	anterior	Dullemeijer, 1958
<i>Eryx jayakari</i>	8	8	4	13	absent	Mohammed, 1991
<i>Atractspis</i>	0	0	0	2	anterior	Underwood & Kochva, 1993

The author finds out that the montpellier snake has relatively large crest of fossa mandibularis of the lower jaw (Fig. 14). Underwood and Kochva (1993) noticed that the crest of fossa mandibularis was highly reduced in *Atractaspis*. On the other hand, viprids were found to possess that crest as reported by Dullemeijer (1958). The presence of this crest in the lower jaw of the montpellier snake may help to strengthen the muscle adductor mandibulae posterior and muscle pseudotemporalis which also inserts there and the muscle pterygoideus which originates from there that may give it more support during mouth opening (Fig. 17). The latter muscle was suggested to have a chief role in mouth opening (Bolt and Ewer, 1964).

### 5.3 The Anatomy Of The Head Muscles

The present investigation finds that the montpellier snake lacks of the muscle compressor glandulae. This was reported in the members of the solenoglypha (Haas, 1952) and the family Viperidae (Dullemeijer, 1958 and Kochva, 1958 and 1962). This muscle was found to be located over the venom gland and suggested to participate with the muscle adductor mandibulae externus superficialis in squeezing the venom out of the venom gland during

envenomation. In order to compensate for the absence of the muscle compressor glandulae, *M.m.insignitus* has got a well developed muscle adductor mandibulae externus superficialis (Fig. 16) in comparison to the thinner one found in the viprids as stated by both Dullemeijer(1958) and Kochva(1958 and 1962). This study doesn't show that much difference amongst the head muscles of the montpellier snake and other colubrid snakes as suggested by Cundall(1986).

*M.m.insignitus* lacks the muscle levator anguli oris which supports what had been mentioned by (Haas, 1973). He generalized the absence of this muscle in the members of the family Colubridae. The loss of this muscle was considered to attain simpler pattern of the muscle adductor mandibulae externus superficialis in the colubrid snakes by the same author.

The muscle pterygoideus of the montpellier snake inserts on the pterygoid (Fig. 17), while it was found to be formed of four parts as reported by Dullemeijer (1958) in the viprids. He stated that the muscle pterygoideus reached the pterygoid bone after passing the lower jaw with its two parts, other part reached the venom gland. The fourth part which was called the muscle pterygoideus accessorius



inserted on the maxilla bone. Kochva (1962) divided this muscle's insertion into two parts: one at the pterygoid bone and the other at the maxilla bone also called the muscle pterygoideus accessorius presented in the viperids. Moreover, Kochva (1958) found that this muscle reached the maxilla, the capsule of the venom gland and the sheath of the fang in *V.palaestinae*. The fangs of the family Viperidae are situated in the most anterior part of the maxillae, so the muscle pterygoideus branches may be needed for more force to compress the gland and to create enough pressure for the passage of the venom anteriorly to the fangs. On the other hand, *M.m.insignitus* has the fangs on the most posterior sites of the maxillae, directly beneath Duvernoy's gland (Fig. 65). So it doesn't need that much force to pass the secretion to the fangs, since the distance is very short.

This study shows that the montpellier snake's MIMP inserts on the midventral raphe. However, it was found to insert on the ligamentous connective tissue (symphysis) that connects the two halves of the lower jaw in *Natrix* (Luboch, 1933).

#### 5.4 The Anatomy Of The Vertebrae

The obtained results show that the centrum of the atlas had fused to the axis forming a pivot point with the atlas and skull of the montpellier snake. Such fusion gives the head more freedom in its rotation movement around the body axis (Weichert, 1970). This adaptation enables the montpellier snake to scan wider area and find out its prey with the help of the large eyes.

The present investigation indicates that the hypapophysis is highly reduced in the trunk vertebra of the montpellier snake. However, Hoffstetter (1939) found the hypapophysis to be present in the trunk vertebrae of *Natrix*. Underwood and Kochva(1993) found that *Atractaspis* trunk vertebrae had ventral haemal keel, while Underwood (1992) found a posterior hypapophysis in the trunk vertebra in some boid snakes. This may suggest the contribution of the anatomy of the vertebral column in snake taxonomy. The obtained results show the different vertebral shape and size in different vertebral column regions. Moreover, Mohammad (1991) found the same situation to be present in the vertebral column of the boid snake *E.jayakari*.

The presence of a well developed neural spine is noticed in the vertebrae of *M.m.insignitus* throughout this study. When the vertebrae of burrower snakes (Anilidae, Xenopeltidae, Uropeltidae, Typhlopidae and Leptophlopidae) and certain aquatic forms are examined, the neural spine was found to be highly reduced (Hoffstetter and Gayrard, 1964). The developed neural spine may suggest more advanced status of the snake.

The presence of haemapophysis in the cloacal vertebra of the montpellier snake coincides with the long tail it has got. However, in Scolecophidia the tail is much shortened, the haemapophysis does not develop (Hoffstetter and Gasc, 1969).

## 5.5 The Anatomy Of The Reproductive System

### 5.5.1 The Female Reproductive System

Through the present study, the right ovary of the montpellier snake is found to be situated anterior to the left one, which results in having longer right oviduct. Furthermore, the right ovary is larger than the left ovary, Fig. (25). The anteriorly situated and larger right ovary was also recorded by many authors for many snakes: *Thamnophis* (Cielak, 1945), *Xenochrophis* (Bergman, 1951), *Natrix* sp.(Bragdon, 1953 and Betz, 1963) and *Ptyas* (Das, 1960).



The montpellier snake has got two oviducts, one on each side. On the contrary, Gadow (1912) stated that the ovaries and oviducts of the reptiles are not always developed equally at the two sides. For example, the loss of the left oviduct in the Australian *Typhlops* (Robb, 1960 and Robb and Smith, 1966), Leptotyphlopidae (Underwood, 1967) and some Colubridae (Underwood, 1967). This finding led Clark (1970) to suggest that the feature is an adaptive one in the burrowing snakes. Furthermore, the two oviducts of the montpellier snake are separated along the tract and don't fuse at any level of their length. The oviducts of some snakes were observed to join and form a median uterus with a thicker wall (Saint Ange, 1856, Leydig, 1857 and Cope, 1898).

### 5.5.2 The Male Reproductive System

The present investigation of *M.m.insignitus* male genitalia reveals the presence of non lobulated testes (Fig. 26). However, the testes of the Blind snake were recorded to be lobed and the lobes were located distal from each other at various intervals of length (Fox, 1965). This snake belongs to primitive group of snakes (Typhlopidae), while the montpellier snake belongs to more advanced group (Colubridae). This may suggest that the lobed testes is a primitive characteristic. The lobed testes were obviously taller

than the unlobed ones, so they were connected to taller epididymis. Since the male montpellier snake has unlobed testes, it has shorter epididymis at the mediiodorsal side of each testis.

The obtained results indicate the presence of smooth surface of *M.m.insignitus* hemipenes (Fig. 27). Moreover, Schleich *et al.* (1996) illustrated the hemipenes of *M.moilensis* which have high level of similarity with those of *M.m.insignitus*. This finding suggests that the hemipenis of the genus *Malpolon* is not proposed as taxonomical tool at species level. This conclusion was also found in the hemipenis of four species of the genus *Eirenis* (Shwayat, 1998).

## 5.6 The Digestive Tract

### 5.6.1 The Esophagus

The esophagus of *M.m.insignitus* resembles 50% of the snout-vent length as indicated by this study. The passage function of the esophagus may need the long distance. The proportions of the esophagus in juvenile and adult individuals are close to each other (Fig. 66). This is also may be referred to the passing function of the esophagus which doesn't need to be developed or increased in relative length through the adulthood.



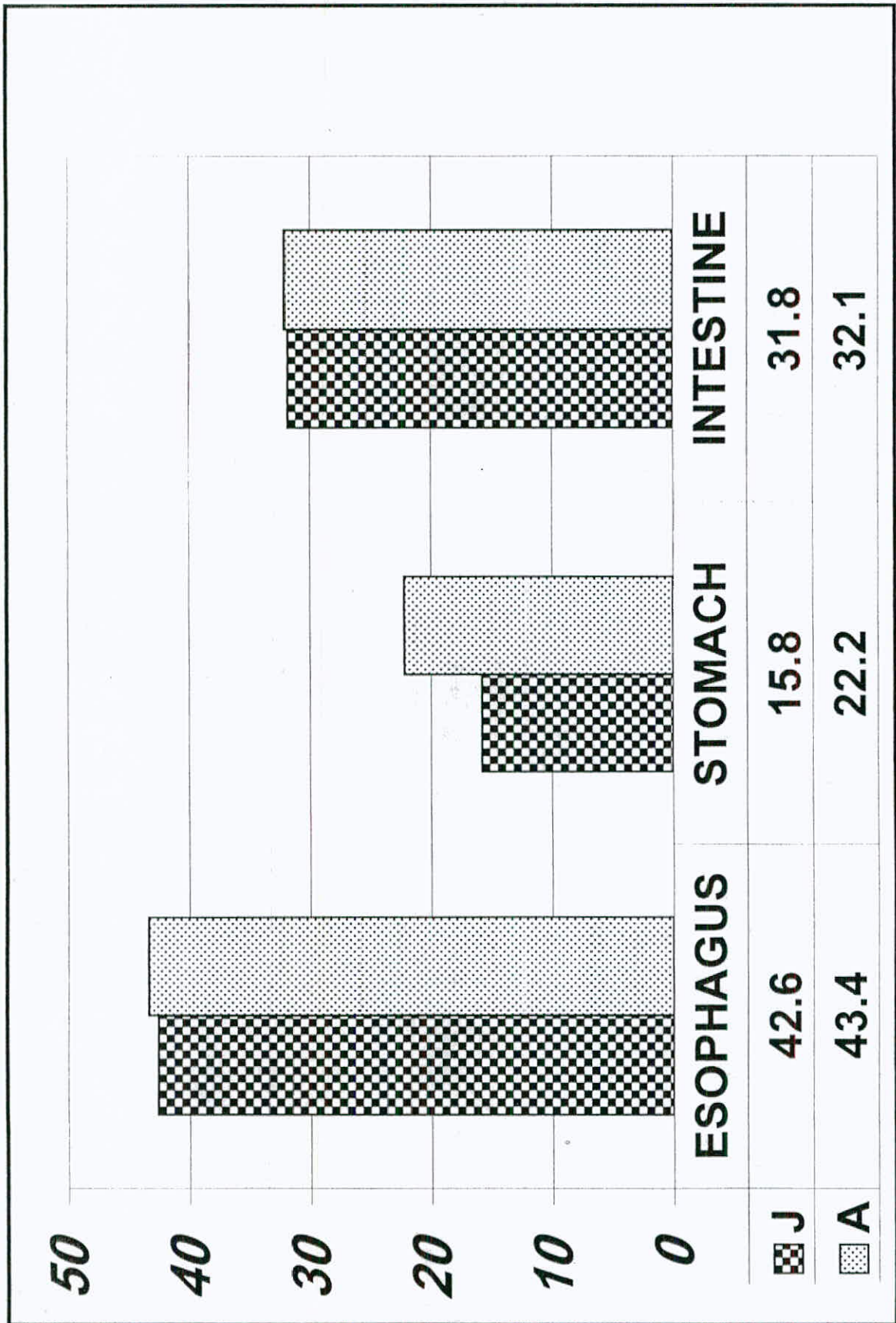


Fig. (66): The percentages of the digestive organs to the snout-vent length in the montpellier snake.



The lining of the esophageal lumen of the montpellier snake is found to be one cell thick and mixed layer, composed of two cell types: the goblet cells and the ciliated columnar cell (Table 5A). The presence of large number of goblet cells may help to smoothen the esophagus (the route of the prey). The presence of simple epithelial layer in the lining of the esophagus and the cilia is not expected in such organ, esophagus. Further investigations are needed to clarify the presence of such lining tissue. Also, an electron microscopic study is needed to ensure the structures of the cilia. The presence of simple columnar epithelial tissue and the cilia in the lining of the esophagus was also reported by Dehlawy and Zaher in the esophagus of the lizard *Acanthodactyllus* (1985a) and the gecko *Pristurus* (1985b). Chou (1977) mentioned that the mucous membrane of the gecko *Gehyra* was found to be lined by a single layer of columnar epithelial cells, while Bishai (1959) found that the mucosa of the lizard *Varanus* esophagus was formed of calcifirous, ciliated epithelium and goblet cells. Luppá (1977) stated that the epithelium was mainly two cells thick and contained variably distributed goblet cells and ciliated cell.

The nuclei of the mucosal cells are found to be laterally positioned in the montpellier snake. This finding supports the secretion function suggested for these cells (Fig. 33).

Table (5): the digestive organs mucosal structure and reaction with PAS and AB

• A: EPITHELIUM

The organ	Cell type	reaction with	
		PAS	AB
<b>Esophagus</b> 1 <sup>st</sup> and 2 <sup>nd</sup> .parts 3 <sup>rd</sup> . part	Simple (goblet & columnar)	(++&++)	(++&+)
	Simple columnar	++	--
<b>Stomach</b>  Cardiac  Fundic   Pyloric	Simple columnar	++	+
	Surface simple columnar	++	+
	Mucous glands	++	--
	Serous glands	--	--
	Surface simple columnar Mucous glands	+ +	+ +
<b>Intestine</b>  (small and large)	Simple (goblet & enterocytes)	(++&__)	++&__

++: highly +ve reactive; +: slightly +ve reactive

--: not reactive.

- B: LAMINA PROPRIA

The organ	Description of the layer
Esophagus	Very poor
Stomach	Well developed, contains the gastric glands
Intestine (small and large)	Well developed, contains lacteal and blood vessels

- C. MUSCULARIS MUCOSA

The organ	Description of the layer
Esophagus	
1 <sup>st</sup> and 2 <sup>nd</sup> Parts	3 layers thick of circular smooth muscles.
3 <sup>rd</sup> part	4 layers of smooth muscles and 4 layers of longitudinal smooth muscles.
Stomach	
Cardiac	Thin layer of circular smooth muscles.
Fundic	Very thick, two layers of smooth muscles (inner circular and outer longitudinal)
Pyloric	Well developed two layers of smooth muscles (circular and longitudinal)
Intestine (small and large)	Poorly developed



This investigation shows that the last part of the esophageal lumen of *M. m. insignitus* is lined only by columnar cells (Fig. 35), the same results were illustrated in the viper *Vipera palaestinae* (Frenkel and Kochva 1970), while it was found to be lined with goblet cells mainly in snakes as reported by Gianelli and Giacomini (1896). Moreover the esophagus of Cheloniidae was found to be lined by keratinized stratified squamous epithelium (Luppa, 1977). A stratified esophageal epithelium was present in the family Testudininae (Jeksajewa and Koloss, 1964 and Dilmuhamedov, 1975). The present study shows that the posterior part of the esophageal epithelium is made up of simple columnar cells.

This study has shown that the montpellier snake lacks any kind of esophageal glands. This may be referred to the passing function of the esophagus and not the digestion. The passage function requires the presence of goblet cells for the lubrication. The same results were documented by Frenkel and Kochva (1970) in the *Vipera palaestinae*, by Bishai (1959) in the lizard *Varanus*, by Dehlawy and Zaher (1985a&b) in the gecko *Pristurus* and the lizard *Acanthodactylus*. On the other hand, the esophageal glands were recorded in turtles by Gabe (1971). Oppel (1900) pointed out the presence of the esophageal glands in number of species, emphasizing

that there was no relation between the presence of the esophageal glands and the systematic position of the organism. Also the same author reported them in *Alligator*, while they were absent in *Crocodylus*.

The reaction of the esophageal epithelium with both PAS and AB is positive. Such results indicate the storage and thence the secretion of the neutral and acid mucopolysaccharides (PAS and AB respectively) from montpellier snake esophagus (Table 5A). The acidic mucopolysaccharides are localized in the goblet cells giving blue color with AB stain (Fig. 36). Both types of mucine are important for lubrication of the esophagus for easier passage of the prey.

The muscularis mucosa of *M.m.insignitus* esophagus is present and developed (Table 5C), which suggests a valid role of this layer to squeeze out the mucus contained in the epithelial secretory cells (Figs. 31&35).

The esophageal submucosa of the montpellier snake consists of loose connective tissue and contains blood vessels. This is assured by the reaction of VG (red) and FG (blue) (Figs. 37&38). The

submucosa of the lizard *Varanus* was found to be well developed (Bishai, 1959 ). Moreover, Chou (1977) found the submucosa of the gecko *Gehyra* consists of connective tissue and rich in blood vessels. The presence of the elastic fibers was also recorded in turtles by Beguin (1904) in addition to the collagen fibers. Luppá (1977) reported capillaries as well as large blood vessels in the submucosa of reptiles. The esophageal submucosa of the montpellier snake is found along the esophagus, while it was found to be present in the posterior part of other reptilian esophagus but was absent in the turtles (Gianelli and Giacomini, 1906).

This study has revealed that the muscularis externa of *M.m.insignitus* has different structures in different regions, that the most anterior part of the esophagus is composed of two layers of skeletal muscles (Fig. 32), which is expected for the voluntary swallowing process. The presence of smooth muscles in the other parts of the esophagus (Fig. 38), is needed for the peristaltic movement. Gegenbaur (1901) reported that the tunica muscularis consisted of two layers of smooth muscle fibers: inner circular and outer longitudinal. Bishai (1959) found that the muscularis externa of the lizard *Varanus* started as a single continuous circular muscle, but the outer longitudinal layer started as weak patches posteriorly. The



esophageal muscularis externa of the gecko *Gehyra* was found to be consisted of inner circular and outer longitudinal smooth muscles (Chou, 1977).

### 5.6.2 The Stomach

The present investigation clarifies that the stomach doesn't exceed 18% of the snout-vent length. On the other hand, the stomach is observed to have the strongest and thickest wall among the digestive organs (Fig. 30). The strong muscular wall is needed for mechanical digestion and breaking down the large preys. When comparing between the proportions of the stomach in the juveniles and the adults (Fig. 66), the latter is found to have higher value. This may result from the larger preys that adults eat, which means larger amount of acid and digestive enzymes are needed for digestion.

The obtained results suggest that the stomach of the montpellier snake can be distinguished into three regions: cardiac, fundic and pyloric. Similar situation was found in the stomach of the lizard *Varanus* (Bishai, 1959). The snake *Xenodon merremii* had a stomach with two regions (Ferri *et al*, 1974). However, two regions were defined in the stomach of the lizard *Acanthdactylus* and the

gecko *Pristurus*, the fundus and the pylorus (Dehlawy and Zaher, 1985a&b). In addition, Lupp (1977) stated that the reptilian stomach always contains two delimited regions: the corpus and the pylorus.

The gastric glands of the montpellier snake are totally absent in the cardiac region (Fig. 39), mostly abundant in the fundus and also found in the pylorus. The pyloric glands have a lesser degree of branching level than the fundic ones (Figs. 42, 46&47). A comparison made between the two types of gastric glands in the snake *Xenodon*, revealed the same results (Ferri, 1974). Similar observations were also made in the gecko *Pristurus* and the lizard *Acanthodactylus* (Dehlawy and Zaher, 1985a&b). The gastric glands of the studied species are surrounded by fibrous connective tissue which is highly vascularized, which may be important to supply the gland cells with the needed raw materials to synthesize the gastric juice (Fig. 48). Moreover, Opper (1896) found the same connective tissue between the gastric glands in the turtle *Caretta*. Also, Dehlawy and Zaher (1985b) found the gastric glands of the gecko *Pristurus* to be separated by areolar connective tissue.

The gastric glands of *M.m.insignitus* are found to be two types: the mucous clear glands and the serous dark glands (Fig. 42).

The clear glands are positively reacted with PAS, while the dark do not (Fig. 49) and (Table 5A). The dark cells were previously termed as cells of chief by Luppa (1961). Bishai (1959) found the two types of glands in the cardiac and the fundic regions, while the pyloric region contained only the clear type of gland cells. However, Dehlawy and Zaher (1985) found that the gastric glands in the fundus were of granular dark type, while the pyloric glands were of the clear type. Also, Gabe and Saint Gerons (1972) reported the presence of only the dark serous glands. They classified the fundic glands into three types, the colubrid snakes had got the second one in which there were specialized neck cells and only the dark serous cells were found in the fundic region.

The muscularis mucosa is thick and well developed *M.m.insignitus* as documented by this study (Fig. 42) and (Table 5B). The presence of such characterized layer beneath the gastric glands may explain the valid role of such layer in the gastric gland secretion.

This study has revealed that the muscularis externa of the montpellier snake stomach is the thickest among other digestive organs. The thick muscularis externa may resulted to adapt the prolonged period of time that the food persists there. Another function



may be achieved by the thick gastric muscularis externa: its role in the mechanical digestion and proper mixing. The variation in the thickness of muscularis externa is not well noticed between the different gastric regions. Luppa (1977) also found that the tunica muscularis of the stomach consisted of two smooth muscle layers, but he reported less thickness in the pars pylorica than in the corpus. Bishai (1959) pointed out that the muscularis externa of the lizard *Varanus* stomach was mainly composed of circular smooth muscle layer, while the longitudinal layer developed at the level of the pylorus. The muscularis externa of the stomach in the gecko *Gehyra* was found to consist of thick inner circular and thin outer longitudinal smooth muscle layers (Chou, 1977).

### 5.6.3 The Small Intestin

The intestine of the montpellier snake is found to occupy 32.1% of the snout-vent length (Fig. 66), which is larger than the stomach value but still smaller than the esophageal one. This value is slightly higher in the adult individuals than in the juveniles. The relatively long intestine with convoluted pattern is needed to offer larger surface area of absorption. The need for the absorption surface area is increased in the adult specimens because of the larger preys they ingest.

The simple columnar epithelial cells lining the small intestine of *M.m.insignitus* are shown through this investigation (Table 5A). Other studies concerning *Natrix*, *Lacerta* and *Agama* also revealed the simple epithelium, while the stratified epithelium was found in turtles and crocodiles as stated by Luppa (1977).

The epithelial layer of the small intestine of the montpellier snake consists of two types of cells, the dominant type is the simple columnar and the other is the goblet cells which are placed randomly between the columnar ones (Figs. 53). Paneth cells are not found in the montpellier snake. On the other hand, previous investigations reported the presence of different types of cells in the intestinal mucosa: marginal, goblet, Paneth and enterochromaffin cells (Luppa, 1977), absorptive, goblet and paneth cells (Dehlawy and Zaher, 1985), stratified columnar epithelium and goblet cells (Bishai, 1959) and short columnar epithelium (Chou, 1977).

The intestinal mucosa of the montpellier snake is positively reactive with AB and PAS stains (Table 5A), which indicates the presence of only acid mucopolysaccharides contained in the goblet

cells. The intestinal columnar epithelium doesn't contain any type of mucin which emphasized the absorptive function of this tissue (Fig. 59).

The present study reports the reduction in the muscularis mucosa especially in the middle part of the small intestine (Table 5B), which is also characterized by being rich in blood supply and in lacteal (Figs. 56&57). The previous mentioned features emphasize the probable suggested absorptive function of this region. The poor developed intestinal muscularis mucosa was also reported in the duodenum of the common garter snake *Thamnophis sirtalis* (Reis and Lyons, 1943). The absence of the intestinal muscularis mucosa was reported in the lizard *Varanus* (Bishai, 1959).

The small intestine of the montpellier snake is devoid of any kinds of glands (Fig. 53). Moreover, the absence of the intestinal glands was noticed also in other snakes as reported by Vialli (1929), the gecko (Chou, 1977). The lack of the intestinal glands may be referred to the absorptive function of the small intestine rather than the digestive one.



The two layers of the intestinal smooth muscles of the montpellier snake are well developed. However, Bishai (1959) mentioned that the intestinal muscularis externa was weakly developed in the lizard *Varanus*, while Chou (1977) noticed a thick internal muscularis externa of the gecko *Gehyra*

#### 5.6.4 The Large Intestine

The present study shows that the montpellier snake is composed of simple low columnar cells and goblet cells which are scattered randomly. The columnar epithelium may be present for water absorption but not for mucin secretion since it doesn't react positively with neither PAS nor AB. The goblet cells contribute to lubricate the route of the faeces which is supported by its reaction with PAS and AB stains (Fig. 62). Bishai (1959) reported the same kind of the mucosa with absorptive function in the large intestine of the lizard *Varanus*. The absorptive columnar epithelium with few goblet cells were recorded in the gecko *Pristurus* (Dehlawy and Zaher, 1985), while the two authors recorded tall columnar epithelium in the lizard *Acanthodactylus*.

#### 5.6.5 The Cloaca

The cloacal mucosa of *M.m.insignitus* is composed of stratified squamous epithelium (Fig. 63). The stratified structure is

needed for the rapid replacement of the mucosal layer after friction with the stools. The muscularis externa is composed of skeletal muscle (Fig. 64), which is a must for the voluntary contraction needed to regulate the passage of stools, urine and eggs in female. The skeletal muscles, which are stained green with FG, follow well developed layers of fibers that may help in stretching the wall of the cloaca to push out the excreted materials.

### 5.7 The Duvernoy's Gland

Duvernoy's gland of *M.m.insignitus* is found to start from the region under the eye corner (Fig. 65). It extends posteriorly with enlargement and then retains its narrow end above the mouth corner. Similar finding was illustrated by Kochva and Gans (1970) in *M.monspessulanus*.

This investigation has shown that the main venom gland ; the Duvernoy's gland of the montpellier snake is not covered by any muscular tissue. On other hand, the viprid venom gland was reported to be covered with the muscle compressor glandulae (Dullemeijer, 1958 and Kochva, 1958 and 1962). Furthermore, this study reveals that the muscle adductor mandibulae externus superficialis is responsible for Duvernoy's gland squeezing in *M.m.insignitus*. On

the contrary, the venom secretion of the viprid snakes was found to be carried out by the muscle compressor glandulae with the participation of the muscle adductor mandibulae externus superficialis (Dullemeijer, 1958 and Kochva, 1958 and 1962).



**6**

**REFERENCES**

Abu- Laban, N. 1999. *The Ecology of Some Rodents in the Azraq Wet Land Reserve, with A Special Reference to Some Abundant*. Master Thesis. The University of Jordan. Jordan. 182 PP.

Amer, M.A., Zaher, M.M and Dehlawy, G.Y. 1987. Histochemistry of the Alimentary Canal Mucosa of *Echis carinatus* (Reptilia, Viperidae). *Egypt.J.Histol.*, **10(2)**: 229-238.

Amer, M.A.,Zaher, M.M., Dehlawy, G.Y. and Abo-Taira, A.M. 1987. Distribution of Lipids and Mucopolysaccharides in Alimentary Tract Mucosa of the Gecko *Tarentola annularis*. *Proc. Eygpt. Acad. Sci.*, **37**:137-144.

Amr, Z., El- Oran, R. and Disi, A. 1994. Reptiles of Southern Jordan. *The Snake*, **26**: 41-49.

Beguin, F. 1904. La muqueuse oesophagienne et ses glandes chez les reptiles. *Anat. Anz.*, **24**: 337-356.

Bergman, R. A. M. 1951. The Anatomy of *Natrix vittata*. *Zool. Meded.*, **31**:13-24.

Bergman, R.A.M. 1965. The anatomy of *Calamaria multipunctata* (Boie). *Bull. Nat. Mus. Singapore*, 7:35-56.

Betz, T. W. 1963. The Gross Ovarian Morphology of the Diamond Back Water Snake *Natrix rhombifera*, During the Reproductive Cycle. *Copeia*, 1963 (4): 692-697.

Bishai, H.M. 1959. The Anatomy and Histology of the Alimentary Tract of the Lizard *Varanus griseus* daud. *Bull. Fac. Sci. cairo Univ.*, 35:53-73.

Boltt, R.E and Ewer, R.F. 1964. The Functional Anatomy of the Head of the Puff Adder, *Bitis arietans* (Merr). *J.Morph.*, 114: 83-106.

Boulenger, G.A. 1893. Catalogue of Snakes in the British Museum. Vol. I. London.

Bragcon, D.E. 1953. A Contribution to the Surgical Anatomy of the Water Snake *Natrix sipedon sipedon*; the Location of the Visceral Endocrine Organs with Reference to Ventral Scutellation. *Anat. Rec.*, 117:145-161.



Branch, W. R. 1986. Hemipeneal Morphology of the African Snakes: A Taxonomic Review Part 1. Scolecophidia and Boide. *J. Herpetol.*, **20(3)**: 285-299.

Chou, L.M. 1977. Anatomy, Histology and Histochemistry of the Alimentary Canal of *Gehyra mutilata* (Reptilia, Lacertilia, Gekkolidae). *J. Herpetol.*, **11(3)**: 349-357.

Cielak, E. S. 1945. Relations Between the Reproductive Cycle and the Pituitary Gland in the Snake *Thamnophis radix*. *Physiol. Zool.*, **18**: 299-329.

Clark, D. R. 1970. Loss of the Left Oviduct in the Colubrid Snake Genes *Tantilla*. *Herpetologica*, **26**: 130-133.

Clark, G. 1981. Staining Procedure. Fourth Ed. Waverly Press, Inc. U.S.A. 512 pp.

Cope, E. D. 1898. The Crocodilians, lizards and Snakes in North America. *Rep. U.S. National Museum*, **1890**: 155-1270.

- Cundall, D. 1981. Cranial Osteology of the Colubrid Snake Genus *Opheodrys*. *Copeia*, **2** : 353-371.
- Cundall, D. 1983. Activity of Head Muscles During Feeding By Snakes: A Comparative Study. *Am. Zool.*, **23**: 383-396.
- Cundall, D. 1986. Variations of the Cephalic Muscles in the Colubrid Snake Genera *Entechinus*, *Opheodrys* and *Symphimus*. *J. Morph.*, **187**: 1-21.
- Cundall, D. and Rossman, D.A. 1984. Quantitative Comparisons of Skull Form in the Colubrid Snake Genera *Farancia* and *Pseudoeryx*. *Herpetologica*, **40(4)**: 388-405.
- Das, S. M. 1960. A Comparative Function Study of the Urino-Genital System in *Uromastyx hardwickii* Gray (Sand Lizard), *Ptyas mucosus* (Rat Snake) and *Eryx conicus* (Sand Boa). *Proc. natn. Acad.. Sci. Lond.*, **30**: 59-78.
- Dehlawy, G.Y. and Zaher, M.M. 1985a. Histological Studies on the Muscosal Epithelium of the Alimentary Canal of the Lizard

*Acanthodactylus boskianus* (Family Lacertidae). *Proc. Zool. Soc. A.R. Egypt*, **9**: 67-90.

Dehlawy, G.Y. and Zaher, M.M. 1985b. Histological Studies on the Muscosal Epithelium of the Alimentary Canal of the Gecko *Pristurus rupestris* (Family Geckonidae). *Proc. Zool. Soc. A.R. Egypt*, **9**:91-112

Dehlawy, G.Y. and Zaher, M.M. and Amer, M.A. 1987. A Histological Study of Carbohydrates in the Mucosal Epithelium of the Alimentary Canal of Gecko, *Pristurus purestris*. *Bull. Fac. Sci., Assiut Univ.*, **16(1)**:37-46.

Dehlawy, G.Y. and Zaher, M.M. and Amer, M.A. 1988a. Histochemistry of the Mucosal Epithelium of the Alimentary Canal of Lizard *Acanthodactylus boskianus* . *Bull. Fac. Sci., Cairo Univ.*, **56**:129-143.

Dehlawy, G.Y. and Zaher, M.M. Amer, M.A. and Abo-Taira, A.M. 1988b. Histochemical Localization of Carbohydrates in the Mucosal Epithelium of the Alimentary Canal of Agamid Lizard *Uromastyx philbyi* . *Proc. Egypt Acad. Sci.*, **37**: 155-164.



Disi, A. 1985. A Contribution to the Herpetofauna of Jordan. 2. New Record and Systematic List of Snakes from Jordan. *The Snake*, **17**: 31-42.

Dilmuhamedov, M. E. 1975. The Comparative Morphology of the Digestive Tract of Some Reptiles. *Dissertation, Alma-Ata*.

Dullemeijer, P. 1956. The Functional Morphology of the Head of the Common Viper, *Vipera berus* (L.). *Arch. Neerl. de Zoologie*, **4**: 386-497.

Dullemeijer, P. 1958. A Comparative Functional Anatomical Study of the Heads of Some Viperidae. *Morph. Jb.*, **99**:881-985.

El-Oran, R., Al-Melhem, W.N. and Amr, Z.S. 1994. Snakes of Southern Jordan. *Boll. Zool.*, **61**: 359-367.

Ferri, S., Medeiros, L.O and Stipp, A.C. 1974. Gastric Wall Histological Analysis and Cellular Types Distribution in *Xenodon merremii* Wagler, 1824 (Ophidia). *Gegenbaurs Morph. Jahrb., Leipzig*, **5**: 627-637.

Fox, W. 1965. A Comparison of the Male Urogenital Systems of Blind Snakes, Leptotyphlopidae and Typhlopidae. *Herpetologica*, **21(4)**: 241-256.

Fox, W. 1956. Seminal Receptacles of Snakes. *Anat. Rec.*, **124**: 519-530.

Frenkel, G. and Kochva, E. 1970. Visceral Anatomy of *Vipera Palaestinae* : An Illustrated Presentation. *Is. J. Zool.*, **19(3)**: 145-163.

Gabe, M. 1971. Repartition des cellules histaminergiques dans la parvis gastrique de quelques reptiles. *C. R. Acad. Sci., Paris*, **273**: 2287-2289.

Gabe, M. and Saint Girons, H. 1972. Contribution a' l'histologie de l'estomac des lepidosauriens (Reptiles). *Zool. Jb.*, **89**: 579-599.

Gadow, H. 1912. The One-Sided Reduction of the Ovaries and Oviducts in the Amniota with Remarks on the Mammalian Evolution. *Proc. Zool. Soc. Lond.*, **1912**: 808-821.

Gasperetti, G. 1988. Snakes of Arabia. Fauna of Saudi Arabia, 9: 169-392.

Gegenbaur, C. 1901. "Vergleichende Anatomie der Wirbeltier mit Berücksichtigung der Wirbellosen" Vol. 11. Wilhelm von Engelmann, Leipzig. pp. 1-215.

Gianilli, J. and Giacomini, E. 1896. Ricerche istologiche sul tubo digerente dei Rettili. *Atti. Accad. Fisiocr. Siena*, 4: 11-38.

Haas, G. 1952. The Head Muscles of the Genus *Causus* (Ophidia, Solenoglypha) and Some Remarks on the Origin of the Solenoglypha. *Proc. Zool. Soc. London.*, 122:573-592.

Haas, G. 1973. Muscles of the Jaws and Associated Structure in the Rhynchocephalia and Squamata, 285-483. In: Gans, C. and Parson, T.S.(ed.): *Biology of the Reptilia*, vol. 4. Academic Press, Inc. London.

Haas, G. and Werner, Y.L. 1969. Lizards and Snakes from Southwestern Asia, Collected by Henry Field. *Bull. Mus. Comp. Zool. Harv.*, 136: 327-374.



Haines, T.P. 1967. Variations of Colubrid Skulls, their Correlations and their Value in Taxonomy. *Herpetologica*, **23**: 142-145.

Hoffstetter, R. 1939. Sur l'articulation occipito-vertébrale des Uropeltidae (Ophidiens fouisseurs). *Bull. Mus. Nat., Paris (2)*, **11 (5)**: 426-433.

Hofstetter, R. and Gasc, J. 1969. Vertebrae and Ribs of Modern Reptiles, 201-310. In: Gasc, C. (ed.), *Biology of the Reptilia*. Vol. 1. Academic Press, London and New York.

Hoffstetter, R. and Gayraud, Y. 1964. Observations sur l'ostéologie et la classification des Acrochordidae (Serpentes). *Bull. Mus. Natn. Hist. nat., Paris (2)*, **36 (5)**: 677-696.

Hroui Bloquet, S. 1982. Les Reptiles du Liban. 1) Nomenclature et Note Ecologique. *Ecologia Mediterranea*, **7**: 93-101.

Jacobshagen,, E. 1920. Zur Morphologie des Oberflächenreliefs der Rumpfdarmschleimhaut der Reptilien. *Jena. Z. Naturw.*, **56**: 361-430.

Jeksajew, V. and Koloss, E. 1964. Histological Observations on the Epithelial Lining of the Esophagus in Vertebrate Animals. *Izu. Akad. Nauk. SSSR, Ser. Biol.*, **1964**: 388-395. (English Abstract).

Kochva, E.T. 1958. The head muscles of *Vipera Palaestinae* and their Relation to the Venom Gland. *J.Morph.*, **102**:23-54.

Kochva, E.T. 1962. On the Lateral Jaw Musculature of the Solenoglypha With Remarks On Some Other Snakes. *J.Morph.*, **110(2)**: 227-284.

Kochva, E. 1963. Development of the Venom Gland and Trigeminal Muscle in *Vipera palaestinae*. *Acta anat.*, **52**:49-89.

Kochva, E.T. 1965. The Development of the Venom Gland in the Opisthoglyph Snake *Telescopus fallax* with Remarks on *Thamnophis sirtalis* (Colubridae, Reptilia). *Copeia*, **2**: 147-154.

Kochva, E.T. And Gans, C. 1965. The Venom Gland of *Vipera palaestinae* With Comments On the Glands of Some Other Viperines. *Acta anat.*, **62**: 365-401.

Kochva, E. and Gans, C. 1967. The Structure of the Venom Gland and Secretion of Venom in Viprid Snakes. *Animal Toxins, The First International Symposium on Animal Toxins*. 195-203

Kochva, E.T. and Wollberg, M. 1970. The Salivary Glands of Aparallactinae (Colubride) and the Venom Glands of *Elaps* (Elapidae) in Relation to the Taxonomic Status of this Genus. *Zool. J. Linn. Soci.*, **49 (3)**: 217-224.

Leviton, A. and Alderich, M. 1984. Introduction and Checklist of the Arabian Herpetofauna. Soc. For the Study of Amphibia and Reptiles.

Leydig, F. 1857. "Traité d'histologie de l'Homme et des Animaux". Transl. From German by R. Lahillonne (1866). *Germer, Baillier, Paris*.

Luppa, H. 1961. Histologie, Histogenese und Topochemie der Drüsen des Sauropsidenmagens. I. *Reptilia. Acta.histochem.*,**12**: 137-187.

Luppa, H. 1977. Histology of the Digestive tract, 235-313. In: Gans, C. and parsons, T.S (ed.). *Biology of the Reptilia*, Vol. 6. Academic Press, Inc.London.



Marshall, A. 1962. Parker and Haswell- A Textbook of Zoology. Seventh Ed. Macmillan & Co. London.

Marx, H. 1968. Checklist of the Reptiles and Amphibians of Egypt. U.S.N.M. Res. Unit. No. 3 (NUMRU-3), Cairo, Egypt.

Mohammed, M.B.H. 1991. The Skeletal Anatomy of *Eryx jayakari* (Boidae, Reptila). *J. Egypt. Ger. Soc. Zool.*, **6b**: 393-409.

Nakar, O, Ovadia, M. and Kochva, E. 1986. Isolation of a Proteolytic Factor from the Venom of *Vipera palaestinae*. *Toxicon*, **24 (3)**: 293-304.

Oppel, A. 1896 and 1900. "Lehrbuch der vergleichenden mikroskopischen Anatomie der Wirbeltiere" vols. 1, 2, 3. *Gustev Fischer, Jerna*.

Parsons, T.S. and Cameron, J.E. 1977. Internal Relief of the Digestive Tract, 159-225. In: Gans, C. and parson, T.S (ed.). *Biology of the Reptilia*, Vol. 6. Academic Press, Inc. London.

Peacock, P and Brdbury, S. 1973. Peacocks Elementary Microtechnique. Fourth Ed. Edward Arnold Ltd. Great Britain.

Reed, C. and Marx, H. 1959. A Herpetological Collection From Northeastern Iraq. *Trans. Kansas Acad. Sci.*, **62 (1)**: 91-122.

Reis, R.H. and Lyons, W. 1943. Histology of the Small and Large Intestine of the Common Green Snake, *Thamnophis sirtalis*. I. Duodenum. *Wasmann collect.*, **5(3)**: 81-88.

Robb, J. 1960. The Internal Anatomy of *Typhlops* Schneider (Reptilia). *Aust. J. Zool.*, **8**: 181-216.

Robb, J. and Smith, H. M. 1966. The Systematic Position of the Group of Snake Genera Allied to *Anomalepis*. *Nat. Hist. Misc.*, **184**: 1-8.

Romer, A.S. 1976. Osteology of the Reptiles. Third Ed. The University of Chicago Press. USA.

Rosenberg, H., Kinamon, S., Kochva, E. and Bdollah, A. 1992. The Secretion of Duvernoy's Gland of *Malpolon monspessulanus* Induces Haemorrhage Change in the Lungs of Mice. *Toxicon*, **30 (8)**: 920-924.

Rosenberg, H., Bdollah, A. and Kochva, E. 1986. Duvernoy's Gland in Colubrid Snakes. *Studies in Herpetology, Proc. Europ. Herpeto.Meeting*. PP: 641-644.

Saint Ange, G. I. M.1856. Etude de l'appariel reproducteur dans les cinq classes d'animaux vertebres. *Mem. Acad. Sci. Inst. Fr.*, **14**: 1-232.

Schatti, B. 1987. The Phylogenetic Significance of Morphological Characters in the Holarctic Racers of the Genus *Coluber* linnaeus, 1758 (Reptilia, Serpentes). *Amphibia- Reptilia*, **8**: 401-418.

Schatti, B. 1988. Systematics and Phylogenetic Relationships of *Coluber florulentus* Geoffroy 1827 (Reptilia, serpentes). *Trop. Zoo.*, **1**: 95-116.

Shleich, H.H., Kastle,W. and Kabisch, K. 1996. Amphibians and Reptiles of the North Africa. Koeltz Scientific Books, Germany.

Shwayat, S.N. 1998. *Systematics and Distribution of Snakes (Genus Eirenis) in Jordan*. Master thesis. University of Jordan. Jordan. 139 PP.



Shwayat, S.N. 1998. *Systematics and Distribution of Snakes (Genus Eirenis) in Jordan*. Master thesis. University of Jordan. Jordan. 139 PP.

Sivan, N. and Werner, L. 1992. Survey of the Reptiles of the Golan Plateau and Mt. Hermon, *Israel. Is. J. Zool.*, **37**: 193-211.

Taib, N.T. and Jarrar, B.M. 1995 . Fundamentals of Histochemistry King Saud Univ. Publication. (in Arabic).

Taka'cs, Z. 1986. Venom Discharge Mechanism in *Malpolon monspessulanus* and *Vipera ammodytes*. *Studies in Herpetology, Proc. Europ. Herpeto. Meeting*. PP.: 349-352.

Underwood, G. 1967. A Contribution to the Classification of the Snakes. *Monogr. Brit. Mus. Nat. Hist. Lond.*, 653:1-179.

Underwood, G. 1992. A Systematic Analysis of Boid Snakes. *Morph, Biol. Rept.*, **3**: 151-175.

Underwood, G. and Kochva, E.T. 1993. On The Affinities of the Borrowing Asps *Atractaspis* (Serpentes: Atractaspididae). *Zool. J. Linn. Soc.*, **107**: 3-64.

Vialli, M. 1929. Ricerche sull' intestino dei Rettili. 1. Il tratto ileociecocolico. *Arch.ital. anat.*, **26**: 454-492.

Weichert, C. K. 1970. The Anatomy of the Chordates. McGraw-Hill Inc. London

Woerkom, V. 1982. The Snakes of the Genus *Malpolon*. *Literature Serpantium*, **2 (4)**: 126-179.

Young, J. 1962. The Life of the Vertebrates. Second Ed. Clarendon Press, Oxford.

Zaher, M.M. Al-Lail, S.J and Dehlawy, G.Y. 1987. Anatomical and Histological Studies On the Alimentary Tract of the Lacertid Lizard *Acanthodactylus opheodreus* (Family Lacertidae). *Egypt. J. Histol.*, **10(2)**: 207-221.

**7**

**APPENDIX**



## A. PREPARATION OF FIXATIVES

## ◀ 1. Formalin (10%)

Formalin 40%	100ml
Sodium monophosphate	4g
Sodium diphosphate	6.5g
Distilled water	900ml

## ◀ 2. Zenker's Solution

Mercuric chloride	50g
Potassium dicromate	25g
Sodium sulfate	10g
Glacial acetic acid	50ml
Distilled water	950ml

## B. PREPARATION OF STAINING SOLUTIONS

### ◀ 1. Acid Fuchsin Solution

Acid fuchsin	0.2g
Saturated aqueous picric acid (about 1.22%)	100ml

### ◀ 2. Alcian Blue (pH=1.0)

Alcian blue	1g
Hydrochloric acid 0.1M	100ml

### ◀ 3. Alcian Blue (pH=2.5)

Alcian blue	1g
Glacial acetic acid (3%)	100ml

### ◀ 4. Ainline Blue

Aniline blue	0.5g
Oranange G	2g
Oxalic acid	2g
Distilled water	100ml

## ◀ 5. Eosin-Y

Eosin	1g
Phloxin B	10ml
95% Ethanol	780ml
Glacial acetic acid	4ml
Distilled water	100ml

## ◀ 6. Fast Green

Fast green	0.1g
Acetic acid 1%	100ml

## ◀ 7. Harris Hematoxylin

Hematoxylin 10%	10ml
(in absolute ethanol)	
Mercuric oxide	0.5g
Potash alum (10%)	200ml
Glacial acetic acid	4ml



### ◀ 8. Iron Hematoxylin

#### Solution (A)

Hematoxylin 10%	100ml
in absolute ethanol	

#### Solution (B)

Ferric chloride 30%	4ml
Hydrochloric acid 1M	1ml
Distilled water	95%

### ◀ 9. Mayer's Hematoxylin

Hematoxylin	1g
Aluminium potassium sulfate	50g
Chloral hydrate	50g
Sodium iodate	0.2g
Citric acid	1g
Distilled water	1000ml

### ◀ 10. Schiff's Reagent

Basic fuchsin	1g
Sodium meta-bisulfate	1.9g
Hydrochloric acid	15ml
Distilled water	85ml

## ◀ 11. Van Gieson's Solution

Acid fuchsin	0.1g
Saturated aqueous picric acid	100ml
(about 1.22%)	

## الملخص

دراسة مظهرية و تشريحية لبعض الأجهزة في الثعبان الخضاري *Malpolon monspessulanus insignitus* من عائلة الثعابين الاصيلية (Colubridae)

اعداد

شفاء عبد الحميد عواد

باشراف

د. احمد الديسي

تناول الدراسة الحالية وبشيء من التفصيل تشريحا لبعض الأجهزة والأعضاء للثعبان الخضاري من عائلة الثعابين الاصيلية، والذي ينتشر بشكل ملحوظ في المناطق الخضراء في الأردن. هذا بالاضافة الى دراسة نسيجية تخصيصية للقناة الهضمية. يتميز الثعبان الخضاري بامتلاكه جسما اسطوانيا طويلا يصل الى 179 سم ضمن العينات المدروسة. يعرف هذا الثعبان بلونه الرمادي الضارب الى الخضرة على الجانب الظهرى والذي يخف تدريجيا باتجاه الذيل ويحمل في منتصفه 19 حرشفة ارينية. اما الجانب البطنى فهو اصفر اللون يتخلله لون وردى في المنطقة الوسطية للجانب البطنى، يغطى هذا الجانب 156-179 حرشفة مستعرضة. ومن الجدير بالذكر ان راس الثعبان الخضاري يتخذ شكل مثلث متساوى الساقين، ذى قاعدة عريضة وساقين طويلتين. يمكن تمييز راس الثعبان عن رقبتة، فهو لا يتخذ وضعا انسيابيا مع بقية الجسد. يحمل الثعبان عينين كبيرتين على جانبي راسه.

تعاملت هذه الدراسة في جزء منها مع التركيب التشريحي لكل من الجمجمة، عضلات الراس و فقرات العمود الفقرى. عند مقارنة النتائج الحالية بنتائج سابقة، وجد ان جمجمة الثعبان الخضاري تحتفظ بالسماوات العامة لجمجمة عائلة الثعابين الاصيلية من حيث كونها مبنية من عظام صلبة متماسكة. اما عضلات الراس فهي مرتبطة بعظامه بشكل قوى و متماسك مما يؤهلها لأداء مهمتها بتحريك العظام اثناء سحب الفريسة بقوة و ثبات. من خلال هذه الدراسة ثبت ان مجموعة العضلات المقربة الخارجية الموجودة متقدمة ومميزة، ولكن وجد ان كل من العضلة الزاوية الحديدية والعضلة الغدية الضاغطة واللذان تنتميان لهذه المجموعة مفقودتان في الثعبان الخضاري. اما عند النظر الى الفقرات الظهرية بتمعن، فقد لوحظ تباينا واضحا في شكلها و حجمها ضمن الثلاث مناطق المدروسة ( اول ثلاث فقرات، الجذعية و المدرقية).

لقد تم ايلاء دراسة القناة الهضمية تشريحا ونسيجيا اهتماما واضحا في هذا لبحث. ان استتالة جسم الثعبان خارجيا تعكس ترتيب احشائه الداخلى، فقد وجد ان الاعضاء الهضمية قد



استطالت وترتبت لتتلاءم مع جسم هذا الكائن. لقد احتل المرء النسبة الأكبر في طول المسافة بين الأنف و المدرق مقارنة ببقية الاعضاء الهضمية. و قد بينت هذه الدراسة تغيرا في طبيعة الطبقة المبطنة على طول القناة الهضمية. فهناك النسيج الطلائى البسيط الذى يجمع بين نوعين من الخلايا فى المرء والأمعاء، و هناك النسيج العمادى البسيط الذى يميز بطانة المعدة. و باستخدام صبغتي شيف-حمض البيريوديك و ازرق الألسيان فقد تبين انتشار عديد السكريات المتعادل و الحامضى على طول الانبوب الهضمى، مع ملاحظة تركيز الأخير فى المرء. كذلك الأمر بالنسبة للطبقة تحت المخاطية، فقد لوحظت فى الأعضاء الهضمية المختلفة. تميز جدار المعدة فى الشعبان الخضارى باحتوائه طبقة عضلية خارجية غنية و سميكة بالنظر الى غيرها من الاعضاء. ولم يكن الحلل كذلك فى الطبقة المصلية، فلم يسجل وجودها قبل الثلث الأخير من المرء.

بالإضافة الى ما سبق ذكره، فقد عنيت هذه الدراسة ايضا بتناول الجهازين الذكري و الأنثوى من الناحية التشريحية. وقد تم ملاحظة اتخاذ الاعضاء التناسلية على الجهة اليمنى موضعا اماميا بالنسبة الى اليسرى فى كلا الجنسين. كما وجد ان الاعضاء الذكرية و الأنثوية اليمنى اكبر حجما من اليسرى. و فى محاولة لدراسة مظهرية لشبه القضيب فى تحت النوع *M.m.insignitus*، و بمقارنته مع ما اورد سابقا عن النوع *M.moilensis* فقد لوحظ عدم وجود اختلاف بين النوعين مما يرجح عدم الاستفادة من شكل شبه القضيب فى اغراض تصنيفية على مستوى النوع لهذا الجنس. لقد تضمن هذا البحث ايضا وصفا للغدة السمية الرئيسة للشعبان الخضارى، غدة دوفيرنوى. و قد توافق ما وجد خلال هذه الدراسة مع ما لوحظ فى غيرها من ان هذه الغدة تظهر حال ازالة الجلد، فهى ليست مغطاة باى عضلة.

تعد هذه الدراسة من اوائل تلك التى تعاملت مع الشعبان الخضارى *Malpolon monspessulanus insignitus* بشيء من التفصيل، سواء من الناحية المظهرية الخارجية او التشريحية او تلك النسيجية. ولكن ذلك لا ينفى الحاجة الى دراسات اضافية حول هذا النوع سيما وان الأردن يعتبر موطننا مناسباً له.