

## MICROSURGICAL AND RADIOLOGICAL ANATOMY OF THE SPHENOID SINUS IN ADULT EGYPTIANS

By

Yousef Barakat, Elsayed Elmor\*, Mohamed Kamal Abd El Aziz\*\*  
and Mahmoud Abo El Fadle\*\*\*.

*From neurosurgery\*, Otorhinology\*\* and Radiology\*\*\*  
Departments, Faculty of Medicine, Al-Azhar University*

---

### ABSTRACT:

The demands for successful pituitary and sphenoid sinus surgery necessitates more microsurgical and radiological details of the sphenoid sinus anatomy.

The present study is formed of two parts; an anatomical study, and a radiological study

The anatomical study was conducted on twenty sphenoid tissue blocks containing the sphenoid sinus which were removed from the cranial base of adult Egyptian cadavers and have been dissected. The radiological study was performed on 100 adult Egyptian volunteers using plain X-ray, and CT Scan. The results were discussed.

### INTRODUCTION and AIM OF THE WORK:

Trans-sphenoidal approach to the pituitary tumours became popular among

neurosurgeons and otorhinology surgeons in Egypt. Increasing use of this approach has created a need for detailed anatomical study of the sphenoid sinus both microsurgical and radiological, which is also important in performing subcranial approach to the sellar region. The sphenoid sinus is subjected to considerable variations in size, degree of pneumatization, and position in relation to the sella turcica.

The aim of the present work is to study the anatomical patterns of the sphenoid sinuses and their variations in adult Egyptians, microsurgically and radiologically.

### MATERIAL and METHODS:

Twenty sphenoid tissue blocks containing the sphenoid sinus were removed from the cranial base of adult Egyptian cadavers and then dissected. The equipments used were:

1- Surgical operating microscope (ZIESS OPMI 6).

2- Least number and simplest micro-instruments

3- Varenner caliber for estimation of bone thickness

One hundred of adult Egyptian volunteers (60 males and 40 females) were radiologically studied as follow:

1- Plain X-ray skull, posteroanterior and lateral views.

2- Magnification correction factor was calculated using the following equation:

$\frac{D-d}{D}$  where D is the focal film distance and d is the distance between the object and the film and the actual dimensions = dimensions seen on the film x magnification correction factor (Meschan, 1975).

3- CT of the sphenoid sinus: Axial, coronal, and sometimes saggital reformatting cuts were done. The plane for axial was parallel to the inferior orbital line and the angle of the coronal was 50 - 75° with the inferior orbital line and the thickness of the slice was 5 mm or less.

## RESULTS:

### A- Anatomical results:

1- Types of sphenoid sinus: In the present study the sphenoid sinus was sellar in 16 specimens (80 %) and presellar in 4 specimens (20%).

2- Septation of sphenoid sinus (Fig 1): In 13 specimens (65 %) the sphenoid sinus has 2 large cavities with one septum located off the midline in all the 13 cases, and in 7 specimens (35 %) there were multiple septae which were very variable in their size, shape, location and com-

pletteness.

3- Bulges in the sphenoid sinus (Fig 2):

a- Bulges in the superior wall (sellar floor): It was central in position in all specimens (100 %), ovoid and smooth in 15 specimens (75 %), and had a degree of deformity in 5 specimens (25 %).

b- Bulges in the lateral wall: The carotid artery formed a bulge in 10 specimens (50 %), and the optic canal has a bulge in superolateral wall of the sinus in 5 specimens (25%).

4- Thickness of the sellar floor: It was 1 mm or less in 15 specimens (75 %) and more than 1 mm in 5 cases (25 %).

5- This study showed that the vomer and sellar bulge are constant midline structures (Fig 3).

6- Dimensions of the sphenoid sinus (Figs. 4,5):

\* The antero posterior diameter of the sphenoid sinus ranged from 1.2 cm to 3 cm.

\* The transverse diameter ranged from 0.6 cm to 2.1 cm.

\* The vertical diameter ranged from 1 cm to 3 cm.

### B- Radiological Results:

Examination of 100 adult Egyptian volunteers by plain X-ray, and CT scan revealed the following:

1- Types and pneumatization of sphenoid sinus: From the lateral plain X-ray the cases were classified into the following types:

a- *Conchal* in which the sphenoid sinus

is slightly pneumatized and was found in one case (1%) (Fig. 6).

b- *Presellar type* in which the pneumatization is only anterior to the tuberculum sellae and was found in 19 cases ( 19 %)(Fig. 7).

c- *Sellar type* in which pneumatization extend to the floor of the sella (partially or completely) or extend beyond the sellar floor and was found in 80 % of the cases (Fig.8) .

II- Septation of the sphenoid sinus (Figs. 9,10): The sphenoid sinus septations were studied mainly from CT scan and the pattern of septations were as follow:

a- 60 % of cases had septum reaching the floor of the sella which is near the midline in anterior part of sellar floor in 20 % cases and located off midline in 40 % cases.

b- 40 % of the cases had multiple septae which differ in location, direction, and completeness .

III- Dimensions of the sphenoid sinus (Fig. 11, 12, 13): In the present study it has been found that the minimum antero-posterior diameter (length) of the sphenoid sinus was 1 cm, and the maximum was 3.2 cm . The minimum transverse diameter (width) was 0.6 cm, and the maximum was 2.1 cm . The minimum vertical diameter (height) was 1 cm and the maximum was 3 cm.

Table (1): Illustrates the anatomical results:

Type :	Sellar (80%)		Presellar (20%)	
Septation:	One Septum (65%)		Multiple septae (35%)	
Bulges:	in superior wall*		in later wall	
	Ovoid (75%)	with deformity (25%)	Carotid artery (50%)	Optic canal (25%)
Thickness**	< 1 m (75%)		> 1 mm (25%)	

\* = Sellar bulge which is central 100% of cases

\*\* = Of sellar floor

Table (2): Illustrates the radiological results

Types	Conchal (1%)	Presellar (19%)	Sellar (80%)
Septations:	One septum (60%)		Multiple septae (40%)
Dimensions:	Anteroposterior	Transverse	Vertical
	min. ≤ 1 cm max. 3.2 cm	min. 0.6 cm max. 2.1 cm	min. 1 cm max. 3 cm

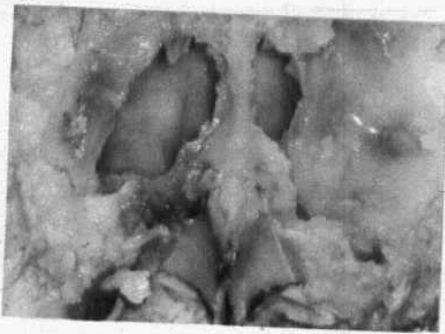


Fig (1): Sphenoid sinus with one off - midline septum.

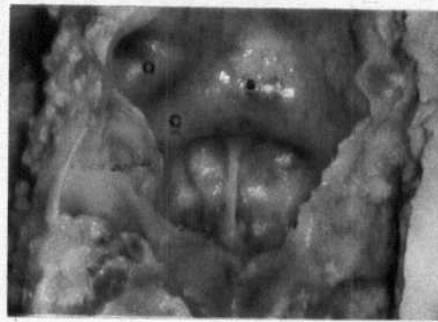


Fig (2): Bulges in the cavity of the sphenoid sinus.

S = Sellar bulge.  
C = Carotid bulge.  
O = Optic bulge.

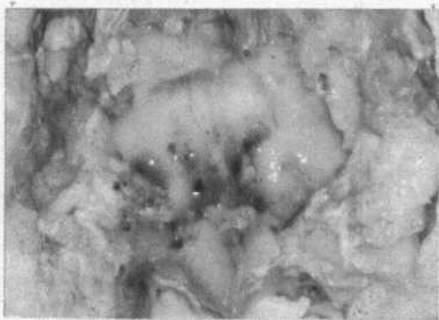


Fig (3): Vomer and sellar bulge are constant midline structures.

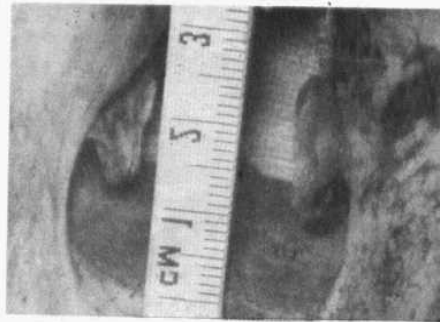


Fig (4): A. P. diameter (length) of the sphenoid sinus.

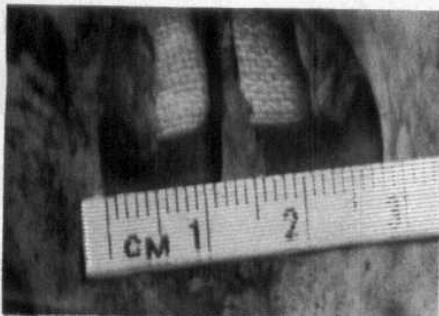


Fig (5): Transverse diameter (width) of the sphenoid sinus.

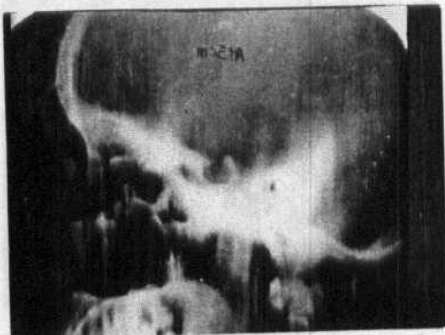


Fig (6): Lateral P. X. ray showing conchal type of sphenoid sinus.

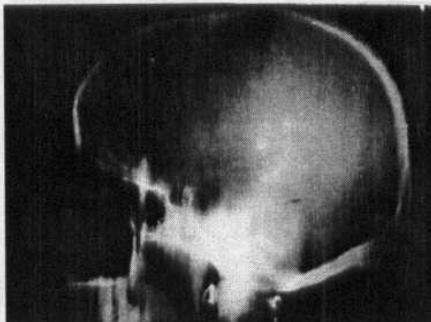


Fig (7): Lateral P.X. ray showing presellar type of sphenoid sinus.

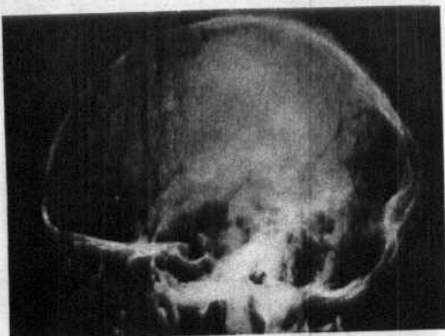


Fig (8): Lateral P. X. ray showing sellar type of sphenoid sinus.

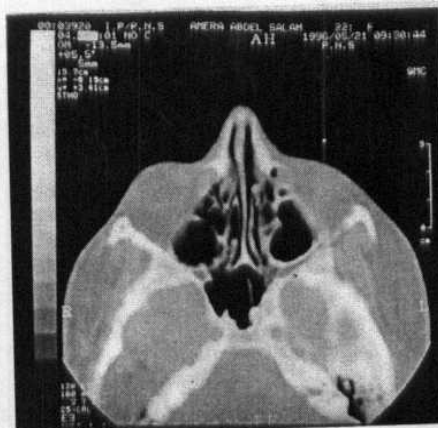

Fig (9): Axial C. T. of the sphenoid sinus showing one septum located off midline.

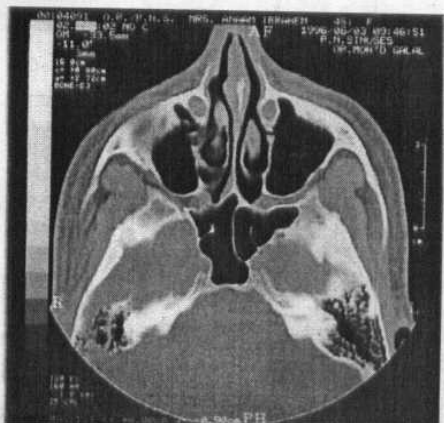


Fig (10): Axial C. T. showing multiple septae.

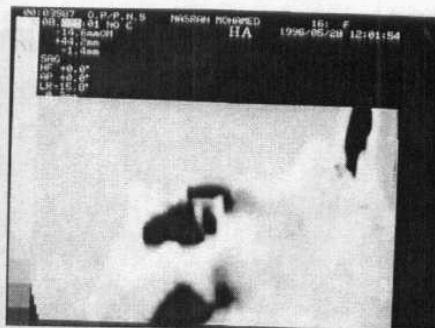

Fig (11): Sagittal reformed C. T. showing A. P. diameter (length) of the sphenoid sinus.

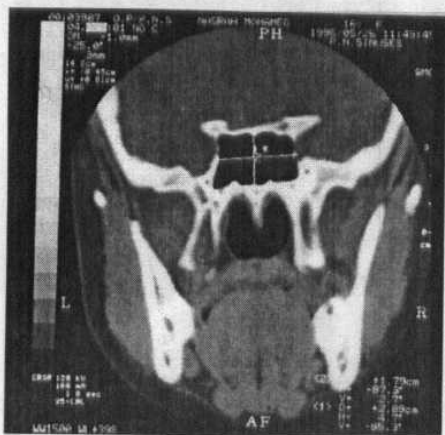

Fig 12: Coronal C. T. showing vertical (height) and transverse (width) diameters of the sphenoid sinus.

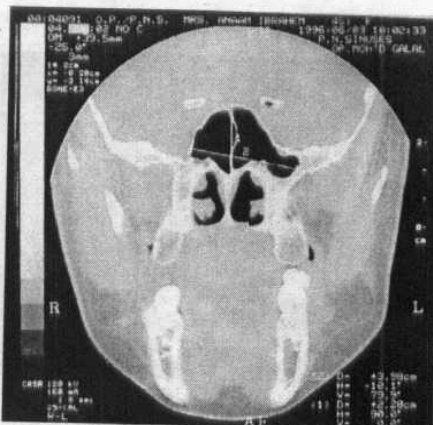


Fig (13): Another coronal C.T. scan showing vertical (height) and transverse (width) diameters of the sphenoid sinus.

**DISCUSSION:**

Anatomical and radiological studying of the sphenoid sinus is very important because the sphenoid sinus may be entered to remove a primary disease within it, or the sinus may serve as an approach to the sella turcica .

The normal sphenoid sinus is subjected to many anatomical and radiological variations . In the present study the sellar type of the sphenoid sinus was 80 % of cases which is more or less similar to the studies conducted by (Hamberger et. al. ,1961) , (Hammer and Radberg ,1961), and (Renn and Rhoton, 1975), where their percents were 86%, 85 % and 80 % respectively .

No cochal type was encountered in the anatomical part of the present study, but it was found in only one case in the radiological part of this study .

The presellar type was nearly 20% of cases in the present study , which is more than that found by (Hamberger et. al., 1961) and Hammer and Radberg,1961).

The present study revealed one major septum mostly located off midline in 60 % of the specimens in the anatomical part of the study and in 65% of cases in the radiological study and CT was used to define the relation of the septum to the floor of the sella, the results did not show a great variation from the findings of (Renn and Rhoton ,1975) where their percent was 68%

The sellar floor thickness was 1 mm or less in 75 % of the specimens which is near to the results obtained by (Bergland ,1968) which was 72% but differ from that of (Renn and Rhoton, 1975) which was 82 %.

As regards to the bulges in the sphenoid sinus the sellar bulge was found in all cases (100 %)

The carotid artery bulge was found in 50% of the specimens that differ from that of (Renn and Rhoton,1975) which was 71 % .

The optic canal bulge was found only in 25 % of the specimens .

The dimensions of the sphenoid sinus were studied radiologically mainly by CT in axial, coronal and reformatted saggital cuts .

The anteroposterior diameter ( length ) in this study ranged from 1 cm to 3 cm while in the study of (Dixon, 1937) the length was between 20.09 mm and 23.20 mm

The vertical diameter (height) in this study ranged from 1 cm to 3 cm but in the study of (Dixon, 1937) the height was between 16.44 and 20.41 mm

The transverse diameter (width) in this study ranged from 0.6 cm to 2.1 cm while in the study of (Dixon ,1937) the width ranged from 15.25 mm to 17.12mm

**CONCLUSION:**

This study has shown the normal marked anatomical and radiological variations of the sphenoid sinus in adult Egyptians and also has shown that vomer and sellar bulge are constant midline structures

So this makes apparent that studying of imaging findings of sphenoid sinus region is of utmost importance before dealing surgically with the sphenoid sinus as approach to sellar region or to remove a primary lesion within that sinus .

## REFERENCES:

- 1- Bergland R.M., Rany B.S., Torack, M. (1968): Anatomical variations in the pituitary gland and adjacent structures in 225 human autopsy cases . J. Neurosurgery 28: 93 - 99.
- 2- Dixon, F.W., (1937): Annals of otology, Rhinology, and laryngology . 76: 687
- 3- Hamberger, C.A., Hammer, G., Norlen, G. and et. al. (1961): Transantrosphenoidal Hypophysectomy. Arch. Otolaryngol. 74:2-8
- 4- Hammer, G. and Radberg, C. (1961): The sphenoid sinus, an anatomical and roentgenologic study with reference to transsphenoidal hypophysectomy . Acta radiol . 56: 401-422.
- 5- Meschan, I. (1975): An atlas of anatomy basic to radiology, first edition, W.B. Saunders Company, philadelphia . Page 17.
- 6- Renn, W.H., and Rhoton, A.L. (1975): Microsurgical Anatomy of the sellar region. J. Neurosurgery . 43:288-298.

### التشريح الجراحي الدقيق والإشعاعي للجيب الوتدي في المصريين البالغين

يوسف بركات\*، السيد المر\*، محمد كمال عبد العزيز\*\*،

محمود أبو الفضل\*\*\*

من أقسام جراحة المخ والأعصاب\*، والأذن والأنف والحنجرة\*\*، والأشعة\*\*\*

بكلية الطب - جامعة الأزهر

إن الحاجة إلى جراحة ناجحة لأورام الغدة النخامية والجيب الوتدي تتطلب مزيداً من التفاصيل التشريحية والإشعاعية لهذا الجيب الوتدي، خاصة في المرضى المصريين البالغين. وقد أجريت هذه الدراسة على عشرين كتلة وتدية تحتوى على الجيب الوتدي حيث تم فصلها من قاع جماجم بلثث مصريين بالغين ثم تم تشريحها. أما الدراسة الإشعاعية فقد أجريت على مائة شخص متطوع، حيث استخدمت الأشعة المستوية والمقطعية لهذا الغرض. وقد تم عرض النتائج ومناقشتها.