

CONTACT EXPOSURE OF RED BALADI RABBITS TO DIAZINON INDUCES PHYSIOLOGICAL AND HISTOPATHOLOGICAL CHANGES

Okab A. B.*, El-Nabarawy I. M.**, Sabah G. El-Banna* And Mona A. H. Yehia***

* Department of Environmental Studies, Institute of Graduate Studies and Research,

*** Histochemistry and Cell Biology, Medical Research Institute,

Alex. Univ., Egypt (E-Mail: abokab@hotmail.com)

** Department of Plant Protection, National Research Center, Cairo, Egypt

ABSTRACT

Objectives: Diazinon are widely used as pesticides in agriculture. So, the current work aimed to investigate the effects of diazinon exposure on some physiological aspects, histopathological changes and histochemical acetylcholinesterase in red Baladi rabbits.

Methods: Seventy-two red Baladi bucks were distributed into three groups, the rabbits of the first group were dipped into tap water and served as control group. The rabbits of the second and the third groups were dipped in diazinon at concentrations of 0.6 mg (DLC) and 3 mg (DHC) dissolved in one liter of water, respectively for 10 sec. This step was repeated after 10 days. The animals were sacrificed by jugular vein incision after 0, 1, 3, 7, 15 and 21 day following the second dipping of rabbits in diazinon.

Results: In whole blood, diazinon decreased rabbits's RBC's ($P < 0.01$) and Hb ($P < 0.05$), while MCV and MCH were elevated ($P < 0.01$) for both tested concentrations, but PCV values were increased only ($P < 0.01$) in the DHC group. In plasma TP was decreased ($P < 0.01$) in both tested concentrations, however cholesterol was increased ($P < 0.01$) in the DLC and DHC groups. Meanwhile hydroxylamine and nitrite were increased only in the DHC treated group. Liver body weight ratio and cytochrome P-450 were decreased ($P < 0.01$) in both tested concentrations, while microsomal protein was increased ($P < 0.01$) in both concentrations. RBC's, PCV and microsomal protein were increased ($P < 0.01$) by the days of treatment. Meanwhile, MCV, MCH, MCHC, liver body weight ratio and cytochrom P-450 were decreased ($P < 0.01$) by the days of treatment. There was no definite trend with days of treatment for WBC's, Hb, TP, cholesterol, hydroxylamine and nitrite. There was a highly significant effect of concentration X day interaction ($P < 0.01$) on all tested parameters. Histopathological changes of liver, kidney and brain were observed after DHC dipping. Glycogen content was decreased in liver and increased in kidney Bowman's capsule. Furthermore, the AChE activity was inhibited in brain tissue and decreased in liver and gradually increased in kidney glomeruli cells.

Conclusion: Exposure of animals to diazinin caused extensive changes in physiological, histochemical and histopathological parameters, the kidney and brain were highly affected by the diazinon exposure when compared with liver. Diazinon lead to negative response on animal performance.

Key words: Diazinon, Rabbits, Physiological aspects, Cytochrome P-450, Histochemistry and Acetylcholinesterase.

Abbreviations:

- DLC= Diazinon low concentration.
- DHC = Diazinon high concentration
- WBC's = White blood cells
- RBC's = Red blood cells
- PCV = Packed cell volume
- Hb = Hemoglobin
- MCV = Mean corpuscular volume
- MCH = Mean corpuscular hemoglobin
- MCHC = Mean corpuscular hemoglobin concentration
- TP = Total protein
- BSA = Bovine serum albumin
- H&E = Hematoxylin and Eosin
- PAS = Periodic acid Schiff's reagent
- AChE = Acetylcholinesterase

INTRODUCTION

Organophosphorus compounds have been utilized as pesticides for almost five decades, particularly as insecticides, helminthocides, ascaricides, nematocides, and to a lesser degree as fungicides and herbicides. Their continuous use proved to be extremely useful in agricultural pest control throughout the world, but this extensive use had led to numerous poisonings of nontarget species, including many human fatalities. The primary acute mammalian toxicity associated with the exposure to organophosphorus pesticides results from the inhibition of acetylcholinesterase enzyme.⁽¹⁾ Diazinon {O, O - diethylO - [6 - methyl - 2 - (1-methylethyl) - 4 - pyrimidinyl] phosphorothioate} is an organophosphate insecticide used to control a

variety of insects.⁽²⁾ Diazinon toxicity has been reported in a variety of species. Reece and Handson (1982)⁽¹⁾ reported that a flock of show birds dusted with powder containing diazinon at 15 g / kg showed respiratory distress within 5 min., and were unable to use their legs and died within 1 hour. Diazinon exerts its toxicity by binding its oxygen analog to the neuronal enzyme AChE, resulting in the accumulation of endogenous acetylcholine in nerve tissues and effectors organs.⁽³⁾ However, other toxicities, some of which are life-threatening but are not related to acetyl cholinesterase inhibition, have been observed following exposure to certain organophosphorus compounds.⁽⁴⁾

The main objective of this study was to find out whether diazinon has a significant effect on some

physiological parameter, histopathological changes and histochemical AChE on the liver, kidney and brain in red Baladi rabbit under low and high exposure.

METHODS

This experiment was carried out at the Institute of Graduate Studies and Research, Alexandria University. During the experimental period the rabbits were individually housed in universal galvanized wire batteries with food and fresh tap water offered ad libitum. A commercial balanced pelleted ration for breeding rabbits containing 18% crude protein, 14% crude fiber, 2% fat and 2600 kcal DE/kg feed was used.

Experimental Design:

Seventy-two red Baladi bucks, 6 month of age and 1.4 ± 0.12 kg live body weight were distributed randomly into three groups of 24 animals each. Each animal in the first group was dipped into tap water and served as control. Animals of the second and third groups were dipped either in diazinon (obtained from Ciba Geigy, All India Medical Co.) at 0.6 mg diazinon low concentration (DLC) and 3 mg diazinon high concentration (DHC) dissolved in one liter of water, respectively for 10 sec. The previous step was repeated after 10 days. The animals were sacrificed by jugular vein incision after 0, 1, 3, 7, 15 and 21 days following the second dipping of rabbits in diazinon.

Blood Analysis:

Blood samples were obtained by sacrificing the animals by jugular vein incision and were placed immediately on ice. Heparin was used as anticoagulant. Plasma was obtained by blood centrifugation at 3,000 rpm for 20 min. and then stored at -20°C until used for analysis. The whole blood was analyzed shortly after collection for white blood cells (WBC's), red blood cells (RBC's), and packed cell volume (PCV), hemoglobin (Hb). Plasma was used for the determination of total protein (TP), cholesterol, nitrite and hydroxylamine.

Hemoglobin concentration was determined in whole blood shortly after collection using Hb kits obtained from Diamond Diagnostics Egypt. RBC's were counted on an AO bright line hemocytometer using a light microscope at 430X magnification. Blood samples were diluted 200 times with physiological saline (0.9 % sodium chloride solution) before counting. Microhematocrit tubes with a hematocrit centrifuge (5 min. at 16,500 Xg) were used to determine PCV. WBC's were counted on an AO bright line hemocytometer using a light microscope at 100 X magnification after diluting blood samples 20 times with a diluting fluid (1 % acetic acid and little of Leshman's stain) before counting. Total protein and cholesterol were determined using kits obtained from Bio ADWIC, Egypt.

Hydroxylamine and nitrite were determined using formation of Azo Dye compound. Hydroxylamine can be oxidized to nitrous acid by iodine in acetic acid solution. If the oxidation occurs in the presence of sulfanilic acid, the latter is diazotized by the nitrous acid. After the removal of the excess iodine by means of thiosulfate, the P-diazonium-benzenesulfonic acid can be coupled with α -naphthylamine to produce the red azo dye 4- (P-sulfophenyl azo) - α -naphthylamin.⁽⁵⁾

Liver Microsomal Enzymes and Protein:

Liver was removed, washed with cold 0.1 M phosphate buffer, pH 7.4, weighed, chilled on ice, and all the following procedures were carried out in cold conditions (i.e over ice at 4°C). A 33 % (W/V) crude homogenate was prepared in 0.1 M phosphate buffer, pH 7.4 by homogenization with a teflon pestle, using 5 strokes. The crude homogenate was then centrifuged at 11,000 Xg for 20 min. at 4°C to remove the intact cells, nuclei and mitochondria. The supernatant solution was subsequently centrifuged at 105,000 Xg for 60 min. at 4°C to sediment the microsomal pellet. The latter was suspended in 0.1 M phosphate buffer, pH 7.4, kept on ice bath and used for the determination of liver microsomal cytochrome P-450⁽⁶⁾ and protein concentration.⁽⁷⁾ Bovine Serum Albumin (BSA) was used as standard.

Histopathological Study:

Liver, kidney and brain were dissected and fixed in 10% neutral formalin, dehydrated in ascending grades of alcohol and imbedded in paraffin wax. Paraffin sections (5μ thick) were stained for routine histological study using Hematoxylin and Eosin (H&E). Other sections were stained by periodic acid Schiff's reagent technique (PAS) for demonstrating a glycogen content.⁽⁸⁾ In addition, acetylthiocholines iodide was used for demonstrating histochemical activity of acetyl cholinesterase enzyme.⁽⁹⁾

Statistical Analysis:

Data were analyzed by general linear model (GLM) SAS, (1995).⁽¹⁰⁾ Significant differences among means were detected using Duncan's Multiple Range Test.

RESULTS

Physiological and Biochemical Results:

Tables (I.&II) show the effect of diazinon concentration, day of treatment and their interaction on WBC's, RBC's counts, PCV, Hb, mean corpuscular volume (MCV), mean corpuscular hemoglobin (MCH), mean corpuscular hemoglobin concentration (MCHC), TP, cholesterol, hydroxylamine, nitrite, liver body weight ratio (LBWr), microsomal protein and cytochrome P-450. The tested parameters were significantly affected ($P<0.01$) by diazinon concentration except WBC's and MCHC. Day of treatment and their interaction had also significant effect. Dipping rabbits in DLC

and DHC induced significant ($P < 0.01$) reduction in RBC's counts and significant elevation in PCV value (Table III.) of the DHC group. The overall mean values of RBC's for control, DLC and DHC were 5.6 ± 0.12 , 4.5 ± 0.22 and $4.3 \pm 0.30 \times 10^6/\text{mm}^3$, respectively (Table III.). On the other hand, WBC's, RBC's and PCV were increased with the day of treatment ($P < 0.01$) reaching the highest values after 21 days from DHC dipping.

Diazinon concentration caused significant decrease ($P < 0.05$) in blood Hb, and significant increases ($P < 0.01$) in MCV and MCH in a dose-dependent manner. Meanwhile, the overall mean of MCV, MCH and MCHC were declined ($P < 0.01$) with the days of exposure (Table IV.), but blood Hb showed no definite trend.

Diazinon induced significant ($P < 0.01$) changes in TP, cholesterol, hydroxylamine and nitrite (Table V.). TP was reduced in rabbits exposed to either concentration and the effect was dose-dependent, while cholesterol concentrations were elevated in both groups. Hydroxylamine and nitrite were increased only in the DHC group. TP, cholesterol, hydroxylamine and nitrite showed irregular trend with the day of treatment. While TP and cholesterol reached the lowest values ($P < 0.01$) after 21 days from DHC dipping, hydroxylamine and nitrite reached the highest values ($P < 0.01$) at the end of the experimental period.

The effects of diazinon concentration and the days of exposure on liver body weight ratio, microsomal protein and cytochrome P-450 were significant (Table VI.). The overall mean values for liver body weight ratio and cytochrome P-450 were decreased ($P < 0.01$) in a dose dependent manner, while microsomal proteins were increased ($P < 0.01$). Additionally, liver body weight ratio and cytochrome P-450 reached the lowest values after 21 days from DHC dipping, while microsomal proteins were significantly ($P < 0.01$) increased.

Histopathological Results:

Paraffin sections of rabbit's liver, kidney and brain stained with H&E are illustrated in plate I containing nine figures (A-C liver), (D-F kidney) and (G-I brain). Control liver sections showed normal hepatic tubules, a polyhedral hepatocytes with control vesicular nuclei and granular cytoplasm were observed (Fig. A). The animals exposed to DLC showed undetectable changes in the studied organs. However, the histopathological examination for animals dipped in DHC showed that the liver cells lost their radial arrangement. There were fatty changes in hepatocytes and cellular infiltration around the center vein and portal tracts. Interlobular mononuclear inflammatory cells among fatty hepatic cells and dilated congestion sinusoid were seen around hepatic venule (Figs. B&C).

The control kidney cortex sections, revealed

normal appearance of renal corpuscles which appear as rounded structures. The glomeruli, surrounded by narrow Bowman's spaces and cortical tubules with small numbers of distal convoluted tubules and collecting tubules (Fig. D). The histopathological changes observed in the rabbit kidney included swelling of convoluted tubules and congestion of both intraglomerular capillaries and peritubular vessels in both dipping of diazinon concentrations. The distal tubules showed adenomatous hyperplasia and proliferation. There was mononuclear infiltrating cells among proliferating convoluted tubules mostly in the DHC group (Figs. E&F).

The control cerebral cortex sections illustrated neurons varying in size and shape. Astrocytes cell characterized by large polygonal nuclei, with central nucleoli. Oligoendrocytes have rounded nuclei and clear perinuclear halo. They adjacent to neurons are called satellite cell. Numerous small capillary vessels were observed (Fig. G). At DLC exposure mild changes were noted, but at DHC there were more histological changes consisting of shrinkage of cell body, pyknosis of the nucleus and disappearance of nucleolus. The multiply rows of large nerve cell (purkinje cells) at the junction of the molecular layer with the granular layer was noted. Neuron cells forming large infiltrating, which vary greatly in size and shape have hyperchromatic and polymorphic nuclei containing many prominent nucleoli. Each cells have large clear perinuclear cytoplasmic vacuole. Other area of granular layer consisting of population of small uniform cell, have moderate amount of eosinophilic cytoplasm and small rounded basophilic nuclei. A mild degenerative changes of nerve fiber, fragmentation, space formation and congestion of blood vessels were observed (Figs. H&I).

Histochemical Results

Glycogen: paraffin sections of rabbit liver, kidney and brain stained with PAS are illustrated in plate II containing six figures (A-C liver) and (D-F kidney). The control liver showed the homogenous feature of glycogen, that were arranged in regular line for all hepatocytes (Fig. A). In rabbits exposed to both concentrations, a disturbance of glycogen content was shown. That were polling in one side of cell in most hepatocytes and absence of glycogen content in fatty hepatic cells (Figs. B&C). Control kidney sections demonstrated PAS positives in the brush border and basement membrane of Bowman's capsules (Fig. D). At low concentration of diazinon a decrease in glycogen content observed faint. At high concentration an increase of glycogen content was noticed at basement membrane of both Bowman's capsule and renal tubules. The surfaces of microvilli are coated with a particularly dense glycogen. Decrease in glycogen content in brush border and cutting of Bowman's capsules appeared (Figs. E&F). Whereas, the glycogen content was absent in cerebral cortex.

Acetylcholinesterase: Paraffin sections are illustrated in plate III containing nine figures (A-C liver), (D-F kidney) and (G-I brain). Histochemistry of AChE activity was moderate in control rabbit liver sections and appeared as brown fine granules in the peripheral part of the cytoplasm and plasma membrane in the interlobular area. Reduction of AChE activity dispersed at the cell membrane of hepatocyte around the portal tract and bile duct in most hepatocytes post 21 days of DHC dipping. Control rabbit kidney cortex demonstrated weak AChE activity in renal tubules and moderate activity

in the glomeruli basal lamina of capillary loops. At high concentrated dipping, an increased AChE activity in the glomeruli mesangial cell and basal lamina of Bowman's capsule were noticed and moderate activity of AChE was observed in basement membrane of most renal tubules. As regard to brain sections, moderate AChE activity in most neurons cell body and dendrites process was observed as well as lined the capillary vessel. After DHC exposure, weak activity of AChE in most hyperchromatic neuron and in area of proliferating cells in granular layer were observed.

Table I. Mean squares for the effect of diazinon concentration, days and their interaction on WBC's, RBC's, PCV, Hb, MCV, MCH, MCHC, Tp and Cholesterol.

S.O.V.	concentration	Day	Concentration X Day	Error
Df.	2	5	10	54
Parameters				
WBC's	0.37	3.09**	1.48**	0.22
RBC's	12.26**	8.12**	3.48**	0.16
PCV	40.72**	215.91**	60.74**	0.84
Hb	2.29*	20.94**	8.71**	0.57
MCV	8384.1**	4574.7**	3059.4**	64.2
MCH	795.2**	909.7**	403.2**	11.8
MCHC	6.2	101.0**	40.5**	3.7
T. Protein	130.1**	5.0**	12.9**	1.2
Cholesterol	130.1**	5.0**	12.9**	1.2

* P < 0.05, ** P < 0.01

Table II. Mean squares for the effect of diazinon concentration, days and their Interaction on hydroxylamine, nitrite, liver body weight ratio (LBWr), Microsomal Protein and Cytocrome P-450.

S.O.V.	Df	Hydroxyl amin	Nitrite	LBWr	Microsomal Protein	Cytocrome P-450
Concentration	2	7914.8**	26.8**	5.74**	4.48**	24587**
Day	5	4105.4**	5.7**	1.10**	1.60**	2507**
ConcentrationXDay	10	2180.4**	4.9**	0.74**	0.52**	637**
Error	54	119	1.2	0.03	0.02	1.09

** P < 0.01

Table III. Changes in white blood cells (WBC's), red blood cells (RBC's) and packed cell volume (PCV) in Baladi rabbits treated with diazinon (Mean \pm SEM).

DAYS	WBC's ($\times 10^3 / \text{mm}^3$)			RBC's ($\times 10^6 / \text{mm}^3$)			PCV (%)		
	Control	DLC	DHC	Control	DLC	DHC	Control	DLC	DHC
0	4.5 0.1	4.2 0.21 4.0 0.16 ^{bc}	3.5 0.28 **	5.4 0.17	2.2 0.12 3.5 0.43 ^c	2.8 0.09 **	43.0 0.41	39.5 0.29 41.3 0.46 ^c	41.3 0.25 **
1	4.2 0.26	5.4 0.18 4.7 0.20 ^a	4.6 0.29	5.8 0.40	4.7 0.08 4.3 0.44 ^d	2.4 0.03	44.0 0.41	30.5 0.29 37.6 1.70 ^f	38.3 0.63
3	4.1 0.24	3.8 0.05 3.6 0.19 ^d	2.8 0.13	5.4 0.38	5.0 0.15 5.1 0.15 ^b	5.0 0.21	41.3 0.48	43.3 0.48 43.8 0.76 ^c	47.0 0.41
7	4.2 0.48	4.0 0.1 4.3 0.18 ^b	4.6 0.22	5.8 0.31	4.7 0.11 4.7 0.27 ^c	3.8 0.09	41.3 0.48	42.3 0.75 42.3 0.39 ^d	43.3 0.48
15	4.5 0.47	2.9 0.05 3.8 0.26 ^{cd}	4.0 0.23	5.3 0.18	5.2 0.16 5.4 0.12 ^{ab}	5.8 0.16	43.5 0.65	45.8 0.25 47.0 1.07 ^b	51.8 0.25
21	4.6 0.04	4.8 0.22 4.9 0.10 ^a	5.1 0.09	6.0 0.18	5.1 0.25 5.7 0.17 ^a	6.2 0.14	47.3 0.75	53.0 0.01 49.5 0.79 ^a	48.3 0.25
Over All mean	4.3 0.12	4.2 0.17 ns	4.1 0.18	5.6 0.12 ^A	4.5 0.22 ^B **	4.3 0.30 ^B	43.4 0.47 ^B	42.4 1.42 ^C **	45.0 0.95 ^A

Means with different superscript letters vary significantly ($P < 0.05$); small letters are used for comparing days, capital letters are used for comparing doses. (** $P < 0.01$ for comparing main effects). DLC and DHC refer to low and high concentrations of diazinon.

Table IV. Changes in blood hemoglobin (Hb), mean corpuscular volume (MCV), mean corpuscular hemoglobin (MCH), mean corpuscular hemoglobin concentration (MCHC) in Baladi rabbits treated with diazinon (Mean \pm SEM).

DAYS	Hb (gm/dl)			MCV (cu μ)			MCH (pg)			MCHC (%)		
	Control	DLC	DHC	Control	DLC	DHC	Control	DLC	DHC	Control	DLC	DHC
0	13.9 0.56	13.7 0.36	14.2 0.45	79.3 1.9	178.9 8.4	149.3 5.4	25.7 1.1	62.9 4.4	51.5 2.35	32.4 1.32	35.1 0.9	34.4 1.2
		13.9 0.25 ^b	**		135.8 13.97 ^a	**		46.7 4.94 ^a	**		34.0 0.7 ^a	**
1	14 0.59	11.5 0.29	12.6 0.40	76.8 5.4	65.3 0.94	157.3 2.4	24.3 1.3	24.7 0.95	52.0 2.64	31.8 1.6	37.8 0.94	33.0 1.5
		12.7 0.39 ^c			99.8 12.46 ^b			33.7 4.02 ^b			34.2 1.1 ^a	
3	13.2 0.40	10.7 0.10	11.2 0.35	73.6 3.4	86.9 3.2	94.4 4.5	23.7 1.7	21.4 0.70	22.6 1.30	32.1 0.95	24.5 0.45	23.9 0.89
		11.7 0.37 ^d			84.9 3.24 ^d			22.5 0.73 ^d			26.8 1.2 ^d	
7	13.4 0.37	10.3 0.45	12.8 0.10	71.8 3.3	89.8 1.8	115.1 2.3	23.2 0.73	22.1 1.3	34.0 0.78	32.4 0.59	24.5 1.4	29.5 0.21
		12.1 0.44 ^{cd}			92.2 5.51 ^e			26.4 1.70 ^e			28.8 1.09 ^e	
15	13.0 0.24	14.1 0.15	15.5 0.47	81.8 2.9	88.9 3.11	81.6 3.1	24.5 0.57	27.5 0.93	26.8 1.36	30.0 0.83	30.9 0.42	29.9 0.91
		14.2 0.34 ^b			84.1 1.89 ^d			26.3 0.65 ^e			30.3 0.42 ^{bc}	
21	13.9 0.23	17.4 0.38	14.1 0.33	79.3 3.5	105.0 5.0	83.5 4.9	23.2 0.95	34.6 2.3	24.4 0.51	29.4 0.48	32.9 0.71	31.2 0.49
		15.1 0.52 ^a			89.2 4.13 ^{cd}			27.4 1.72 ^e			31.1 0.53 ^b	
Over All mean	13.6 0.17 ^A	13.0 0.52 ^B	13.4 0.31 ^{AH}	77.1 1.5 ^C	102.5 7.7 ^B	113.5 6.5 ^A	24.1 0.44 ^C	32.2 3.11 ^B	35.2 2.61 ^A	31.3 0.45	30.9 1.09	30.3 0.78
		*			**			**			ns	

Means with different superscript letters vary significantly ($P < 0.05$); small letters are used for comparing days, capital letters are used for comparing doses (* $P < 0.05$, ** $P < 0.01$ for comparing main effects). DLC and DHC refer to low and high concentrations of diazinon.

Table V. Changes in total protein (TP), cholesterol, hydroxyamine and nitrite in Baladi rabbits treated with diazinon (Mean \pm SEM).

DAYS	Total protein (gm/dl)			Cholesterol (mg/dl)			Hydroxyamine (mg/l)			Nitrite (mg/l)		
	Control	DLC	DHC	Control	DLC	DHC	Control	DLC	DHC	Control	DLC	DHC
0	10.4 0.49	6.8 .005	6.9 .005	62.5 13.2	105.7 4.3	67.1 0.41	5.5 0.00	5.1 0.03	5.0 0.05	3.1 0.19	3.8 0.06	4.7 0.21
		8.0 0.52 ^{ab}	**		78.4 7.2 ^c	**		5.2 0.07 ^{ab}	**		3.9 0.22 ^b	**
1	10.4 0.12	6.0 .005	8.3 .005	69.8 5.2	138.9 4.7	76.4 0.30	3.7 0.13	4.7 0.08	5.0 0.06	1.9 0.04	1.9 0.13	4.5 0.21
		8.2 0.53 ^a			95.0 9.6 ^b			4.5 0.17 ^{bc}			2.7 0.37 ^c	
3	9.0 0.36	9.5 .005	3.1 .005	54.9 4.9	133.2 0.4	135.1 4.55	2.7 0.38	3.6 0.19	7.7 1.40	1.9 0.04	3.2 0.56	5.5 0.09
		7.2 0.89 ^{bc}			107.7 11.4 ^a			4.7 0.80 ^{bc}			3.5 0.48 ^b	
7	11.7 1.32	6.8 .005	7.0 .005	72.4 10.0	98.9 0.49	61.5 0.37	2.6 0.28	4.2 0.38	5.5 0.02	5.3 0.10	4.2 0.36	4.7 0.24
		8.5 0.79 ^a			77.6 5.6 ^c			4.1 0.38 ^c			4.7 0.18 ^a	
15	10.8 1.11	6.8 .005	8.0 .005	57.5 11.2	62.8 0.59	77.8 0.52	5.4 0.07	3.9 0.18	6.9 1.13	5.4 0.14	4.5 0.31	4.8 0.08
		8.5 0.60 ^a			66.0 0.25 ^d			5.4 0.50 ^{ab}			4.8 0.16 ^a	
21	11.0 1.49	6.8 .005	3.2 .005	66.7 4.4	59.8 0.50	45.6 0.48	5.1 0.03	5.9 0.02	7.0 1.18	5.1 0.12	4.8 0.01	5.1 0.03
		7.0 1.07 ^e			57.4 2.97 ^d			6.0 0.43 ^a			5.0 0.06 ^a	
Over All mean	10.5 0.39 ^A	7.1 0.23 ^B	6.1 0.44 ^C	64.0 3.5 ^C	99.9 6.47 ^A	77.3 5.87 ^B	4.2 0.26 ^B	4.6 0.17 ^B	6.2 0.39 ^A	3.8 0.32 ^B	3.7 0.23 ^B	4.9 0.09 ^A
		**			**		**	**		**	**	

Means with different superscript letters vary significantly ($P < 0.05$); small letters are used for comparing days, capital letters are used for comparing doses. (** $P < 0.01$ for comparing main effects) DLC and DHC refer to low and high concentrations of diazinon.

Table VI. Changes in liver body weight ratio (LWBr), microsomal protein and cytochrom P-450 in Baladi rabbits treated with diazinon (Mean \pm SEM).

D A Y S	Liver : Body Weight ratio (%)			Microsomal Protein (μ g protein /g liver)			Cytochrom P-450 (η mole/ mg microsomal protein)		
	Control	DLC	DHC	Control	DLC	DHC	Control	DLC	DHC
0	4.3 \pm 0.08	4.1 \pm 0.04 4.2 \pm 0.05 ^a	4.3 \pm 0.07 **	1.1 \pm 0.05	0.66 \pm 0.04 0.8 \pm 0.06 ^d	0.78 \pm 0.08 **	813 \pm 0.43	70.6 \pm 0.62 71.9 \pm 2.2 ^a	63.7 \pm 0.18 **
1	4.2 \pm 0.07	2.6 \pm 0.07 3.4 \pm 0.02 ^d	3.3 \pm 0.08	1.1 \pm 0.05	1.5 \pm 0.07 1.5 \pm 0.11 ^c	1.9 \pm 0.10	80.4 \pm 0.60	33.3 \pm 0.53 46.2 \pm 7.4 ^b	24.9 \pm 0.25
3	4.3 \pm 0.08	4.0 \pm 0.06 3.9 \pm 0.13 ^b	3.4 \pm 0.11	1.05 \pm 0.05	1.8 \pm 0.06 1.6 \pm 0.13 ^b	2.1 \pm 0.04	80.2 \pm 0.78	17.6 \pm 0.30 40.3 \pm 8.5 ^c	23.2 \pm 0.17
7	4.3 \pm 0.09	4.9 \pm 0.10 3.6 \pm 0.23 ^c	2.5 \pm 0.10	1.07 \pm 0.05	2.0 \pm 0.02 1.8 \pm 0.18 ^a	2.5 \pm 0.06	81.4 \pm 1.14	17.7 \pm 0.87 36.5 \pm 9.6 ^d	10.4 \pm 0.33
15	4.3 \pm 0.08	3.4 \pm 0.06 3.7 \pm 0.14 ^c	3.3 \pm 0.07	1.6 \pm 0.05	1.8 \pm 0.07 1.5 \pm 0.11 ^c	1.7 \pm 0.11	81.0 \pm 0.42	17.4 \pm 0.18 36.2 \pm 9.6 ^d	10.3 \pm 0.25
21	4.2 \pm 0.08	3.4 \pm 0.11 3.6 \pm 0.14 ^c	3.2 \pm 0.07	1.1 \pm 0.05	1.8 \pm 0.06 1.8 \pm 0.19 ^a	2.6 \pm 0.07	80.3 \pm 0.57	12.4 \pm 0.23 32.5 \pm 10.2 ^e	4.8 \pm 0.24
Over All mean	4.3 \pm 0.03 ^A	3.6 \pm 0.11 ^B **	3.3 \pm 0.11 ^C	1.1 \pm 0.02 ^C	1.6 \pm 0.09 ^B **	1.9 \pm 0.13 ^A	80.8 \pm 0.27 ^A	28.2 \pm 4.2 ^B **	22.9 \pm 4.1 ^C

Means with different superscript letters vary significantly (P<0.05); small letters are used for comparing days, capital letters are used for comparing doses. (** P < 0.01 for comparing main effects). DLC and DHC refer to low and high concentrations of diazinon.

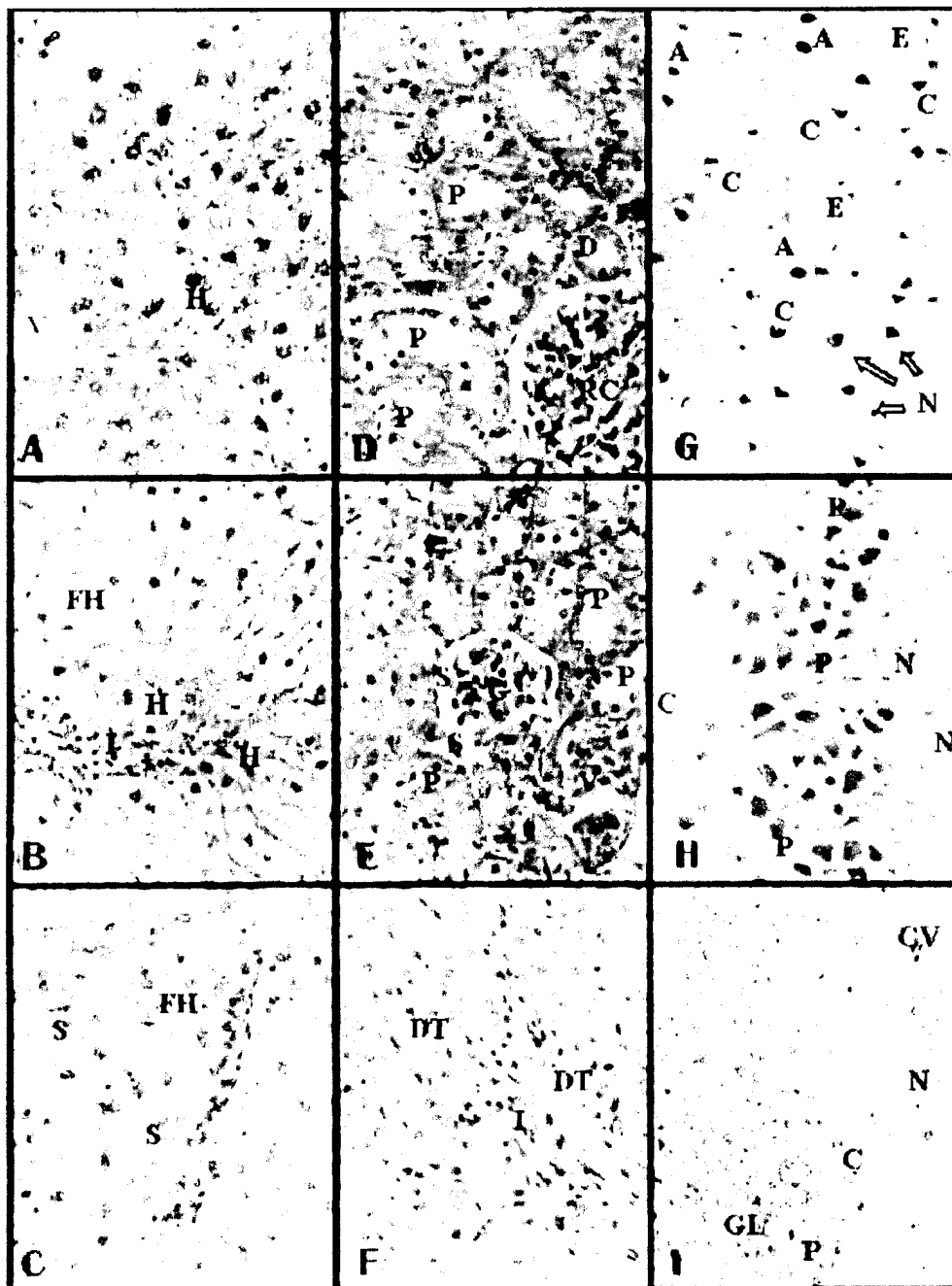


Plate I. paraffin sections stained by heamatoxylin and eosin for histopathological changes. original magnification X400.

Fig. A. Control rabbit liver, showing the hepatocytes (H) form flat, anastomosing plates towards the terminal hepatic vainule (V), they are large polyhedral cells with large rounded nuclei with dispersed chromatin and prominent nucleoli.

Fig. B&C. Rabbit liver post 21 days DHC dipping, showing liver cell with vacuolated and amorphous eosinophilic cytoplasm and small pyknotic nuclei (H). Inflammatory cell infiltrate among the parenchyma hepatic cells (I). Interlobular mononuclear inflammatory cell among fatty hepatic cells (FH) and dilated congestion sinusoid (S) were seen.

Fig. D. Control rabbit kidney cortex showing, rounded structural renal corpuscles (RC), the glomeruli, surrounded by narrow Bowman's space. The cortical tubules consist of proximal convoluted tubules (P) with smaller number of distal convoluted tubules (D).

Fig. E&F. Rabbit kidney cortex post 21 days DHC dipping showing, congestion of glomeruli and peritubular vessels (V), swelling of some convoluted tubules and Bowman's capsule lining with flattened nuclei of squamous cells (S) and enlarged space were noted. Mononuclear infiltrating cells among proliferating convoluted tubules (I) and hyperplasia of distal convoluted tubules (DT) were seen.

Fig. G. Control rabbit cerebral cortex showing, neurons vary in size and shape (N). Astrocytes cell (A) characterized by large polygonal nuclei contain central nucleoli. Oligodendrocytes (E) have rounded nuclei and clear perinuclear halo. Numerous small capillary vessels (C) are present.

Fig. H&I. rabbit cerebral cortex post 21days DHC dipping showing, multiply rows of large nerve cell (purkinje cells (P)) and neuron cells forming large infiltrating, which vary greatly in size and shape (N), have hyperchromatic nuclei. Granular layer (GL) consisting of population of small uniform cell, have moderate amount of eosinophilic cytoplasm and small rounded basophilic nuclei. Also, showing mild degenerative changes of nerve fiber and congestion of blood vessels (CV).




Plate II. paraffin section stained by periodic acid Schiff (PAS) for demonstrating the glycogen content. Original magnification X400.

Fig. A. Control rabbit liver showing, intense PAS positive reaction as red granules arranged in regular line in hepatocytes cytoplasm (H) around negative nuclei.

Fig. B&C. Rabbit liver post 21 days DHC dipping showing, marked decrease of glycogen content in hepatocytes and absent in the fatty cells (FC). In other zone a weak stained were observed in one side of hepatocytes (↑).

Fig. D. control rabbit kidney cortex showing, strong PAS-positive demonstrate the prominent brush border (bb) into the lumen of proximal tubules and its basal lamina, as well as the glomeruli given red reactions in the basal lamina of the capillary loops (C).

Fig. E&F. rabbit kidney cortex post 21 days DHC dipping showing, increased glycogen content in the glomeruli mesengail matrix (m) and thickening of basement membrane (bm).

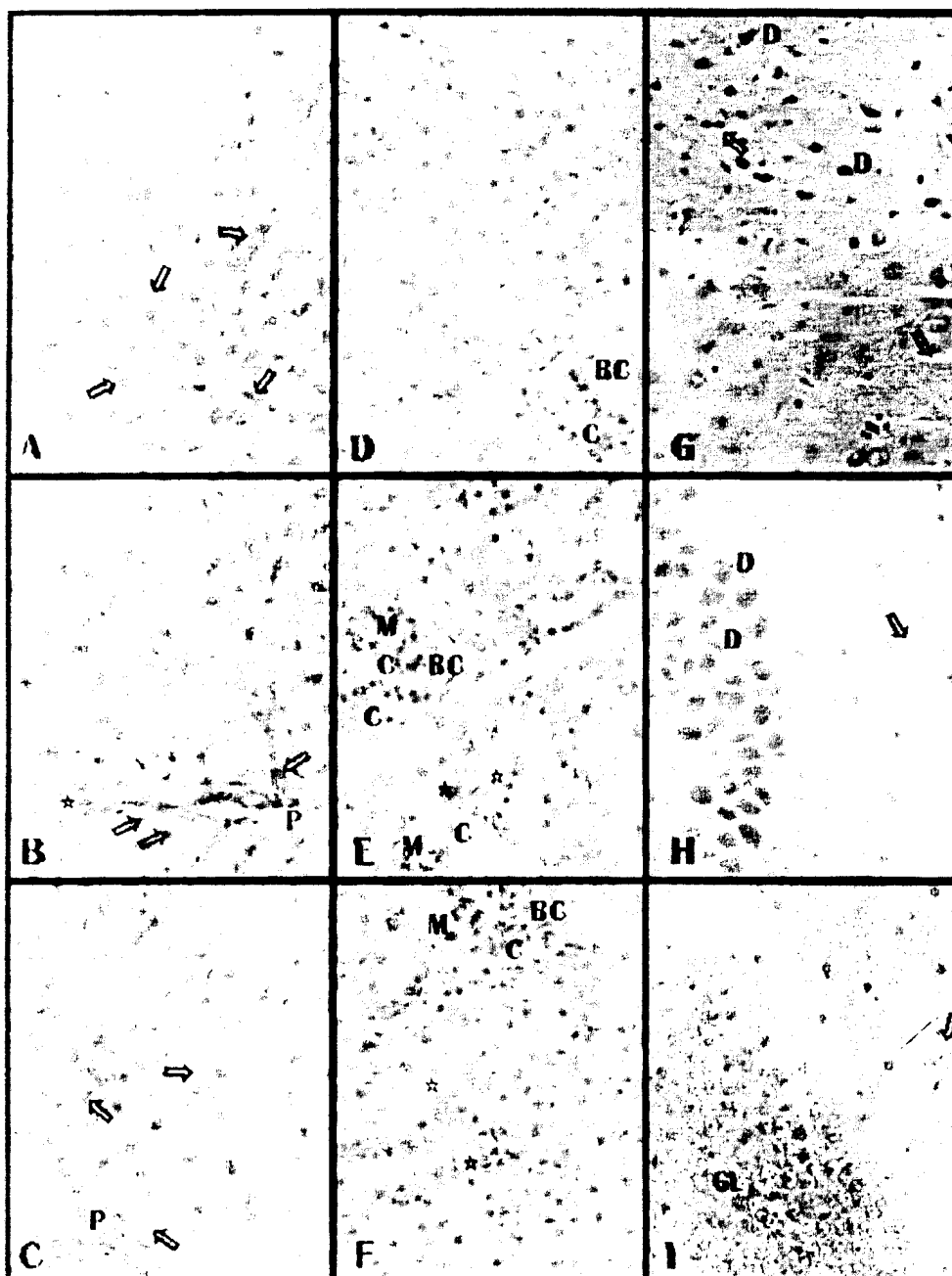


plate III. Paraffin section incubated in acetylthiocholine iodide and stained with yellow ammonium sulfide for demonstrating AChE activity. Original magnification X400.

Fig. A. Control rabbit liver showing, moderate AChE activity in hepatocyte cytoplasm around the hepatic venule as brown fine granules (↑).

Fig. B&C. rabbit liver post 21 days DHC dipping showing reduction of AChE activity despaired at the cell membrane of hepatocyte around the portal tract (P) and bile duct (*).

Fig. D. Control rabbit kidney cortex showing, week AchE activity in renal tubules and moderate activity in the glomeruli basal lamina of capillary loops (C).

Fig. E&F. rabbit kidney cortex post 21 days DHC dipping showing, increased AChE activity in the glomeruli mesangial cell (mc) and basal lamina of Bowman's capsule (Bc). Moderate activity of AChE was observed in basement membrane of most renal tubules (*).

Fig. G. Rabbit cerebral cortex showing, moderate AChE activity in most neurons cell body (N), dendrites process (D) and lined the capillary vessel (↑).

Fig. H&I. Rabbit cerebral cortex post 21 days DHC dipping showing, week activity of AChE in most hyperchromatic neuron and in area of proliferating cells in granular layer (GL).

DISCUSSION

Physiological and Biochemical Parameters:

The present results revealed that diazinon exposure was associated with significant decreases in RBC counts and blood Hb, and significant increases in MCV, MCH and PCV. A similar trend to our finding has been observed in mice treated with Nuvacron and Furadan.⁽¹¹⁾ Shalby (1998).⁽¹²⁾ found that treating rats with chlorpyrifos insecticide reduced Hb and RBC's counts. They explained this reduction in hemoglobin content by the observed reduction in RBC's counts, and that Nuvacron and Furadan might have adversely affected the bone marrow resulting in anemia. The increase in MCV and MCH are known to be a characteristic of an anemic condition.⁽¹³⁾

It has been reported that total plasma protein were decreased in rabbits and rats treated by organophosphorous pesticides.^(14,15) That agrees with our results that diazinon caused a reduction in TP ($P < 0.01$), a possible explanation for these findings is that proteolytic activity was induced due to stress of exposure. Another hypothesis has been advanced to explain the reduction in the protein level. It suggests that physiological compensatory mechanisms are activated to (i) provide intermediates for deriving energy through Krebs's cycle and (ii) to compensate for osmoregulatory problems (arising out of leakage of ions and other essential molecules) by enhancing the free amino acid level in blood.⁽¹⁶⁾

The elevated cholesterol level in the present study due to diazinon dipping is consistent with those of Ashgar et al. (1994)⁽¹⁴⁾ who reported that total cholesterol were elevated in male rabbits treated by methyl parathion. The increase in the level of serum cholesterol may be due to an increased synthesis of cholesterol in the liver.⁽¹⁷⁾

Nitrite represents a potential hazard because of its involvement in the nitrosation reaction with appropriate nitrosatable substrate(s) giving rise to the formation of a potent group of chemical carcinogens, the N-nitroso compounds, most of which have induced tumors in every species of laboratory animals tested and in virtually every tissue.⁽¹⁸⁾ The present results indicated a significant increase of nitrite concentration in the DHC treated rabbits (Table V.). This increase might be ascribed to its conversion into nitrous acid in the acidic pH, which subsequently react with unionized secondary or tertiary amines to form N-nitrose compounds. The present work observed increase in hydroxylamine level in the DHC treated group which can be explained by the fact that hydroxylamine derivatives are formed in the liver and then converted into a glucuronide. The glucuronide conjugate is excreted in urine, where the acidic pH can convert it back to

hydroxylamine, which is rearranged to form nitrenium ion by a loss of water. The electrophilic nitrenium ion can then react with nucleophilic targets in the urinary bladder epithelium.⁽¹⁹⁾ The mammalian cytochrome P-450 dependent mixed-function monooxygenases are responsible for the metabolic biotransformation of numerous exogenous agents e.g. drugs, dyes, pesticides and environmental carcinogens,⁽²⁰⁾ as well as endogenous compounds e.g. steroids, fatty acids and prostaglandins.⁽²¹⁾

It has been postulated that the hepatotoxic effects of some environmental carcinogens may be proportional to the levels of their activating enzymes in the liver.⁽²²⁾ Bio-transformation in the liver is, therefore, a critical factor, not only in drug therapy, but also in defending the body against the toxic effects of a wide variety of environmental chemicals such as insecticides, food additives, etc.. The metabolism of most of these agents involves an oxidation-reduction reaction mediated by the enzyme complex localized in the endoplasmic reticulum of the liver microsomes. This enzyme system metabolizes a wide variety of xenobiotics.⁽²³⁾

The present study is concerned with certain class of these enzymes, the microsomal cytochrome P-450. The present results showed that the hepatic content of cytochrome P-450 was significantly decreased (Table VI.), that were associated with the elevation of total cholesterol which caused disturbance of liver microsomal enzymes.

Histopathological Findings:

The light microscopic pictures of animal organs exposed to different concentration of diazinon are indispensable. The animal showed accumulation of the pesticide in different organs, the order of tendency for accumulation is; the liver, kidney and brain. According to the present work, liver cells lost their radial arrangement as well as cellular infiltration in the central and portal tract (plate I), this feature may be due to the disturbance in liver detoxifying the toxic effect of diazinon. Similar to our results, the liver treated with DDT showed large globules of fat inside the liver cells, indicating fat accumulation compared to control liver where there were tiny minute droplets of fats.⁽²⁴⁾ However, hepatocyte proliferation, vacuolated cytoplasm and focal necrosis preceding hepatomegaly in rat received DDT is related to a regenerative liver response to pesticides.⁽²⁵⁾

The kidney is the main site of uptake and degradation of circulating small molecular weight proteins and peptides. After crossing the glomerular filtration barrier, these constituents are usually taken up by the proximal tubular cell.⁽²⁶⁾ The tissue distribution of diazinon were investigated in male rats which received a single intraperitoneal dose of diazinon (100 mg/kg body wt) in olive oil, and showed that the diazinon residue was much greater

in the kidney than in other organs.^(27,28) In the present work, the pathological changes observed in the kidney after DHC exposure included swelling of proximal convoluted tubules and congestion of both intraglomerular capillaries and peritubular vessels. Infiltrating cells among proliferating tubules and hyperplasia of distal tubules were observed (plate I), demonstrating that the diazinon residues level are higher in the kidney tissue when compared with the liver. In agreement with this study, the presence of a renal tubular lesion caused by mercuric chloride enhanced the toxicity of diazinon which was orally administrated.⁽²⁹⁾

The present results revealed brain lesion consisting of neuron cells forming large infiltration, which vary greatly in size and shape, have hyperchromatic and polymorphic nuclei with large clear perinuclear cytoplasmic vacuole. Other area consisting of population of small uniform cell, have moderate amount of eosinophilic cytoplasm and small rounded basophilic nuclei. Mild degenerative changes of nerve fiber and congestion of blood vessels were observed. Similarly, the histological examination of *Orizias latipes* embryo exposed to diazinon reverted small foci of necrotic cells which become apparent within the inner nuclear layer and isolated individual pyknotic cells in the ganglion layer.⁽³⁰⁾ Also, histopathologic changes in the brain of Rhesus macaques (*Macaca mulatta*) treated with organophosphorus consisted of neuron necrosis, spongiosis, gliosis, astrocytosis and vascularization.⁽³¹⁾ The brain lesion is a feature of the neuropathies, toxic states in which the primary injuries are found in neuronal cell bodies.⁽³²⁾

Histochemical Findings:

Glycogen is the major storage form of carbohydrates in the animal liver.⁽³³⁾ Normally the glycogen is intense in the hepatocyte and this was evident by marked positive PAS reaction. A marked decrease of hepatocyte glycogen was noticed after DHC exposure, focally to the central vein region indicating the increase of fatty cells and may denote to affection of hepatocyte function induced by diazinon. However marked increases in glycogen deposits in one side of some hepatocytes may be due to the detoxifying feature of hepatocytes. These findings are in good agreement with the results of some previous studies.⁽³⁴⁾ The elevation of glycogen levels may reflect a disruption in enzyme pathways of glycolysis.⁽³⁵⁾ Histochemical studies in the kidney cortex revealed strong PAS-positive in the basement membrane and on the brush border of the proximal convoluted tubules.⁽³⁶⁾ In the current study, glycogen content of renal tubules and glomeruli mesangial cells was increased. This increase may be due to the condensed ground substance and a reduction in the basement membrane permeability, owing to the toxic effect of organophosphorus. The lack of glycogen in the brush border of proximal convoluted tubules observed in this study may be related to the

diazinon treatment, induced destruction in the tubules border, thus, the tubules lost their physical and chemical protection.^(37,38)

Acetylcholinesterase identified Cholinergic fibers by the neurohistochemistry method in rat and hamster livers demonstrated that the hepatic functions may be regulated by both sympathetic and parasympathetic nerves in the portal region.⁽³⁹⁾ The present histochemical AChE staining to visualized nerve fiber was seen in liver interlobular region, decreased gradually in degenerative hepatocytes at the cell membrane of hepatocytes around the portal tract and bile duct. These findings are in accordance with those of other workers.^(28,40,41)

The increase in enzymatic activity in portal region and sinusoid provides a detoxification mechanism from high diazinon exposure. A strong AChE enzyme activity was also detected within the interlobular arteries and the cells of Bowman's capsule.⁽⁴²⁾ The present work revealed an increased of AChE in kidney glomeruli and tubules compared to the control group, due to the diazinon toxicokinetic associated with tissue distribution and anticholinesterase activity, that the diazinon residue was much greater in kidney than in other organs.⁽²⁸⁾ After DHC exposure, an inhibition of AChE was observed in the brain tissues in most hyperchromatic neuron and in area of proliferating granular layer. Inactivation of AChE in nervous tissue results in accumulation of acetylcholine in nicotinic cholinergic synapses, causing over stimulation and subsequent disruption of transmission in both the central and peripheral nervous system.⁽⁴³⁾ There was relation to function of the cholinergic system and distribution of AChE in brain which may be associated with memory loss and cognitive dysfunction. The loss of cholinergic input was accompanied by a persistent decrease in choline acetyltransferase and acetylcholine esterase activities in the cortical target areas similar to the cholinergic malfunction seen in Alzheimer's dementia.⁽⁴⁴⁾

In conclusion diazinon caused anemic condition to the animals exposed to it. In addition, it caused decrease in plasma total protein leading to decreases in the animal production. Also cholesterol increased in plasma causing negative effects on the animal health. The decrease of cytochrom P-450 was reflected on the absence of glycogen deposit making the pure fatty hepatic cells appear in histopathology and proliferation of microsomal enzyme associated with glycolysis. Decreased histochemical AChE was related to the function of the cholinergic system and distribution of AChE in brain was associated with memory loss and cognitive dysfunction. Our results suggest that dipping of animal in diazinon for protection from scab mite *Psoroptes ovis* may cause impairment of the physiological and histopathological parameters in red Baladi rabbits and other farm animals.

Acknowledgements:

The authors are grateful to Professor M. H. Salem and Professor F. D. El-Nouty for critical reviewing of the manuscript.

REFERENCES

1. Reece RL and Handson P. Observation on the accidental poisoning of birds by organophosphate insecticides and other toxic substances. *Vet Rec* 1982; 111: 453-455.
2. Hill DL, Hall CI, Sander JE, Fletcher OJ, Page RK and Davis SW. Diazinon toxicity in Broilers. *Avian Diseases* 1994; 38: 393-396.
3. Mayer DF, Lurden CA and Williams RE. Tralomethrin insecticide and domestic pollinator. *Am Bee J* 1991; 132: 461.
4. Sultatos LG. Mammalian toxicology of organophosphorus Pesticides. *J. Toxicol. Environ Health* 1994; 43: 271-289.
5. Feigl F and Anger V. *Spot Test in organic analysis*. 7th ed., Elsevier Pub. New York. 1966; ed. Oesper R.
6. Omura T and Sato R. The carbon monoxide binding pigment Of liver microsomes. 1- Evidence for its hemoprotein nature. *J. Biol Chem* 1964; 239: 2370-2378.
7. Lowery OH, Rosebrough, NJ, Faw, AL, and Randall, RJ. Protein measurement with the folin-phenol reagent. *J Biol Chem* 1951; 193: 265-275.
8. Pears AVE. *Histochemistry theoretical and applied* 4th ed. Little Brown and Company Poston 1985; 165-195.
9. Tewari TP, Schgal SS and Malhotra SK. Microanalysis of the reaction product in Kranvsky and Roots histochemical localization of acetylcholinesterase. *J. Histochem. Cytochem.* 1982; 29: 1021-1028.
10. SAS user guide: *Statistics Version 5th ed.* SAS institute Inc., Cary, NC. 1995.
11. Gupta M, Bagchi G, Bandyopadhyay S, Sasmal D, Chatterjee T and Dey SN. Hematological changes produced in mice by Nuvacron or Furadan. *Toxicology* 1982; 25: 255-260.
12. Shalby Sh AA. *Toxicological studies on experimental rats*. M Sc Thesis, Fac Agric Mansoura Univ 1998.
13. Seiverd CE. *Hematology for technologists*, 4th ed. Lea and Febiger Philadelphia, 1972; pp. 300-360.
14. Ashgar M, Sheikh MA, Hashmi A. Effects of orally fed methyl parathion on some hematochemical parameters of rabbits. *Pakistan Vet J* 1994; 14: 34-36.
15. Eissa FII. *Studies on the determination of some pesticides residues and their toxic effect against some pests*. M Sc Thesis, Fac Agric Kafer El-Sheikh Tanta Univ 1999.
16. Bhavan PS and Geraldine P. Alterations in concentrations of protein, carbohydrate, glycogen, free sugar and lipid in the prawn *macrobrachium malcolmsonii* on exposure to sublethal concentrations of Endosulfan. *Pestic Biochem Physiol* 1997; 58: 89-101.
17. Enan E, Berberian IG, El-fiki S, El-Masry M and Enan OH. Effects of two organophosphorous insecticides on some biochemical constituent in the nervous system and liver of rabbits. *J Environ Sci Helth* 1987; B22: 149-170.
18. Schlag P, Bockler R and Peyer, M. Nitrite and nitrosamines In gastric-juice: Risk factors for gastric cancer. *Scand J Gastroenterol* 1982; 17: 145-150.
19. Kadlubar FF, Miller, JA and Miller EC. Hepatic microsomal N-glucuronidation and nucleic acid binding of N-hydroxy arylamines in relation to urinary bladder carcinogenesis. *Cancer Res* 1977; 37: 805-814.
20. Guengerich F. Roles of cytochrome P-450 enzymes in chemical Carcenogenesis and cancer chemotherapy. *Cancer Res* 1988; 48: 2946-2954.
21. Kupfer D. Endogenous substrates of monooxygenases: Fatty acids and prostaglandins. In: *Hepatic cytochrome P-450 monooxygenase system*. ed Schenkman, J B 1982; pp. 157-187, Pergamen Press, Oxford.
22. Badawi AF and Mostafa MH. The possible mechanisms and the etiological relevance of aberration in carcinogen metabolizing enzymes during schistosomiasis. *Int J Med Res* 1993; 21: 281-305.
23. Young-nam C and Robert E. Effect of Schistosoma infection on the hepatic drug metabolizing capacity of mice. *J Pharmacol Exp Therap* 1976; 199:432-445.
24. Mikhail TH, Aggour N, Awadallah R, Boulos MN, El-Dessoukey EA and Karima AI. Acute toxicity of organophosphorus and organochlorine insecticides in laboratory animals. *Zernahrungs wiss*, 1979; 18: 258-268.
25. Kastka G, Kopec-Szlezak J and Palut D. Early hepatic changes induced in rats by two hepatocarcinogenic organohalogen pesticides: bromopropylate and DDT. *Carcinogenesis*, 1996; 17: 407-412.
26. Gibson IW and More IA. Glomerular pathology: recent advances. *J Pathol* 1998; 184: 123-129.
27. Tomokuni K and Hasegawa T. Diazinon concentrations and blood cholinesterase activities in rats exposed to diazinon *Toxicol Lett* 1985; 25: 7-10.
28. Wu HX, Evreux-Gros C and Descotes J. Diazinon toxicokinetics, tissue distribution and anticholinesterase activity in the rat. *Biomed Environ Sci* 1996; 9: 359-369.
29. Abdelsalam EB and Ford EJ. The effect of induced liver, kidney and lung lesions on the toxicity of levamisole and diazinon in calves. *J Comp Pathol* 1987; 97: 619-627.
30. Hamm JT, Wilson BW and Hinton DE. Organophosphate-induced acetylcholinesterase

- inhibition and embryonic retinal cell necrosis in vivo in the teleost (*Oryzias latipes*). *Neurotoxicology* 1998; 19: 853-869.
31. Britt JO Jr, Martin JL, Okerberg CV and Dick EJ Jr. Histopathologic changes in the brain, heart, and skeletal muscle of rhesus macaques, ten days after exposure to soman (an organophosphorus nerve agent). *Comp Med* 2000; 50:133-139.
32. Jortner BS. Mechanisms of toxic injury in the peripheral nervous system: neuropathologic considerations. *Toxicol Pathol* 2000; 28:54-69.
33. Murray R, Granner D, Maysr P and Rodwell VW. *Biochemistry Harper's 32nd ed.* Icton and Long. 2000.
34. Shaheen AA, Ebeid FA and Fahim AT. Effect of praziquantel on some aspects of carbohydrate metabolism in mice infected with *Schistosoma mansoni*. *Pharmacol Res* 1989; 21: 263-270.
35. Mchugh LJ, Lopez L and De Angelo AB. Hepatotoxicity of drinking water disinfection by-product, dichloroacetic acid, in the medaka small fish model. *Toxicol lett* 1998; 94: 19-27.
36. Burkitt HG, Young B and Heath TW. *Wheater's functional histology a text and colour atlas, 3rd ed.*, Churchill Livingstone Harcourt Brace and Company limited, 1999; pp294.
37. Ogura T, Takaoka M, Yanouchi T, Oishi T, Mimra Y, Hashimoto M and Yamamura M. Changes in urinary enzyme activity and histochemical findings in experimental tubular injury induced by gold sodium thionate. *Toxicol Med* 1996; 27: 41-55.
38. Salem MA, El-Aggan HA and Afify MT. Fibrillary-Immunotactoid Glomerulopathy. *Bull Alex Fac Med* 1999; 35: 559-565.
39. Akiyoshi H, Gonda T and Terada T. A comparative histochemical and immunohistochemical study of aminergic, cholinergic and peptidergic innervation in rat, hamster, guinea pig, dog and human livers. *Liver* 1998; 18: 352-359.
40. Watson AM and Chambers JE, The effect of high and low dosages of paraoxon in beta-naphthoflavone-treated rats. *J Biochem Toxicol* 1996; 11: 263-268.
41. Salazar De La Vega MY, Tabche LM and Garcia CM. Bioaccumulation of methyl parathion and its toxicology in several species of the freshwater community in Ignacio Ramirez dam in Mexico. *Ecotoxicol Environ Saf* 1997; 38: 53-62.
42. Luppá H, Alabdalla M, Andra J, and Weiss J. Histochemical investigations on the localization of acetylcholinesterase in the kidney of selected vertebrates. *Acta Histochem* 1992; 92: 147-159.
43. Cavaliere MJ, Puga FR, Calore EE, Calore NMP, Da Rosa AR, and Weg R. Protective effect of pralidoxime on muscle fiber necrosis induced by organophosphate compounds. *J Toxicology* 1998; 36: 295-306.
44. Zeitschel U, Schliebs R, Rossner S, Bigl V, Eschrich K and Bigl M. Changes in activity and expression of phosphofructokinase in different rat brain regions after basal forebrain cholinergic lesion. *J Neurochem* 2001; 83: 371-380.

سید محمد علی